



PATIENT

Arlo Shiner

SPECIES

Canine

BREED

Boxer

SEX

Male

AGE

5 years

WEIGHT

70 lbs

INTERPRETED BY

Remo Lobetti, BVSc,
MMedVet (Med),
PhD, Dipl. ECVIM

IMAGING PERFORMED BY

Jocelyn Smith, CVT

HOSPITAL NAME

Annville-Cleona
Veterinary Associates

REFERRING VET

Dr. Keck

INVOICE

69537

DATE

12/11/25

PRESENTING CLINICAL SIGNS

History: On and off diarrhea for 2 & 1/2 years. Treated with fiber and Baytril for Boxer colitis with a moderate response. Negative fecals. Suspect ulcerative colitis but owner wants to rule out GI lymphoma and IBD. Owner declined endoscopy or exploratory surgery for GI biopsies. Owner tried dietary management with HILLS I/D DIET and Hydrolyzed diets and high fiber/Hills GI Biome which helps. Probiotics are being used by owner.

ULTRASONOGRAPHIC EXAMINATION OF THE ABDOMEN

Urinary System

The urinary bladder is small with a normal thickness and smooth appearance of the wall. Normal anechoic urine with no sediment or uroliths evident.

Normal appearance of the trigone area, proximal urethra, and iliac blood vessels.

Normal appearance and size of the iliac lymph nodes. Ureters not visualized, which can be considered a normal finding.

Normal renal size (left measured 7.6 cm, right measured 7.4 cm), architecture, echogenic appearance, cortico-medullary differentiation, which maintains a 1:3 cortex to medulla ratio, pelvis, and capsule. No infarcts, mineralization or renoliths evident. Normal color flow pattern is evident in both kidneys.

The prostate is small and hypoechogenic.

Adrenal Glands

Normal shape, echogenic appearance, size, position, and appearance of the visible peri-adrenal vasculature. Left adrenal gland measured 0.42 cm in width. The right adrenal gland measured 0.5 cm in width.

Spleen

Normal size and echogenic appearance. Smooth homogenous parenchyma and regular curvilinear capsule. Normal volume of the splenic vasculature without any overt congestion or thrombosis evident. No inflammatory, neoplastic, infarction, or infiltrative changes evident. The spleen measured 2.1 cm in width.

Liver

Normal size, echogenic appearance, portal markings, and regular curvilinear capsule. No nodules or masses evident. Normal appearance of the hepatic and portal vasculature.



PATIENT

Arlo Shiner

SPECIES

Canine

BREED

Boxer

SEX

Male

AGE

5 years

WEIGHT

70 lbs

INTERPRETED BY

Remo Lobetti, BVSc,
MMedVet (Med),
PhD, Dipl. ECVIM

IMAGING PERFORMED BY

Jocelyn Smith, CVT

HOSPITAL NAME

Annville-Cleona
Veterinary Associates

REFERRING VET

Dr. Keck

INVOICE

69537

DATE

12/11/25

Gallbladder

The gallbladder is full containing normal anechoic bile. Normal thickness and echogenic appearance of the wall. Normal size and appearance of the cystic and common bile duct.

Gastrointestinal

Normal appearance of the stomach, duodenum, small intestine, ileo-cecal junction, and colon with no loss of layering, 1:3 muscularis to mucosa ratio, normal wall thickness and peristaltic activity, and no distension of the lumen.

Pancreas

The visible sections of the pancreas are of normal size and echogenic appearance with a regular capsule. Normal echogenic appearance of the mesentery and fat surrounding the pancreas.

Free Abdomen

Normal mesenteric lymph nodes.

No ascites evident.

ULTRASONOGRAPHIC FINDINGS

- Normal ultrasound examination of the abdomen.

INTERPRETATION OF THE FINDINGS & FURTHER RECOMMENDATIONS

On this ultrasound there is no obvious etiology for the intermittent chronic diarrhea. With the patient's history the most likely diagnosis would be ulcerative colitis.

Ideal further assessment would be endoscopy of the upper and lower urinary tract with biopsies.

Management would be to continue with the current therapy.



PATIENT

Arlo Shiner

SPECIES

Canine

BREED

Boxer

SEX

Male

AGE

5 years

WEIGHT

70 lbs

INTERPRETED BY

Remo Lobetti, BVSc,
MMedVet (Med),
PhD, Dipl. ECVIM

IMAGING PERFORMED BY

Jocelyn Smith, CVT

HOSPITAL NAME

Annville-Cleona
Veterinary Associates

REFERRING VET

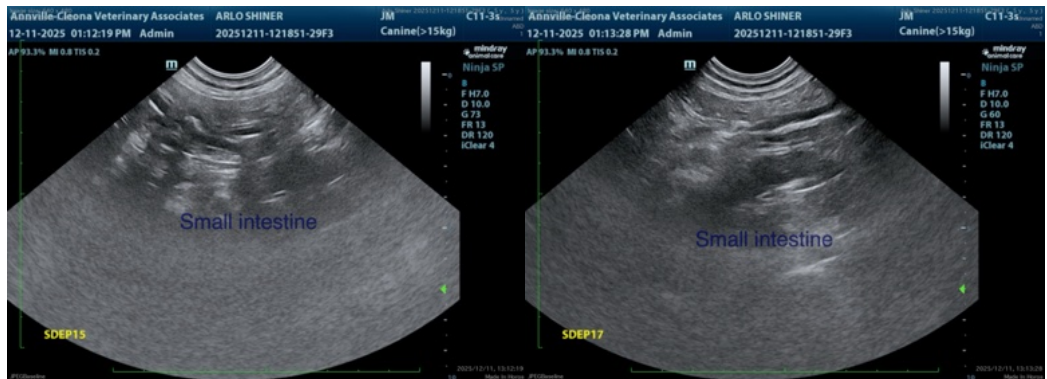
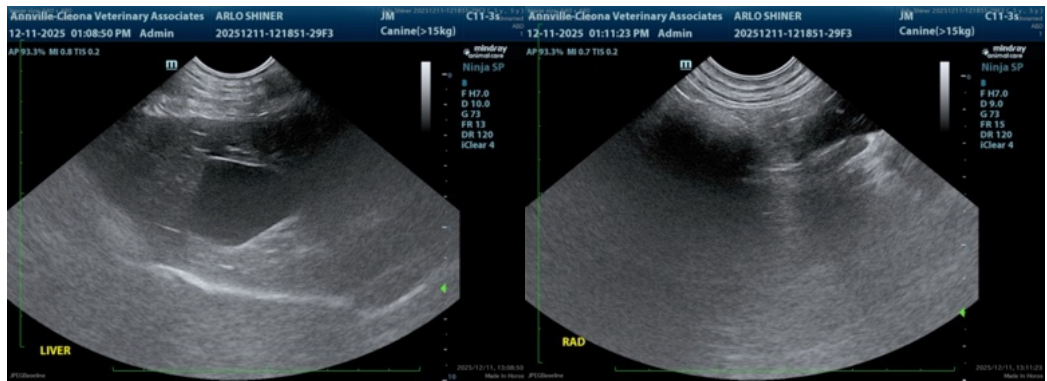
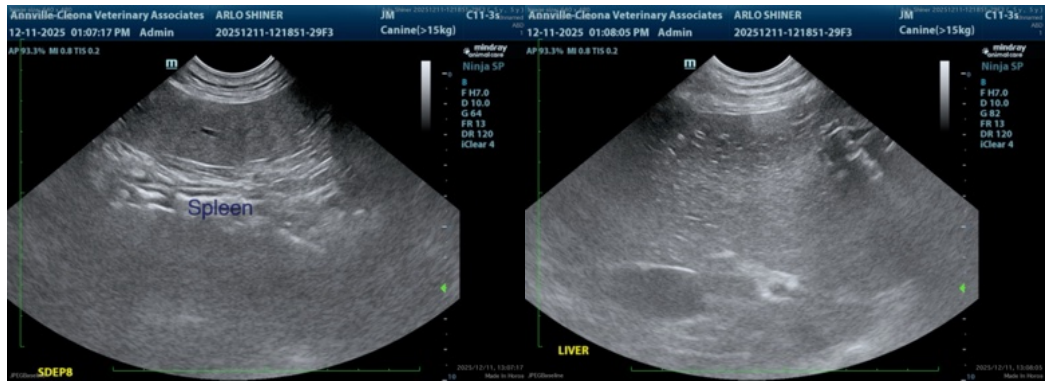
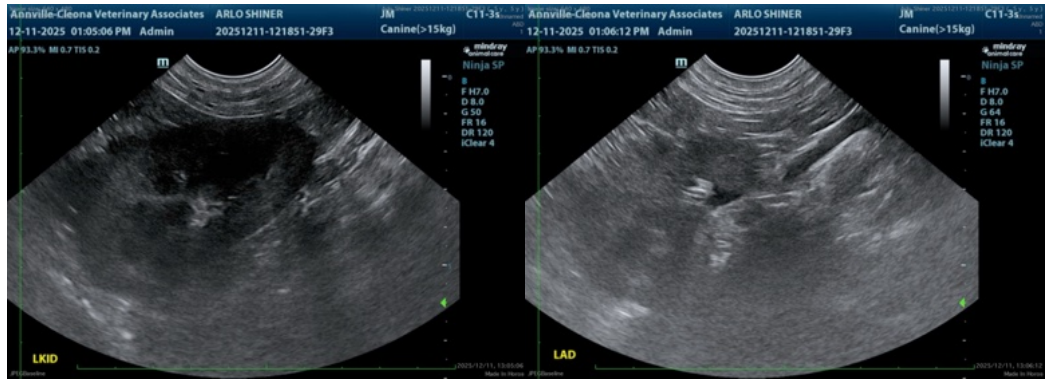
Dr. Keck

INVOICE

69537

DATE

12/11/25





PATIENT

Arlo Shiner

SPECIES

Canine

BREED

Boxer

SEX

Male

AGE

5 years

WEIGHT

70 lbs

INTERPRETED BY

Remo Lobetti, BVSc,
MMedVet (Med),
PhD, Dipl. ECVIM

IMAGING PERFORMED BY

Jocelyn Smith, CVT

HOSPITAL NAME

Annvile-Cleona
Veterinary Associates

REFERRING VET

Dr. Keck

INVOICE

69537

DATE

12/11/25

The information and recommendations provided are based on the images presented by the referring veterinarian/sonographer. No evaluation can be communicated regarding pathology that was not visible in the image/video clips provided.

Thank you for this referral. If the clinical or image interpretation does not parallel your findings or if I can be of any further assistance please contact me.

Remo Lobetti, BVSc, MMedVet (Med), PhD, Dipl. ECVIM (Internal Medicine)

info@sonopath.com