



PATIENT

Emma Madhusudhan

SPECIES

Canine

BREED

German Shepherd

SEX

Spayed female

AGE

13 years

WEIGHT

73 lbs

INTERPRETED BY

Remo Lobetti, BVSc,
MMedVet (Med),
PhD, Dipl. ECVIM

IMAGING PERFORMED BY

Dr. Gail Schmieder

HOSPITAL NAME

Slade VH

REFERRING VET

Dr. Schmieder

INVOICE

69509

DATE

12/10/25

PRESENTING CLINICAL SIGNS

History: Increased appetite and water intake. Normal bloods. Spot blood glucose=210. Sending out Fructosamine 12/10/2025. Schedule LDD in future

ULTRASONOGRAPHIC EXAMINATION OF THE ABDOMEN

Urinary System

The urinary bladder is small with a normal thickness and smooth appearance of the wall. Normal anechoic urine with no sediment or uroliths evident.

Normal appearance of the trigone area, proximal urethra, and iliac blood vessels.

Normal appearance and size of the iliac lymph nodes. Ureters not visualized, which can be considered a normal finding.

Normal renal size (left measured 5.8 cm, right measured 6.1 cm), architecture, echogenic appearance, cortico-medullary differentiation, which maintains a 1:3 cortex to medulla ratio, pelvis, and capsule. No infarcts, mineralization or renoliths evident. Normal color flow pattern is evident in both kidneys.

Adrenal Glands

The left adrenal gland is normal in shape, echogenic appearance, size, position, and appearance of the visible peri-adrenal vasculature. Left adrenal gland measured 0.54 cm in width. The right adrenal gland was poorly visualized, but appears to be of normal shape, echogenic appearance and size.

Spleen

Normal size and echogenic appearance. Smooth homogenous parenchyma and regular curvilinear capsule. Normal volume of the splenic vasculature without any overt congestion or thrombosis evident. No inflammatory, neoplastic, infarction, or infiltrative changes evident. The spleen measures 2.7 cm in width.

Liver

Normal size, echogenic appearance, portal markings, and regular curvilinear capsule. No nodules or masses evident. Normal appearance of the hepatic and portal vasculature.

Gallbladder

The gallbladder is full containing normal anechoic bile. Normal thickness and echogenic appearance of the wall. Normal size and appearance of the cystic and common bile duct.



PATIENT

Emma Madhusudhan

SPECIES

Canine

BREED

German Shepherd

SEX

Spayed female

AGE

13 years

WEIGHT

73 lbs

INTERPRETED BY

Remo Lobetti, BVSc,
MMedVet (Med),
PhD, Dipl. ECVIM

IMAGING PERFORMED BY

Dr. Gail Schmieder

HOSPITAL NAME

Slade VH

REFERRING VET

Dr. Schmieder

INVOICE

69509

DATE

12/10/25

Gastrointestinal

Normal appearance of the stomach, duodenum, small intestine, ileo-cecal junction, and colon with no loss of layering, 1:3 muscularis to mucosa ratio, normal wall thickness and peristaltic activity, and no distension of the lumen.

Pancreas

The visible sections of the pancreas are of normal size and echogenic appearance with a regular capsule. Normal echogenic appearance of the mesentery and fat surrounding the pancreas.

Free Abdomen

Normal mesenteric lymph nodes.

No ascites evident.

ULTRASONOGRAPHIC FINDINGS

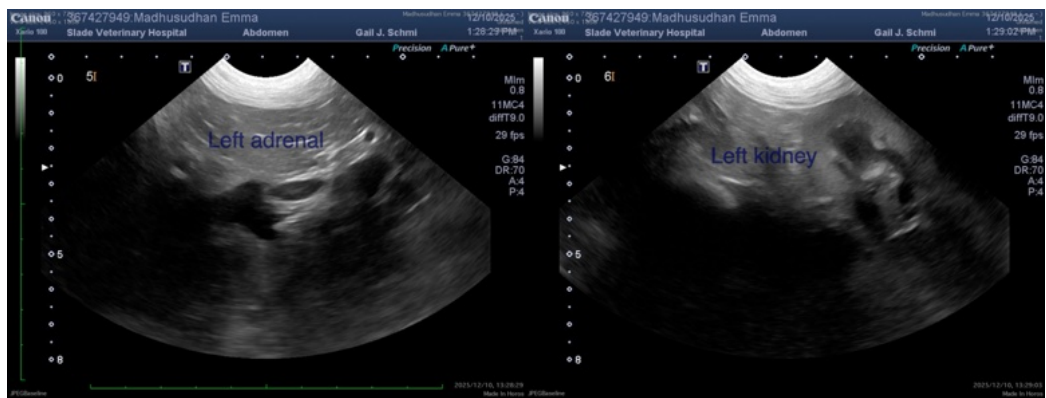
- Normal ultrasound examination of the abdomen.

INTERPRETATION OF THE FINDINGS & FURTHER RECOMMENDATIONS

On this ultrasound there is no obvious etiology for the PU/PD.

Further assessment would be urinalysis.

Specific therapy would be dependent on an etiological diagnosis.





PATIENT

Emma Madhusudhan

SPECIES

Canine

BREED

German Shepherd

SEX

Spayed female

AGE

13 years

WEIGHT

73 lbs

INTERPRETED BY

Remo Lobetti, BVSc,
MMedVet (Med),
PhD, Dipl. ECVIM

IMAGING PERFORMED BY

Dr. Gail Schmieder

HOSPITAL NAME

Slade VH

REFERRING VET

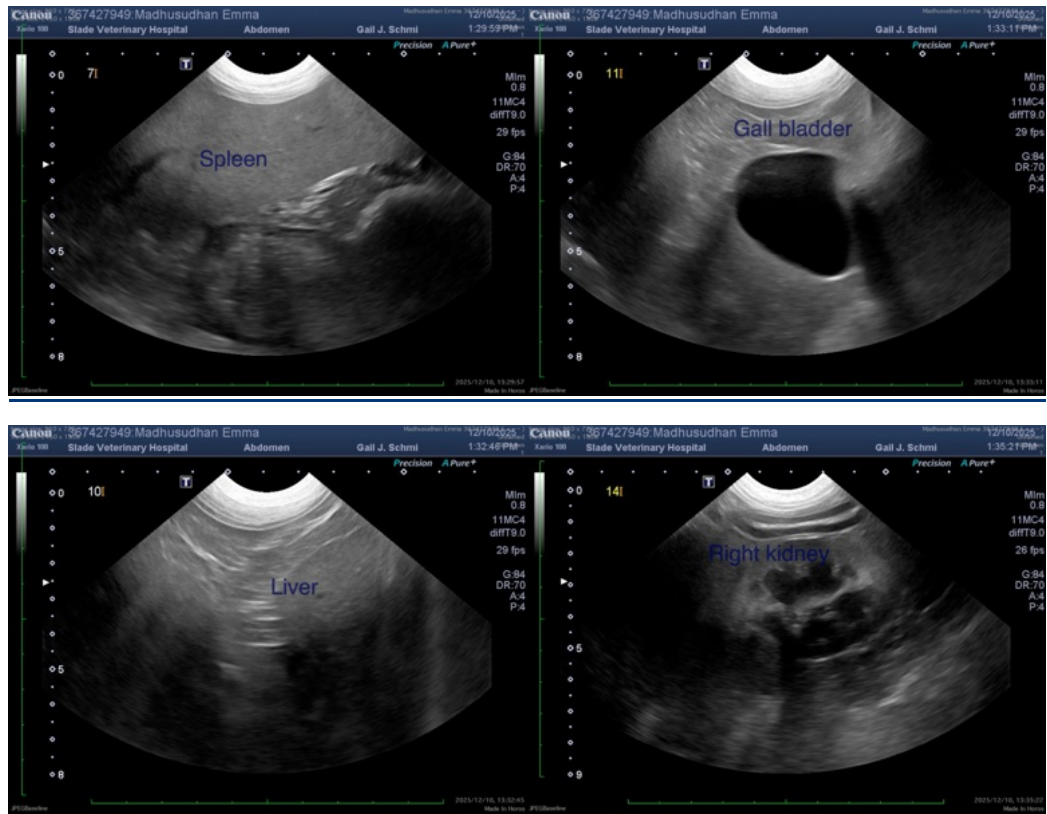
Dr. Schmieder

INVOICE

69509

DATE

12/10/25



The information and recommendations provided are based on the images presented by the referring veterinarian/sonographer. No evaluation can be communicated regarding pathology that was not visible in the image/video clips provided.

Thank you for this referral. If the clinical or image interpretation does not parallel your findings or if I can be of any further assistance please contact me.

Remo Lobetti, BVSc, MMedVet (Med), PhD, Dipl. ECVIM (Internal Medicine)

info@sonopath.com