



PATIENT

Franklin Nitzl

SPECIES

Canine

BREED

Mix

SEX

Neutered male

AGE

14 years

WEIGHT

17 lbs

INTERPRETED BY

Remo Lobetti, BVSc,
MMedVet (Med),
PhD, Dipl. ECVIM

IMAGING PERFORMED BY

Dr. Pascucci

HOSPITAL NAME

American AH

REFERRING VET

Dr. Pascucci

INVOICE

68351

DATE

11/5/25

PRESENTING CLINICAL SIGNS

History: Urinating blood yesterday Being treated for suspect UTI (amoxi) Elevated liver enzymes Being treated for congestive heart failure Has firm moveable mass on neck near thyroid
Neu 15.3k, Mono 1.8k, BUN 32, Glob 4.7, ALT 229, ALP 1415, GGT 51, Chol 328

ULTRASONOGRAPHIC EXAMINATION OF THE ABDOMEN

Urinary System

The urinary bladder is full with a normal thickness and smooth appearance of the wall. Normal anechoic urine with no sediment or uroliths evident.

Normal appearance of the trigone area, proximal urethra, and iliac blood vessels.

Normal appearance and size of the iliac lymph nodes. Ureters not visualized, which can be considered a normal finding.

Normal renal size (left measured 4.9 cm, right measured 4.8 cm), architecture, echogenic appearance, cortico-medullary differentiation, which maintains a 1:3 cortex to medulla ratio, pelvis, and capsule. No infarcts, mineralization or renoliths evident. Normal color flow pattern is evident in both kidneys.

The prostate is small and hypoechogenic measuring 0.7 cm in width.

Adrenal Glands

Normal shape, echogenic appearance, size, position, and appearance of the visible peri-adrenal vasculature. Left adrenal gland measured 0.44 cm and 0.48 cm in width. The right adrenal gland measured 0.52 cm in width.

Spleen

Normal size and echogenic appearance. Smooth homogenous parenchyma and regular curvilinear capsule. Normal volume of the splenic vasculature without any overt congestion or thrombosis evident. No inflammatory, neoplastic, infarction, or infiltrative changes evident. The spleen measured 1.1 cm in width.

Liver

The liver is enlarged with rounded edges, with a diffuse, mottled echogenic, coarse and nodular appearance, decreased portal markings, and regular curvilinear capsule. Nodules are few, parenchymal, hyperechogenic and measure up to 1.4 x 2.1 cm in size. No masses are evident. Normal appearance of the hepatic and portal vasculature.



PATIENT

Franklin Nitzl

SPECIES

Canine

BREED

Mix

SEX

Neutered male

AGE

14 years

WEIGHT

17 lbs

INTERPRETED BY

Remo Lobetti, BVSc,
MMedVet (Med),
PhD, Dipl. ECVIM

IMAGING PERFORMED BY

Dr. Pascucci

HOSPITAL NAME

American AH

REFERRING VET

Dr. Pascucci

INVOICE

68351

DATE

11/5/25

Gallbladder

The gallbladder is full containing normal anechoic bile. Normal thickness and echogenic appearance of the wall. Normal size and appearance of the cystic and common bile duct.

Gastrointestinal

Normal appearance of the stomach, duodenum, small intestine, ileo-cecal junction, and colon with no loss of layering, 1:3 muscularis to mucosa ratio, normal wall thickness and peristaltic activity, and no distension of the lumen. Fecal material is present within the colon.

Pancreas

The visible sections of the pancreas are of normal size and echogenic appearance with a regular capsule. Normal echogenic appearance of the mesentery and fat surrounding the pancreas.

Free Abdomen

Normal mesenteric lymph nodes.

No ascites evident.

ULTRASONOGRAPHIC FINDINGS

- Nodular hepatopathy.

INTERPRETATION OF THE FINDINGS & FURTHER RECOMMENDATIONS

The most likely etiology for the nodular hepatopathy would be nodular hyperplasia with chronic hepatitis, granulomatous disease and infiltrative neoplasia a less likely differential diagnosis.

Further assessment would be FNA cytology of the liver. However, a tru cut or wedge biopsy may be required for a final etiological diagnosis.

Specific therapy would be dependent on an etiological diagnosis. Symptomatic management that could be considered would be the use of Ursodiol with regular monitoring of liver enzyme activity.



PATIENT

Franklin Nitzl

SPECIES

Canine

BREED

Mix

SEX

Neutered male

AGE

14 years

WEIGHT

17 lbs

INTERPRETED BY

Remo Lobetti, BVSc,
MMedVet (Med),
PhD, Dipl. ECVIM

IMAGING PERFORMED BY

Dr. Pascucci

HOSPITAL NAME

American AH

REFERRING VET

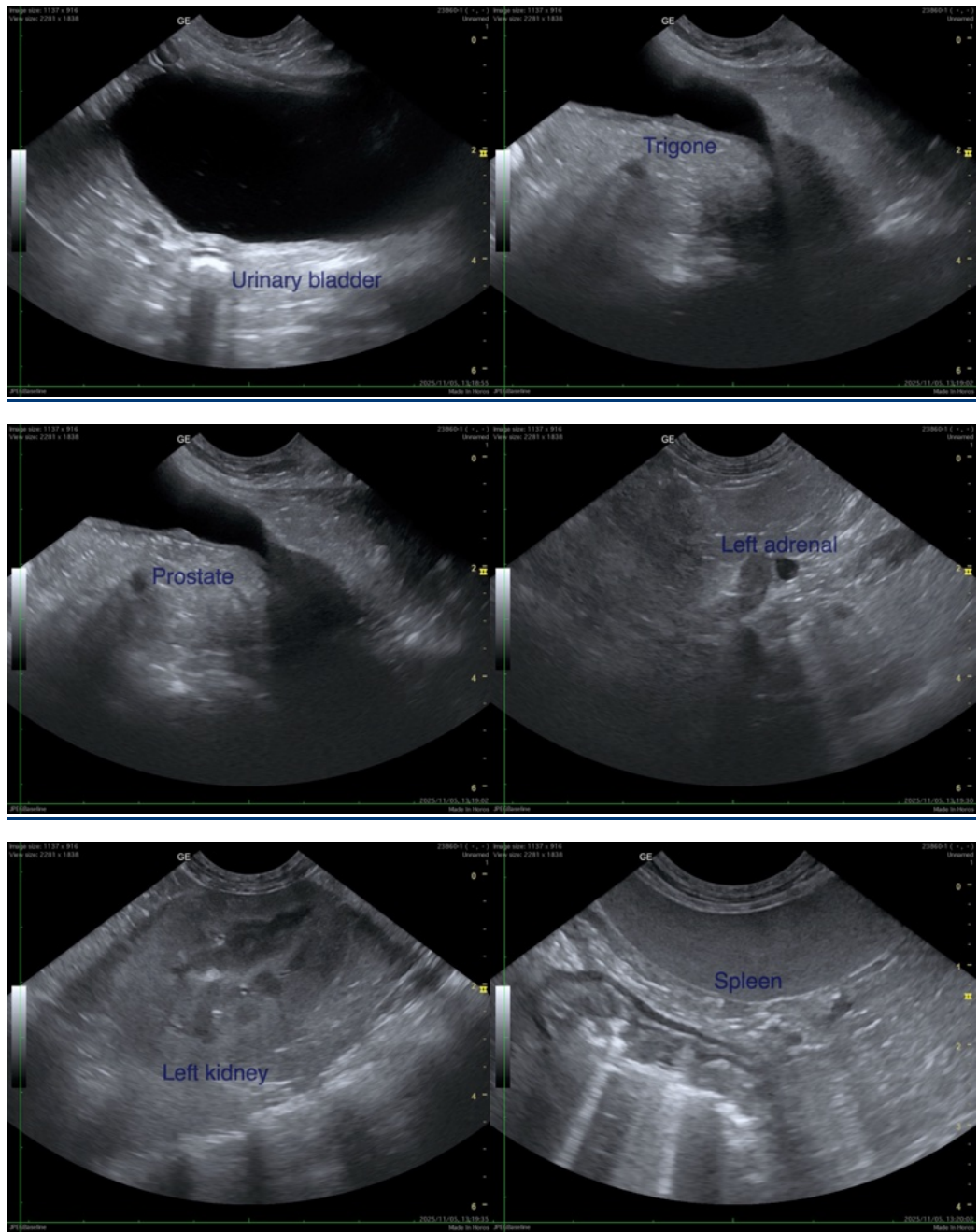
Dr. Pascucci

INVOICE

68351

DATE

11/5/25





PATIENT

Franklin Nitzl

SPECIES

Canine

BREED

Mix

SEX

Neutered male

AGE

14 years

WEIGHT

17 lbs

INTERPRETED BY

Remo Lobetti, BVSc,
MMedVet (Med),
PhD, Dipl. ECVIM

IMAGING PERFORMED BY

Dr. Pascucci

HOSPITAL NAME

American AH

REFERRING VET

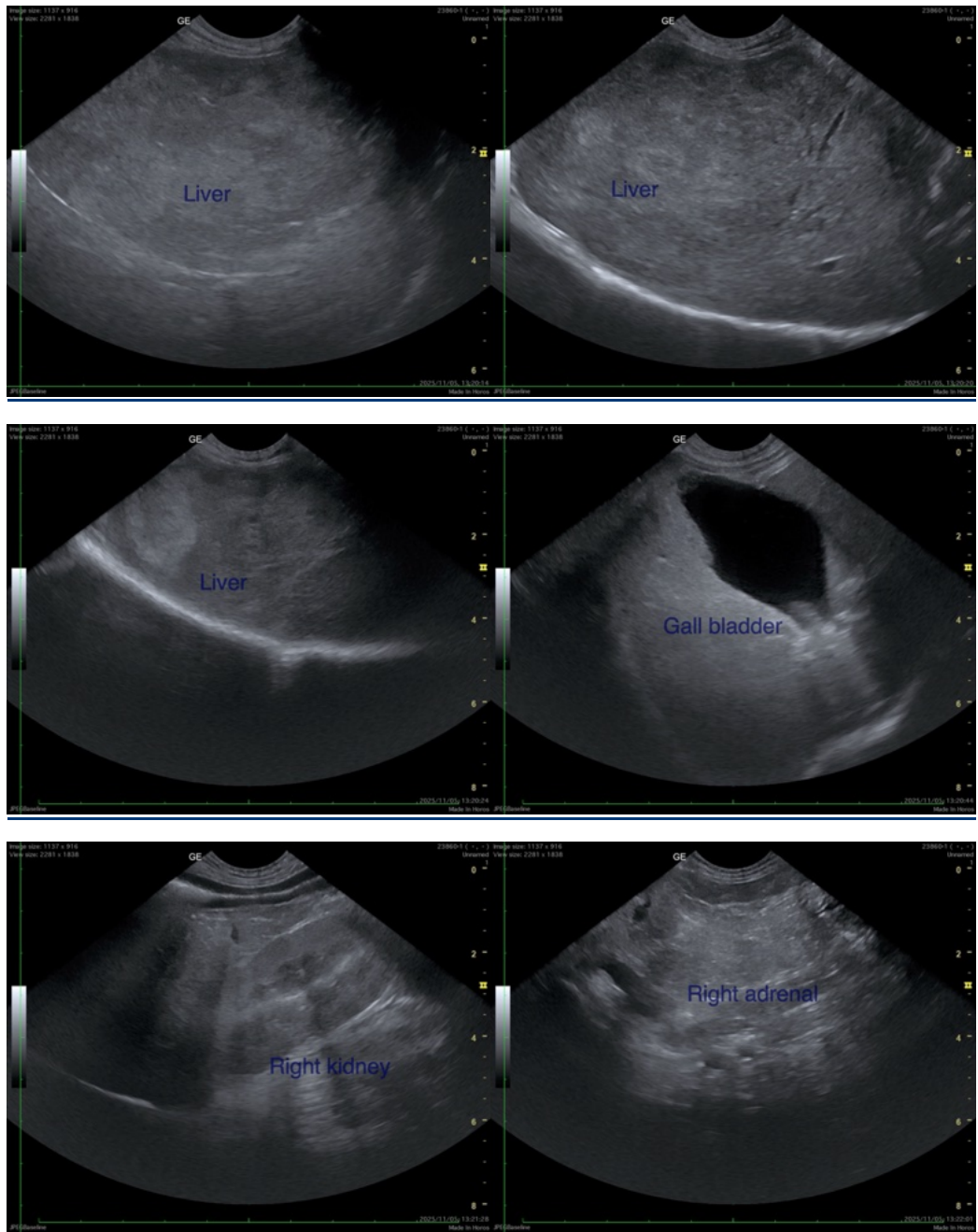
Dr. Pascucci

INVOICE

68351

DATE

11/5/25





PATIENT

Franklin Nitzl

SPECIES

Canine

BREED

Mix

SEX

Neutered male

AGE

14 years

WEIGHT

17 lbs

INTERPRETED BY

Remo Lobetti, BVSc,
MMedVet (Med),
PhD, Dipl. ECVIM

IMAGING PERFORMED BY

Dr. Pascucci

HOSPITAL NAME

American AH

REFERRING VET

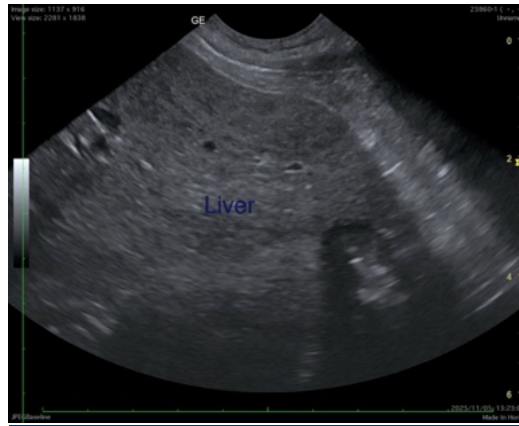Dr. Pascucci

INVOICE

68351

DATE

11/5/25



The information and recommendations provided are based on the images presented by the referring veterinarian/sonographer. No evaluation can be communicated regarding pathology that was not visible in the image/video clips provided.

Thank you for this referral. If the clinical or image interpretation does not parallel your findings or if I can be of any further assistance please contact me.

Remo Lobetti, BVSc, MMedVet (Med), PhD, Dipl. ECVIM (Internal Medicine)

info@sonopath.com