



PATIENT

Ellie Price

SPECIES

Canine

BREED

Golden

SEX

Spayed female

AGE

9 years

WEIGHT

92 lbs

INTERPRETED BY

Remo Lobetti, BVSc,
MMedVet (Med),
PhD, Dipl. ECVIM

IMAGING PERFORMED BY

Dr. Smatt

HOSPITAL NAME

The Pets I Love

REFERRING VET

Dr. Szpicek

INVOICE

68326

DATE

11/5/25

PRESENTING CLINICAL SIGNS

History: Patient was placed under anesthesia for procedure. Had hypovolemic event in recovering after procedure. Then within 24 hours post op had a seizure. Patient is acting normal since. Blood work was wnl. Ultrasound to r/o any abnormalities.

Abnormal PE/Chem/CBC/UA Results: CBC - wnl Chem - wnl U/A - wnl

ULTRASONOGRAPHIC EXAMINATION OF THE ABDOMEN

Urinary System

The urinary bladder is full with a thickened and irregular appearance of the apical wall. The rest of the wall has a normal thickness and smooth appearance. Normal anechoic urine with no sediment or uroliths evident.

Normal appearance of the trigone area, proximal urethra, and iliac blood vessels.

Normal appearance and size of the iliac lymph nodes. Ureters not visualized, which can be considered a normal finding.

Normal renal size (left measured 6.5 cm, right measured 6.1 cm), architecture, echogenic appearance, cortico-medullary differentiation, which maintains a 1:3 cortex to medulla ratio, pelvis, and capsule. No infarcts, mineralization or renoliths evident.

Adrenal Glands

Normal shape, echogenic appearance, size, position, and appearance of the visible peri-adrenal vasculature. Left adrenal gland measured 0.45 cm x 0.56 cm in width. The right adrenal gland measured 0.66 cm in width.

Spleen

Normal size and echogenic appearance. Smooth homogenous parenchyma and regular curvilinear capsule. Normal volume of the splenic vasculature without any overt congestion or thrombosis evident. No inflammatory, neoplastic, infarction, or infiltrative changes evident. The spleen measured 2.4 cm in width.

Liver

Normal size, echogenic appearance, portal markings, and regular curvilinear capsule. No nodules or masses evident. Normal appearance of the hepatic and portal vasculature.



PATIENT

Ellie Price

SPECIES

Canine

BREED

Golden

SEX

Spayed female

AGE

9 years

WEIGHT

92 lbs

INTERPRETED BY

Remo Lobetti, BVSc,
MMedVet (Med),
PhD, Dipl. ECVIM

IMAGING PERFORMED BY

Dr. Smatt

HOSPITAL NAME

The Pets I Love

REFERRING VET

Dr. Szpicek

INVOICE

68326

DATE

11/5/25

Gallbladder

The gallbladder is full containing normal anechoic bile. Normal thickness and echogenic appearance of the wall. Normal size and appearance of the cystic and common bile duct.

Gastrointestinal

Normal appearance of the stomach, duodenum, small intestine, ileo-cecal junction, and colon with no loss of layering, 1:3 muscularis to mucosa ratio, normal wall thickness and peristaltic activity, and no distension of the lumen.

Pancreas

The pancreas was poorly visualized, but the visible sections of the pancreas are of normal size and echogenic appearance with a regular capsule. Normal echogenic appearance of the mesentery and fat surrounding the pancreas.

Free Abdomen

Normal mesenteric lymph nodes.

No ascites evident.

ULTRASONOGRAPHIC FINDINGS

- Urinary bladder thickening.

INTERPRETATION OF THE FINDINGS & FURTHER RECOMMENDATIONS

Etiologies for the urinary bladder thickening would be chronic bacterial cystitis, granulomatous disease and emerging neoplasia.

Further assessment would be urine culture, BRAF analysis and/or a catheter assisted aspirate/biopsy of the urinary bladder wall for cytology/histopathology and culture.

Specific therapy would be dependent on an etiological diagnosis.



PATIENT

Ellie Price

SPECIES

Canine

BREED

Golden

SEX

Spayed female

AGE

9 years

WEIGHT

92 lbs

INTERPRETED BY

Remo Lobetti, BVSc,
MMedVet (Med),
PhD, Dipl. ECVIM

IMAGING PERFORMED BY

Dr. Smatt

HOSPITAL NAME

The Pets I Love

REFERRING VET

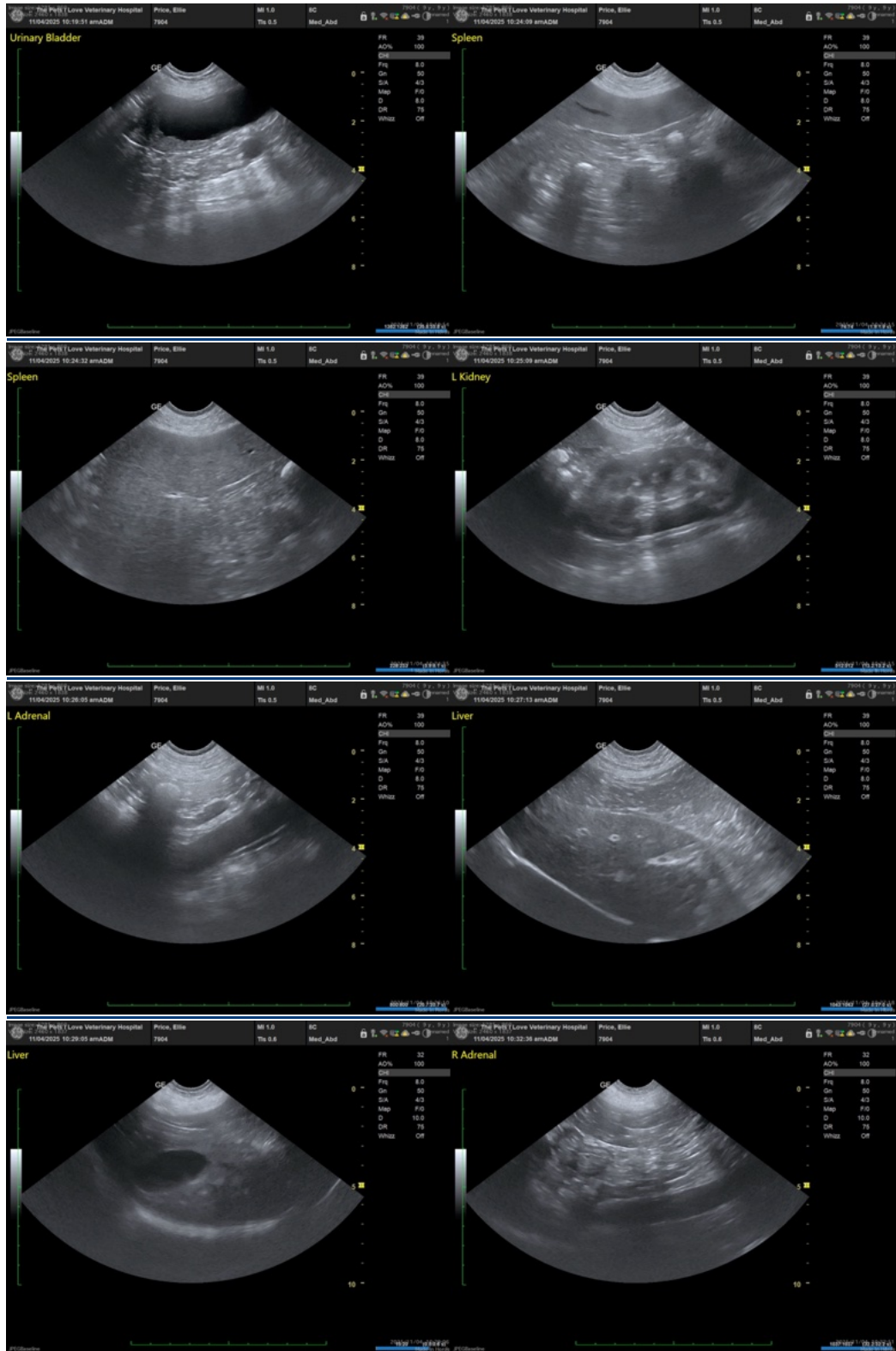
Dr. Szpicek

INVOICE

68326

DATE

11/5/25





PATIENT

Ellie Price

The information and recommendations provided are based on the images presented by the referring veterinarian/sonographer. No evaluation can be communicated regarding pathology that was not visible in the image/video clips provided.

SPECIES

Canine

Thank you for this referral. If the clinical or image interpretation does not parallel your findings or if I can be of any further assistance please contact me.

BREED

Golden

Remo Lobetti, BVSc, MMedVet (Med), PhD, Dipl. ECVIM (Internal Medicine)

info@sonopath.com

SEX

Spayed female

AGE

9 years

WEIGHT

92 lbs

INTERPRETED BY

Remo Lobetti, BVSc,
MMedVet (Med),
PhD, Dipl. ECVIM

IMAGING PERFORMED BY

Dr. Smatt

HOSPITAL NAME

The Pets I Love

REFERRING VET

Dr. Szpicek

INVOICE

68326

DATE

11/5/25