



PATIENT

Boston Good

SPECIES

Canine

BREED

Miniature Pinscher

SEX

Spayed female

AGE

10 years

WEIGHT

3.66 kg

INTERPRETED BY

Remo Lobetti, BVSc,
MMedVet (Med),
PhD, Dipl. ECVIM

IMAGING PERFORMED BY

Danielle Jaspar RVT

HOSPITAL NAME

Orchard VC

REFERRING VET

Dr. Antonopoulos

INVOICE

68354

DATE

11/5/25

PRESENTING CLINICAL SIGNS

History: Few days of vomiting, inappetence. Did seem to improve with treatment of Cerenia and Omeprazole.

CBC: -mild neutrophilia Chemistry: -mild hyperglycemia -mild hypoproteinemia USG : 1.050

ULTRASONOGRAPHIC EXAMINATION OF THE ABDOMEN

Urinary System

The urinary bladder is small with a normal thickness and smooth appearance of the wall. Normal anechoic urine with no sediment or uroliths evident.

Normal appearance of the trigone area, proximal urethra, and iliac blood vessels.

Normal appearance and size of the iliac lymph nodes. Ureters not visualized, which can be considered a normal finding.

Normal renal size (left measured 3.6 cm, right measured 3.8 cm), architecture, echogenic appearance, cortico-medullary differentiation, which maintains a 1:3 cortex to medulla ratio, pelvis, and capsule. No infarcts, mineralization or renoliths evident. Normal color flow pattern is evident in both kidneys.

Adrenal Glands

Normal shape, echogenic appearance, size, position, and appearance of the visible peri-adrenal vasculature. Left adrenal gland measured 1.81 cm in length x 0.42 cm and 0.43 cm in width. The right adrenal gland measured 0.47 cm in width.

Spleen

Normal size and echogenic appearance. Smooth homogenous parenchyma and regular curvilinear capsule. Normal volume of the splenic vasculature without any overt congestion or thrombosis evident.

No inflammatory, neoplastic, infarction, or infiltrative changes evident. The spleen measured 1.1 cm in width.

Liver

Normal size, echogenic appearance, portal markings, and regular curvilinear capsule. No nodules or masses evident. Normal appearance of the hepatic and portal vasculature.

Gallbladder

The gallbladder is full containing a small amount of adhered, hyperechogenic sediment or a small polyp. Normal thickness and echogenic appearance of the wall. Normal size and appearance of the cystic and common bile duct.



PATIENT

Boston Good

SPECIES

Canine

BREED

Miniature Pinscher

SEX

Spayed female

AGE

10 years

WEIGHT

3.66 kg

INTERPRETED BY

Remo Lobetti, BVSc,
MMedVet (Med),
PhD, Dipl. ECVIM

IMAGING PERFORMED BY

Danielle Jaspar RVT

HOSPITAL NAME

Orchard VC

REFERRING VET

Dr. Antonopoulos

INVOICE

68354

DATE

11/5/25

Gastrointestinal

Normal appearance of the stomach, duodenum, ileo-cecal junction, and colon with no loss of layering, 1:3 muscularis to mucosa ratio, normal wall thickness and peristaltic activity, and no distension of the lumen. Normal thickness of the small intestine (up to 0.3 cm) with no loss of layering, but with an increase in the muscularis to mucosa ratio, normal peristaltic activity and no distension of the lumen. A small amount of fluid was present in the stomach.

Pancreas

The visible sections of the pancreas are of normal size and echogenic appearance with a regular capsule. Normal echogenic appearance of the mesentery and fat surrounding the pancreas.

Free Abdomen

Normal mesenteric lymph nodes.

No ascites evident.

ULTRASONOGRAPHIC FINDINGS

- Enteropathy.
- Gallbladder sediment/polyp.

INTERPRETATION OF THE FINDINGS & FURTHER RECOMMENDATIONS

The likely etiologies for the enteropathy would be parasitic enteritis, dietary hypersensitivity and inflammatory bowel disease with emerging lymphoma an unlikely differential diagnosis.

The gallbladder sediment/polyp can be considered an incidental finding.

Further assessment would be fecal analysis, cobalamin and folate assay and endoscopy of the upper GI tract with biopsies.

Specific therapy would be dependent on an etiological diagnosis.

Symptomatic management that can be considered would be feeding small frequent meals of a novel protein/hypoallergenic diet, cobalamin supplementation, course of Fenbendazole and if there is still not a satisfactory improvement then a course of Prednisolone would then be indicated.



PATIENT

Boston Good

SPECIES

Canine

BREED

Miniature Pinscher

SEX

Spayed female

AGE

10 years

WEIGHT

3.66 kg

INTERPRETED BY

Remo Lobetti, BVSc,
MMedVet (Med),
PhD, Dipl. ECVIM

IMAGING PERFORMED BY

Danielle Jaspar RVT

HOSPITAL NAME

Orchard VC

REFERRING VET

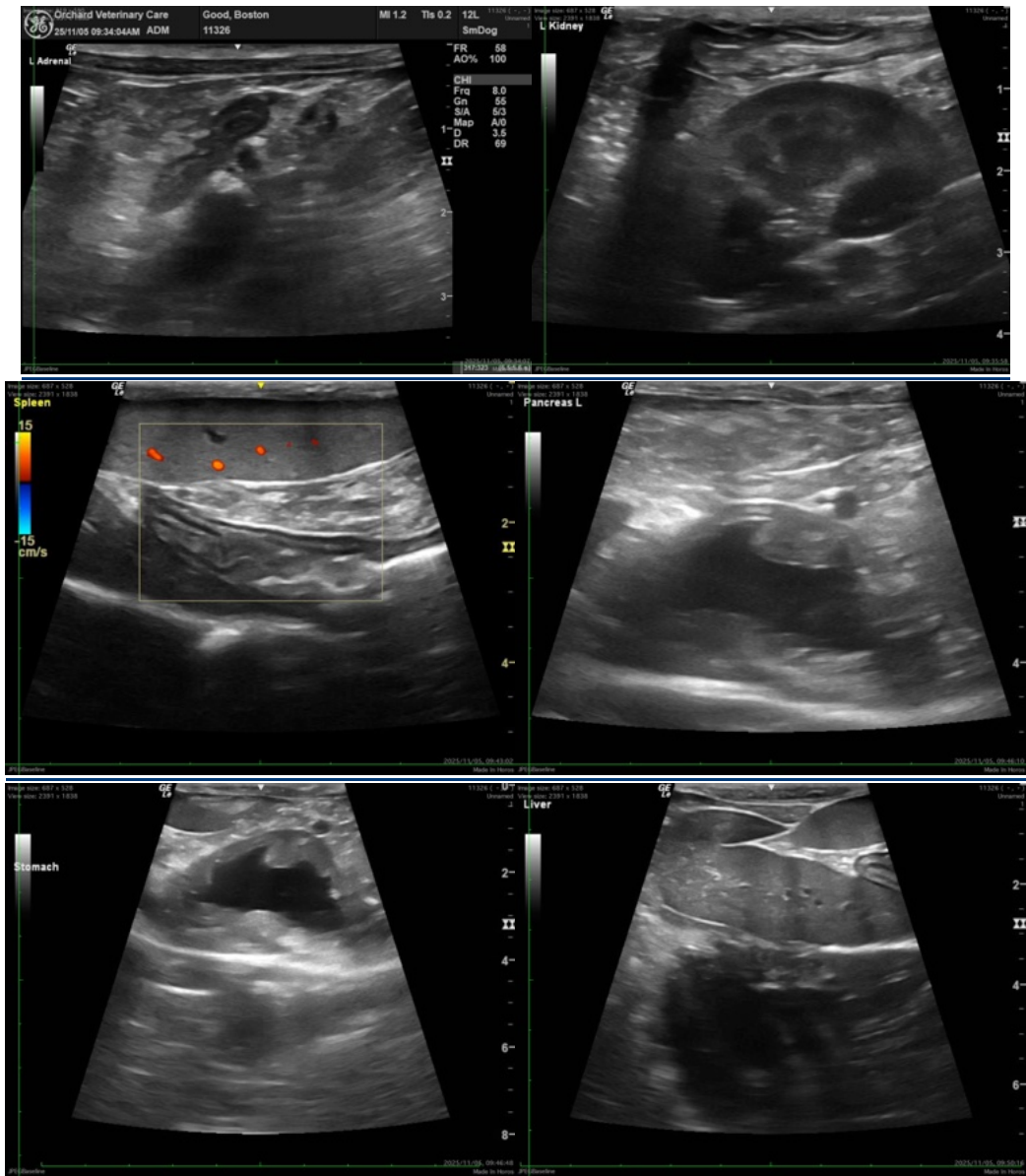
Dr. Antonopoulos

INVOICE

68354

DATE

11/5/25





PATIENT

Boston Good

SPECIES

Canine

BREED

Miniature Pinscher

SEX

Spayed female

AGE

10 years

WEIGHT

3.66 kg

INTERPRETED BY

Remo Lobetti, BVSc,
MMedVet (Med),
PhD, Dipl. ECVIM

IMAGING PERFORMED BY

Danielle Jaspar RVT

HOSPITAL NAME

Orchard VC

REFERRING VET

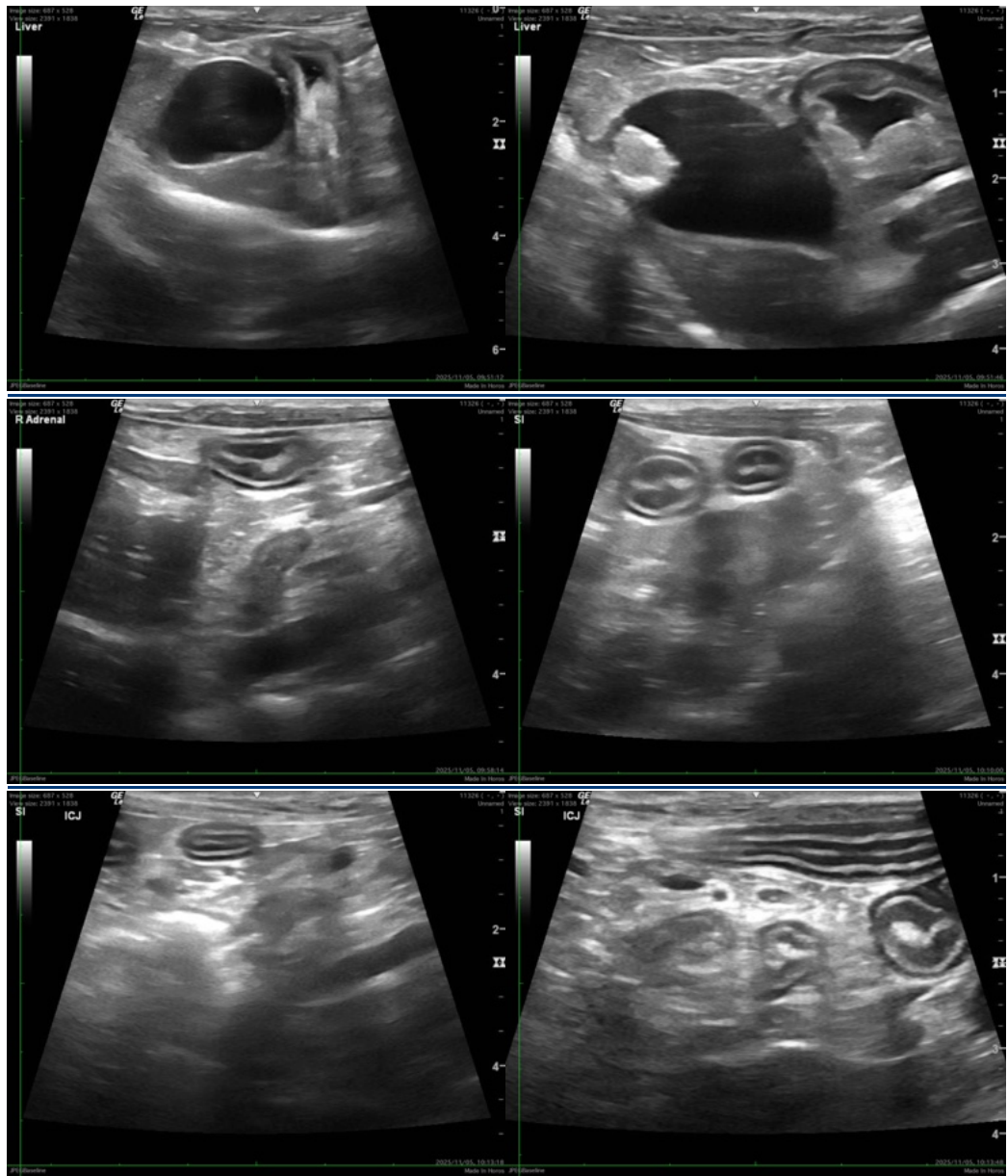
Dr. Antonopoulos

INVOICE

68354

DATE

11/5/25



The information and recommendations provided are based on the images presented by the referring veterinarian/sonographer. No evaluation can be communicated regarding pathology that was not visible in the image/video clips provided.

Thank you for this referral. If the clinical or image interpretation does not parallel your findings or if I can be of any further assistance please contact me.

Remo Lobetti, BVSc, MMedVet (Med), PhD, Dipl. ECVIM (Internal Medicine)

info@sonopath.com