



## PATIENT

Sadie West

## SPECIES

Canine

## BREED

Poodle Mix

## SEX

Spayed female

## AGE

11 years

## WEIGHT

14 lbs

## INTERPRETED BY

Remo Lobetti, BVSc,  
MMedVet (Med),  
PhD, Dipl. ECVIM

## IMAGING PERFORMED BY

Dr. Emilia Monachino

## HOSPITAL NAME

Finger Lakes AH  
Vetcor

## REFERRING VET

Dr. Monachino

## INVOICE

68321

## DATE

11/4/25

## PRESENTING CLINICAL SIGNS

History: Episodes of anxiety and restlessness, most severe at night and also decreased appetite. History of food intolerance. Appetite has improved since adding HA canned to the HA dry food. Concern for gastrointestinal discomfort vs. anxiety due to other cause. Melatonin did not help. Benadryl did help due to sedative side effect.

Abnormal PE/Chem/CBC/UA Results: 10/23/25- UA - 1.040, neg protein, no rbcs/ wbc/ bacteria or crystals. 2 hyaline casts- NSF. CBC - sl dec Eos 0.139, rest WNL. CHEM - dec PHOS 2.3, rest WNL. T4 low 0.9. 4dx & fecal all negative. No significant abnormalities on exam. Thoracic radiographs pending.

## ULTRASONOGRAPHIC EXAMINATION OF THE ABDOMEN

### Urinary System

The urinary bladder is full with a normal thickness and smooth appearance of the wall. Normal anechoic urine with no sediment or uroliths evident.

Normal appearance of the trigone area, proximal urethra, and iliac blood vessels.

Normal appearance and size of the iliac lymph nodes. Ureters not visualized, which can be considered a normal finding.

Normal renal size (left measured 4.1 cm, right measured 3.9 cm), architecture, echogenic appearance, cortico-medullary differentiation, which maintains a 1:3 cortex to medulla ratio, pelvis, and capsule. No infarcts, mineralization or renoliths evident. Normal color flow pattern is evident in both kidneys.

### Adrenal Glands

Normal shape, echogenic appearance, size, position, and appearance of the visible peri-adrenal vasculature. Left adrenal gland measured 1.54 cm in length x 0.33 cm and 0.38 cm in width. The right adrenal gland measured 1.77 cm in length x 0.59 cm and 0.3 cm in width.

### Spleen

Normal size and echogenic appearance. Smooth homogenous parenchyma and regular curvilinear capsule. Normal volume of the splenic vasculature without any overt congestion or thrombosis evident. No inflammatory, neoplastic, infarction, or infiltrative changes evident. The spleen measured 1.5 cm in width.

### Liver

Normal size, echogenic appearance, portal markings, and regular curvilinear capsule. No nodules or masses evident. Normal appearance of the hepatic and portal vasculature.



## PATIENT

Sadie West

## SPECIES

Canine

## BREED

Poodle Mix

## SEX

Spayed female

## AGE

11 years

## WEIGHT

14 lbs

## INTERPRETED BY

Remo Lobetti, BVSc,  
MMedVet (Med),  
PhD, Dipl. ECVIM

## IMAGING PERFORMED BY

Dr. Emilia Monachino

## HOSPITAL NAME

Finger Lakes AH  
Vetcor

## REFERRING VET

Dr. Monachino

## INVOICE

68321

## DATE

11/4/25

## Gallbladder

The gallbladder is full containing normal anechoic bile. Normal thickness and echogenic appearance of the wall. Normal size and appearance of the cystic and common bile duct.

## Gastrointestinal

Normal appearance of the stomach, duodenum, small intestine, ileo-cecal junction, and colon with no loss of layering, 1:3 muscularis to mucosa ratio, normal wall thickness and peristaltic activity, and no distension of the lumen.

## Pancreas

The visible sections of the pancreas are of normal size and echogenic appearance with a regular capsule. Normal echogenic appearance of the mesentery and fat surrounding the pancreas.

## Free Abdomen

Normal mesenteric lymph nodes measuring up to 0.2 cm in width.

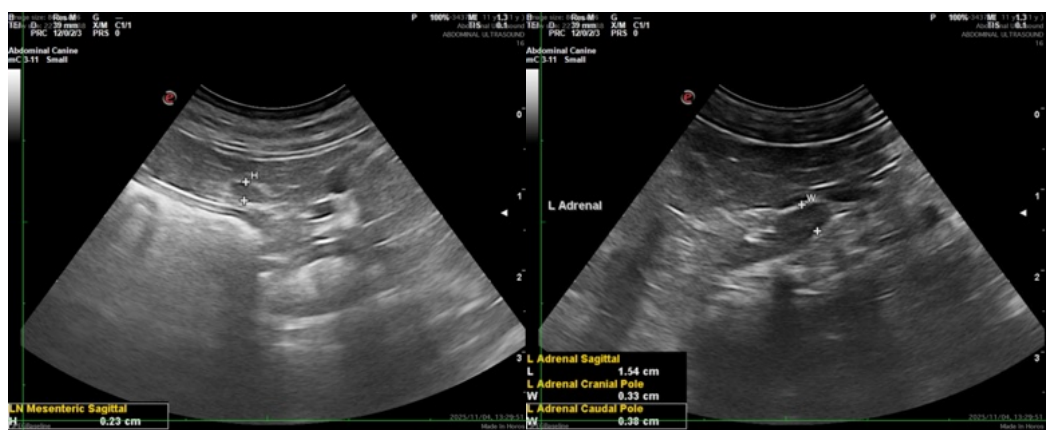
No ascites evident.

## ULTRASONOGRAPHIC FINDINGS

- Normal ultrasound examination of the abdomen.

## INTERPRETATION OF THE FINDINGS & FURTHER RECOMMENDATIONS

Continue feeding a hypoallergenic diet would be recommended.





## PATIENT

Sadie West

## SPECIES

Canine

## BREED

Poodle Mix

## SEX

Spayed female

## AGE

11 years

## WEIGHT

14 lbs

## INTERPRETED BY

Remo Lobetti, BVSc,  
MMedVet (Med),  
PhD, Dipl. ECVIM

## IMAGING PERFORMED BY

Dr. Emilia Monachino

## HOSPITAL NAME

Finger Lakes AH  
Vetcor

## REFERRING VET

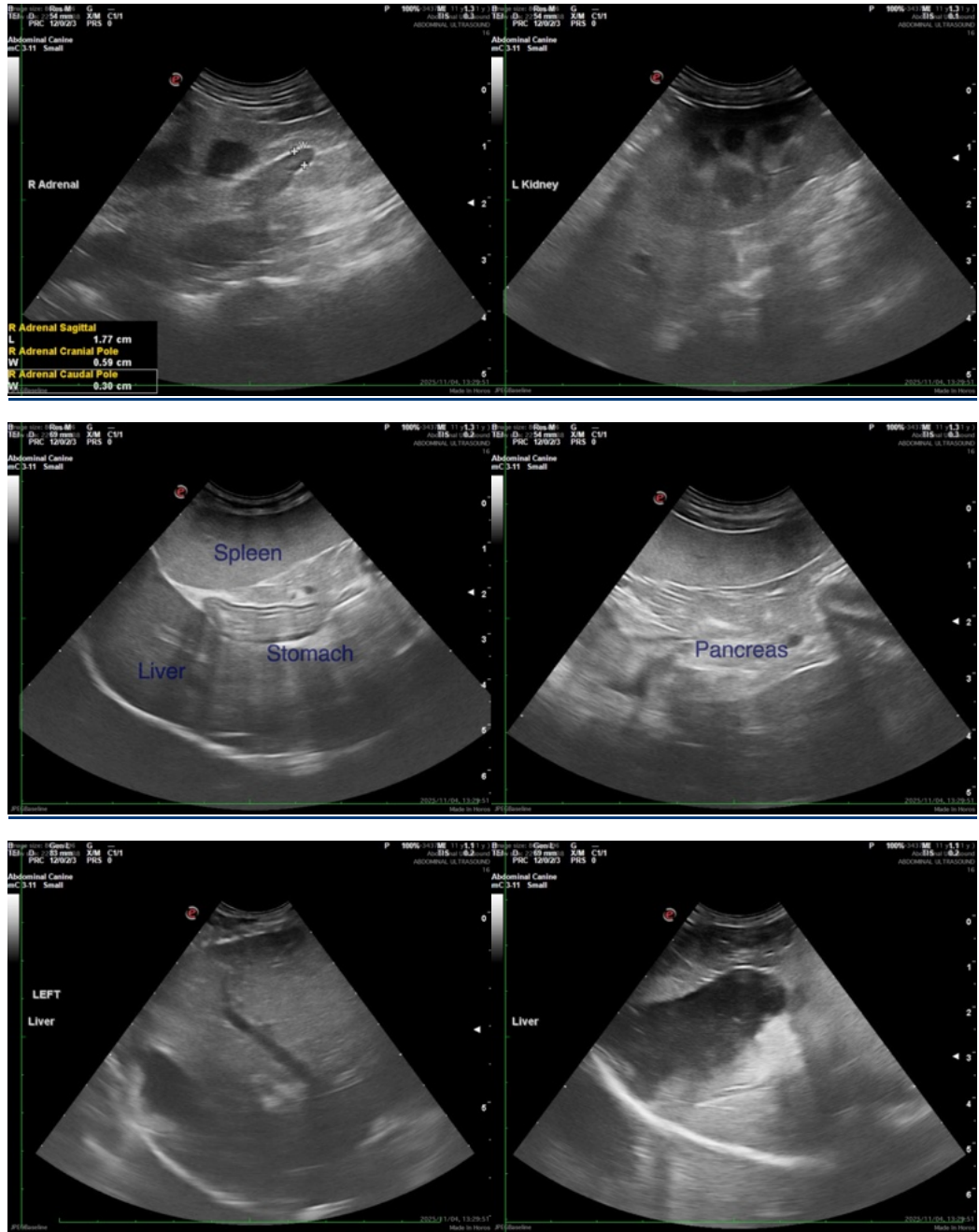
Dr. Monachino

## INVOICE

68321

## DATE

11/4/25





## PATIENT

Sadie West

## SPECIES

Canine

## BREED

Poodle Mix

## SEX

Spayed female

## AGE

11 years

## WEIGHT

14 lbs

## INTERPRETED BY

Remo Lobetti, BVSc,  
MMedVet (Med),  
PhD, Dipl. ECVIM

## IMAGING PERFORMED BY

Dr. Emilia Monachino

## HOSPITAL NAME

Finger Lakes AH  
Vetcor

## REFERRING VET

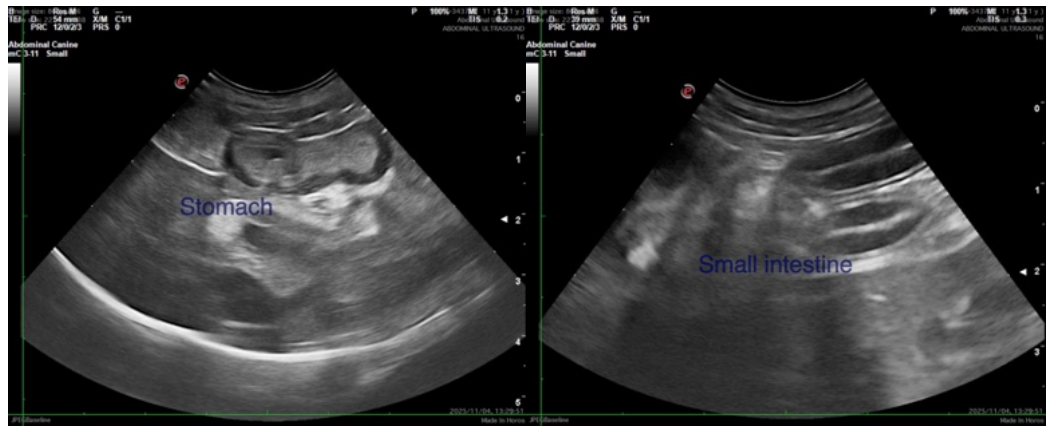
Dr. Monachino

## INVOICE

68321

## DATE

11/4/25



The information and recommendations provided are based on the images presented by the referring veterinarian/sonographer. No evaluation can be communicated regarding pathology that was not visible in the image/video clips provided.

Thank you for this referral. If the clinical or image interpretation does not parallel your findings or if I can be of any further assistance please contact me.

Remo Lobetti, BVSc, MMedVet (Med), PhD, Dipl. ECVIM (Internal Medicine)

[info@sonopath.com](mailto:info@sonopath.com)