



## PATIENT

Dublin Ebert

## SPECIES

Canine

## BREED

Canine

## SEX

Cavalier Mix

## AGE

2 years

## WEIGHT

21.2 lbs

## INTERPRETED BY

Remo Lobetti, BVSc,  
MMedVet (Med),  
PhD, Dipl. ECVIM

## IMAGING PERFORMED BY

Dr. Leanna Boyd

## HOSPITAL NAME

Oakridge VC

## REFERRING VET

Dr. Boyd

## INVOICE

68286

## DATE

11/3/25

## PRESENTING CLINICAL SIGNS

History: Patient presents for persistent nighttime urinary incontinence. Multiple urine cultures have been negative with no crystals or casts present on urinalysis.

## ULTRASONOGRAPHIC EXAMINATION OF THE ABDOMEN

### *Urinary System*

The urinary bladder is full with a normal thickness and smooth appearance of the wall. A scant amount of floating, hyperechogenic sediment is noted.

Normal appearance of the trigone area, proximal urethra, and iliac blood vessels.

Normal appearance and size of the iliac lymph nodes. Ureters not visualized, which can be considered a normal finding.

Normal renal size (left measured 4.6 cm, right measured 4.8 cm), architecture, echogenic appearance, cortico-medullary differentiation, which maintains a 1:3 cortex to medulla ratio, pelvis, and capsule. No infarcts, mineralization or renoliths evident. Normal color flow pattern is evident in both kidneys.

### *Adrenal Glands*

Normal shape, echogenic appearance, size, position, and appearance of the visible peri-adrenal vasculature. Left adrenal gland measured 0.42 cm in width. The right adrenal gland measured 0.48 cm in width.

### *Spleen*

Normal size and echogenic appearance. Smooth homogenous parenchyma and regular curvilinear capsule. Normal volume of the splenic vasculature without any overt congestion or thrombosis evident. No inflammatory, neoplastic, infarction, or infiltrative changes evident. The spleen measured 1.8 cm in width.

### *Liver*

Normal size, echogenic appearance, portal markings, and regular curvilinear capsule. No nodules or masses evident. Normal appearance of the hepatic and portal vasculature.

### *Gallbladder*

The gallbladder is full containing normal anechoic bile. Normal thickness and echogenic appearance of the wall. Normal size and appearance of the cystic and common bile duct.



## PATIENT

Dublin Ebert

## SPECIES

Canine

## BREED

Canine

## SEX

Cavalier Mix

## AGE

2 years

## WEIGHT

21.2 lbs

## INTERPRETED BY

Remo Lobetti, BVSc,  
MMedVet (Med),  
PhD, Dipl. ECVIM

## IMAGING PERFORMED BY

Dr. Leanna Boyd

## HOSPITAL NAME

Oakridge VC

## REFERRING VET

Dr. Boyd

## INVOICE

68286

## DATE

11/3/25

## Gastrointestinal

Normal appearance of the stomach, duodenum, small intestine, ileo-cecal junction, and colon with no loss of layering, 1:3 muscularis to mucosa ratio, normal wall thickness and peristaltic activity, and no distension of the lumen.

## Pancreas

The visible sections of the pancreas are of normal size and echogenic appearance with a regular capsule. Normal echogenic appearance of the mesentery and fat surrounding the pancreas.

## Free Abdomen

Normal mesenteric lymph nodes.

No ascites evident.

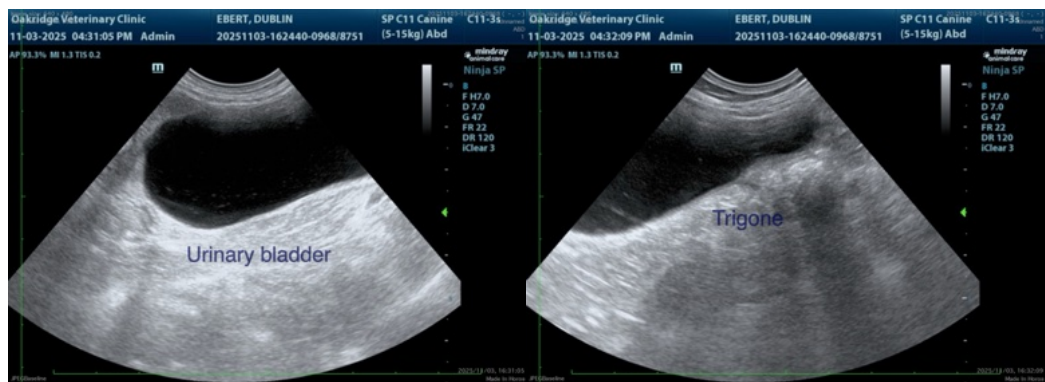
## ULTRASONOGRAPHIC FINDINGS

- On this ultrasound there is no obvious etiology for the urinary incontinence.

## INTERPRETATION OF THE FINDINGS & FURTHER RECOMMENDATIONS

The most likely etiology would be urethral sphincter incompetence.

Urinary incontinence in spayed female dogs is common, especially in medium to large breeds. It often develops months to years after spaying and is usually due to hormone-responsive incontinence. Initial management includes phenylpropanolamine and/or estrogen-replacement. In some cases deslorin can be added. In cases that are completely refractory to medical therapy the use of an artificial urethral sphincter (AUS) device should be considered.





**PATIENT**

Dublin Ebert

**SPECIES**

Canine

**BREED**

Canine

**SEX**

Cavalier Mix

**AGE**

2 years

**WEIGHT**

21.2 lbs

**INTERPRETED BY**

Remo Lobetti, BVSc,  
MMedVet (Med),  
PhD, Dipl. ECVIM

**IMAGING PERFORMED BY**

Dr. Leanna Boyd

**HOSPITAL NAME**

Oakridge VC

**REFERRING VET**

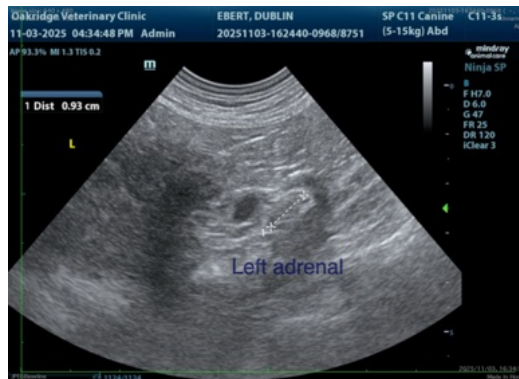
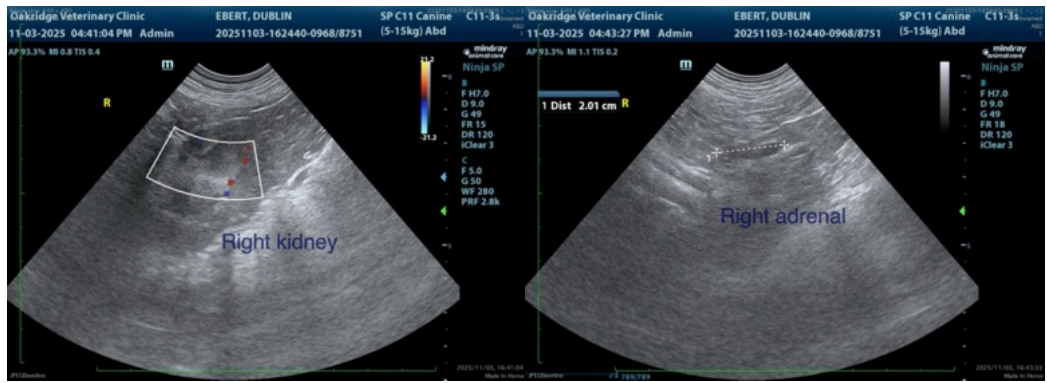
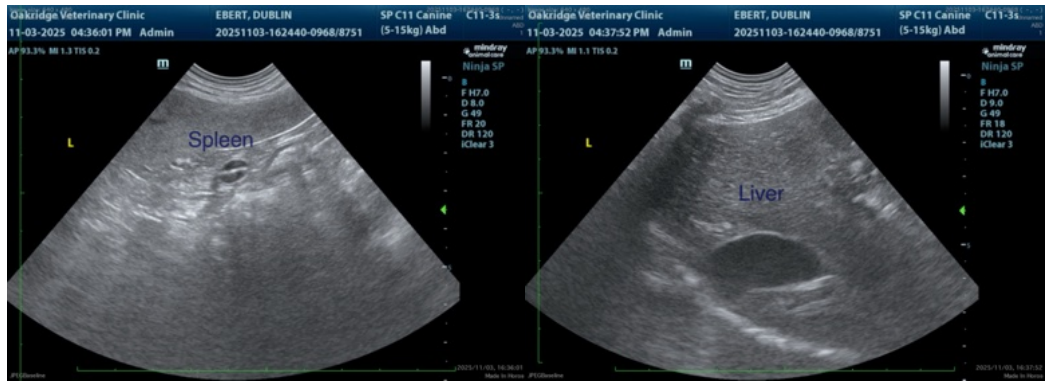
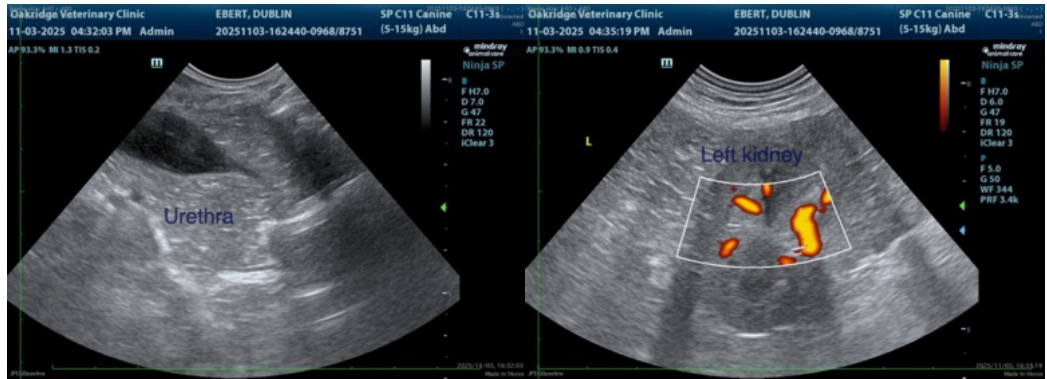
Dr. Boyd

**INVOICE**

68286

**DATE**

11/3/25





## PATIENT

Dublin Ebert

## SPECIES

Canine

## BREED

Canine

## SEX

Cavalier Mix

## AGE

2 years

## WEIGHT

21.2 lbs

## INTERPRETED BY

Remo Lobetti, BVSc,  
MMedVet (Med),  
PhD, Dipl. ECVIM

## IMAGING PERFORMED BY

Dr. Leanna Boyd

## HOSPITAL NAME

Oakridge VC

## REFERRING VET

Dr. Boyd

## INVOICE

68286

## DATE

11/3/25

The information and recommendations provided are based on the images presented by the referring veterinarian/sonographer. No evaluation can be communicated regarding pathology that was not visible in the image/video clips provided.

Thank you for this referral. If the clinical or image interpretation does not parallel your findings or if I can be of any further assistance please contact me.

Remo Lobetti, BVSc, MMedVet (Med), PhD, Dipl. ECVIM (Internal Medicine)

[info@sonopath.com](mailto:info@sonopath.com)