



PATIENT

Teeka Valentine

SPECIES

Canine

BREED

Miniature Schnauzer

SEX

Spayed female

AGE

9 years

WEIGHT

6 kg

INTERPRETED BY

Remo Lobetti, BVSc,
MMedVet (Med),
PhD, Dipl. ECVIM

IMAGING PERFORMED BY

Catherine Alexander,
LVT

HOSPITAL NAME

NorthStar Veterinary
Sonography

REFERRING VET

Dr. Robinson

INVOICE

68883

DATE

11/20/25

PRESENTING CLINICAL SIGNS

History: 10/21/25: splenectomy due to splenic mass. Stromal sarcoma grade 2, mitotic count 20. Hx of gb disease. Currently on ursodiol and metronidazole. No concerns, just staging today
Abnormal PE/Chem/CBC/UA Results: Grade 2/6 heart murmur

ULTRASONOGRAPHIC EXAMINATION OF THE ABDOMEN

Urinary System

The urinary bladder is full with a normal thickness and smooth appearance of the wall. Normal anechoic urine with no sediment or uroliths evident.

Normal appearance of the trigone area, proximal urethra, and iliac blood vessels.

Normal appearance and size of the iliac lymph nodes. Ureters not visualized, which can be considered a normal finding.

Normal renal size (left measured 4.3 cm, right measured 3.8 cm), architecture, echogenic appearance, cortico-medullary differentiation, which maintains a 1:3 cortex to medulla ratio, pelvis, and capsule. No infarcts, mineralization or renoliths evident. Normal color flow pattern is noted in both kidneys.

Adrenal Glands

Normal shape, echogenic appearance, size, position, and appearance of the visible peri-adrenal vasculature. Left adrenal gland measured 0.47 cm and 0.57 cm in width. The right adrenal gland measured 0.49 cm in width.

Spleen

The spleen was absent (previous splenectomy). Normal appearance of the anatomical area of the spleen.

Liver

Normal size, echogenic appearance, portal markings, and regular curvilinear capsule. No nodules or masses evident. Normal appearance of the hepatic and portal vasculature.

Gallbladder

The gallbladder is full containing normal anechoic bile. Normal thickness and echogenic appearance of the wall. Normal size and appearance of the cystic and common bile duct.



PATIENT

Teeka Valentine

SPECIES

Canine

BREED

Miniature Schnauzer

SEX

Spayed female

AGE

9 years

WEIGHT

6 kg

INTERPRETED BY

Remo Lobetti, BVSc,
MMedVet (Med),
PhD, Dipl. ECVIM

IMAGING PERFORMED BY

Catherine Alexander,
LVT

HOSPITAL NAME

NorthStar Veterinary
Sonography

REFERRING VET

Dr. Robinson

INVOICE

68883

DATE

11/20/25

Gastrointestinal

Normal appearance of the stomach, duodenum, small intestine, ileo-cecal junction, and colon with no loss of layering, 1:3 muscularis to mucosa ratio, normal wall thickness and peristaltic activity, and no distension of the lumen. The stomach measured 0.19 cm and the colon measured 0.16 cm.

Pancreas

The visible sections of the pancreas are of normal size and echogenic appearance with a regular capsule. Normal echogenic appearance of the mesentery and fat surrounding the pancreas.

Free Abdomen

Normal mesenteric lymph nodes.

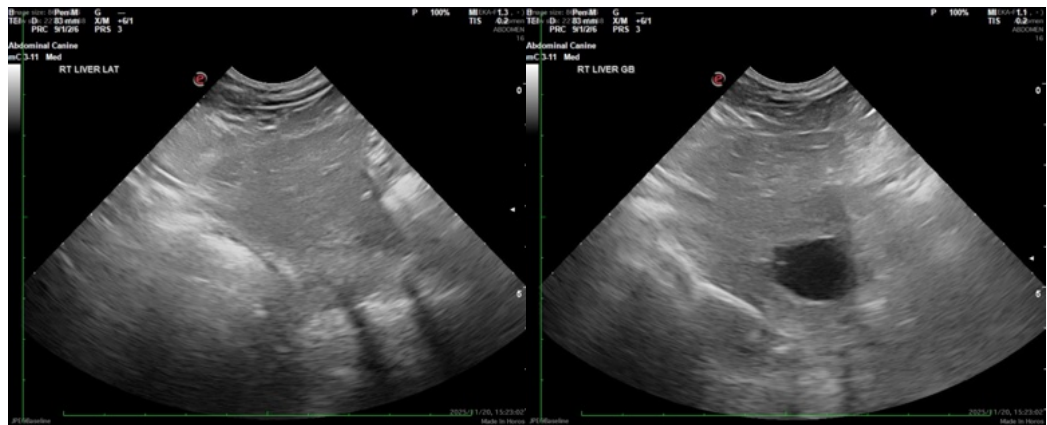
No ascites evident.

ULTRASONOGRAPHIC FINDINGS

- Normal ultrasound examination of the abdomen.

INTERPRETATION OF THE FINDINGS & FURTHER RECOMMENDATIONS

On this ultrasound there is no obvious evidence of metastatic disease.





PATIENT

Teeka Valentine

SPECIES

Canine

BREED

Miniature Schnauzer

SEX

Spayed female

AGE

9 years

WEIGHT

6 kg

INTERPRETED BY

Remo Lobetti, BVSc,
MMedVet (Med),
PhD, Dipl. ECVIM

IMAGING PERFORMED BY

Catherine Alexander,
LVT

HOSPITAL NAME

NorthStar Veterinary
Sonography

REFERRING VET

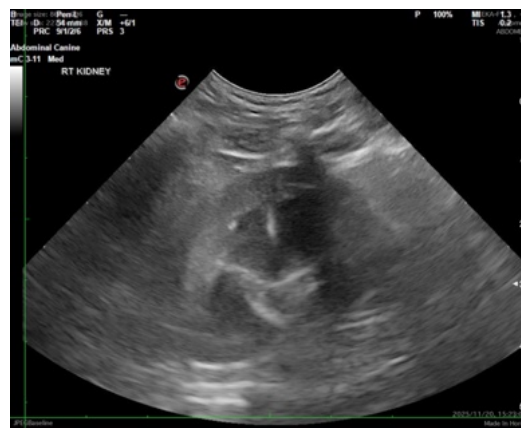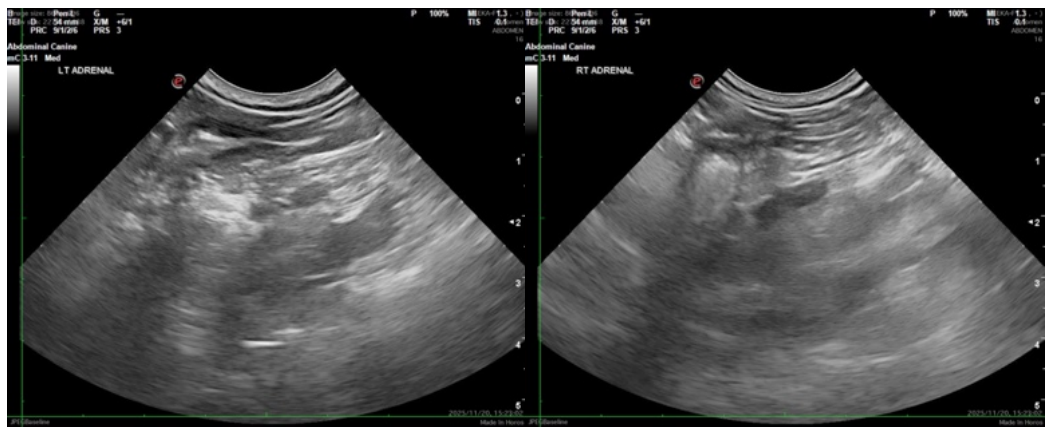
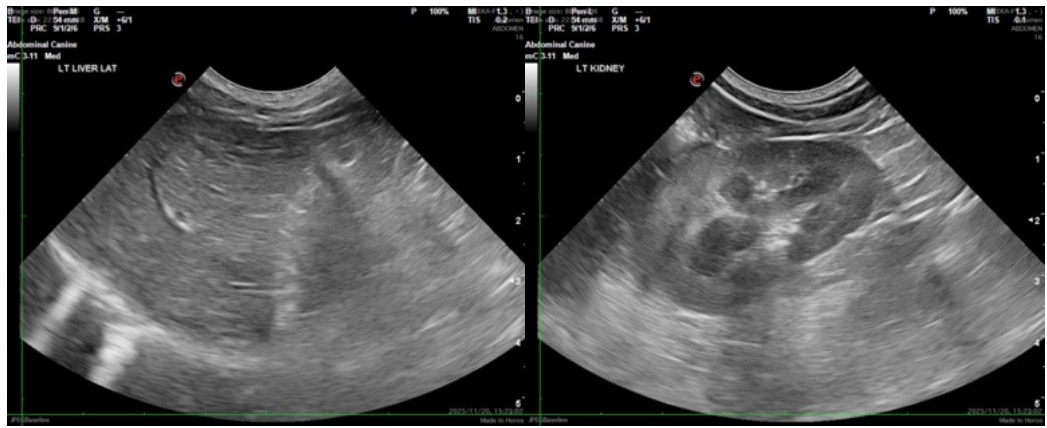
Dr. Robinson

INVOICE

68883

DATE

11/20/25



The information and recommendations provided are based on the images presented by the referring veterinarian/sonographer. No evaluation can be communicated regarding pathology that was not visible in the image/video clips provided.

Thank you for this referral. If the clinical or image interpretation does not parallel your findings or if I can be of any further assistance please contact me.

Remo Lobetti, BVSc, MMedVet (Med), PhD, Dipl. ECVIM (Internal Medicine)



PATIENT

info@sonopath.com

Teeka Valentine

SPECIES

Canine

BREED

Miniature Schnauzer

SEX

Spayed female

AGE

9 years

WEIGHT

6 kg

INTERPRETED BY

Remo Lobetti, BVSc,
MMedVet (Med),
PhD, Dipl. ECVIM

**IMAGING
PERFORMED BY**

Catherine Alexander,
LVT

HOSPITAL NAME

NorthStar Veterinary
Sonography

REFERRING VET

Dr. Robinson

INVOICE

68883

DATE

11/20/25