



PATIENT

Teddy Cox

SPECIES

Canine

BREED

Beagle Mix

SEX

Neutered male

AGE

9 years

WEIGHT

36 lbs

INTERPRETED BY

Remo Lobetti, BVSc,
MMedVet (Med),
PhD, Dipl. ECVIM

IMAGING PERFORMED BY

Tasha

HOSPITAL NAME

Dillsburg VC

REFERRING VET

Dr. Pryor

INVOICE

68876

DATE

11/20/25

PRESENTING CLINICAL SIGNS

History: Hypertensive, hyperadrenocorticism, weight loss, elevated liver enzymes
Abnormal PE/Chem/CBC/UA Results: Inc ALT, ALKP, GGTP, BUN/CREAT RATIO, PSL, PLT,
NEUTROPHILS, PROT/CREAT RATIO see attached

ULTRASONOGRAPHIC EXAMINATION OF THE ABDOMEN

Urinary System

The urinary bladder is full with a normal thickness and smooth appearance of the wall. Normal anechoic urine with no sediment or uroliths evident.

Normal appearance of the trigone area, proximal urethra, and iliac blood vessels.

Normal appearance and size of the iliac lymph nodes. Ureters not visualized, which can be considered a normal finding.

Normal renal size (left measured 5.8 cm, right measured 6.1 cm), architecture, echogenic appearance, cortico-medullary differentiation, which maintains a 1:3 cortex to medulla ratio, pelvis, and capsule. No infarcts, mineralization or renoliths evident.

Adrenal Glands

Normal shape, echogenic appearance, size, position, and appearance of the visible peri-adrenal vasculature. Left adrenal gland measured 0.53 cm and 0.48 cm in width. The right adrenal gland measured 0.64 cm in width.

Spleen

Normal size and echogenic appearance. Smooth homogenous parenchyma and regular curvilinear capsule. Normal volume of the splenic vasculature without any overt congestion or thrombosis evident. No inflammatory, neoplastic, infarction, or infiltrative changes evident. The spleen measured 1.5 cm in width.

Liver

The liver was enlarged with rounded edges, diffuse, increased echogenic and coarse appearance, normal portal markings, and regular curvilinear capsule. No nodules or masses evident. Normal appearance of the hepatic and portal vasculature.

Gallbladder

The gallbladder is full containing a moderate amount of non-adhered, hyperechogenic sediment. Normal thickness and echogenic appearance of the wall. Normal size and appearance of the cystic and common bile duct.



PATIENT

Teddy Cox

SPECIES

Canine

BREED

Beagle Mix

SEX

Neutered male

AGE

9 years

WEIGHT

36 lbs

INTERPRETED BY

Remo Lobetti, BVSc,
MMedVet (Med),
PhD, Dipl. ECVIM

IMAGING PERFORMED BY

Tasha

HOSPITAL NAME

Dillsburg VC

REFERRING VET

Dr. Pryor

INVOICE

68876

DATE

11/20/25

Gastrointestinal

Normal appearance of the stomach, duodenum, small intestine, ileo-cecal junction, and colon with no loss of layering, 1:3 muscularis to mucosa ratio, normal wall thickness and peristaltic activity, and no distension of the lumen. A moderate amount of ingesta is present in the stomach compatible with a recent meal.

Pancreas

The visible sections of the pancreas are of normal size and echogenic appearance with a regular capsule. Normal echogenic appearance of the mesentery and fat surrounding the pancreas.

Free Abdomen

Normal mesenteric lymph nodes.

No ascites evident.

ULTRASONOGRAPHIC FINDINGS

- Hepatopathy.
- Gallbladder sediment.

INTERPRETATION OF THE FINDINGS & FURTHER RECOMMENDATIONS

The most likely etiology for the hepatopathy would be metabolic secondary to the Cushing's disease with reactive hyperplasia and vacuolar hepatopathy differential diagnosis and hepatitis and infiltrative neoplasia highly unlikely differential diagnosis.

The gallbladder sediment is most likely an incidental finding, but needs to be monitored for the possible development of a mucocele.

Further assessment would be ACTH stimulation test (if not recently done) and possibly FNA cytology of the liver.

Further specific therapy would be dependent on an etiological diagnosis.



PATIENT

Teddy Cox

SPECIES

Canine

BREED

Beagle Mix

SEX

Neutered male

AGE

9 years

WEIGHT

36 lbs

INTERPRETED BY

Remo Lobetti, BVSc,
MMedVet (Med),
PhD, Dipl. ECVIM

IMAGING PERFORMED BY

Tasha

HOSPITAL NAME

Dillsburg VC

REFERRING VET

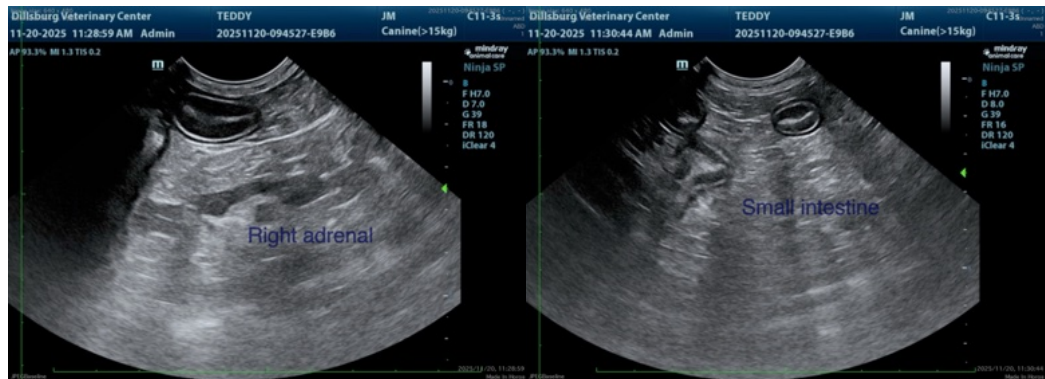
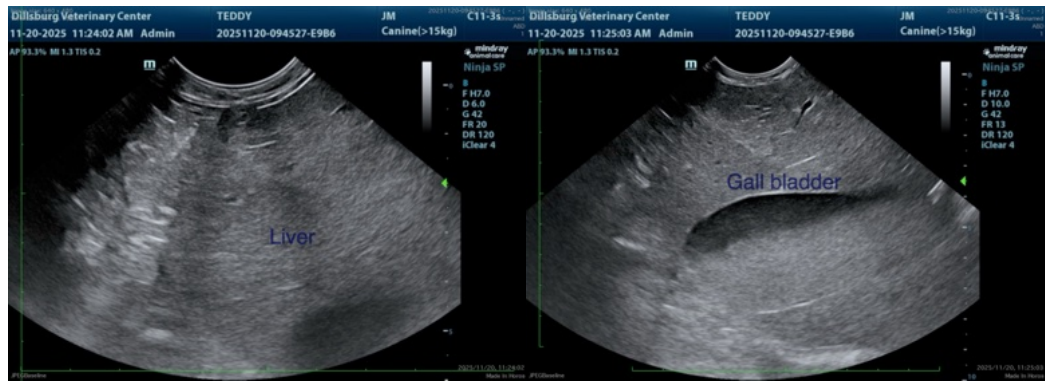
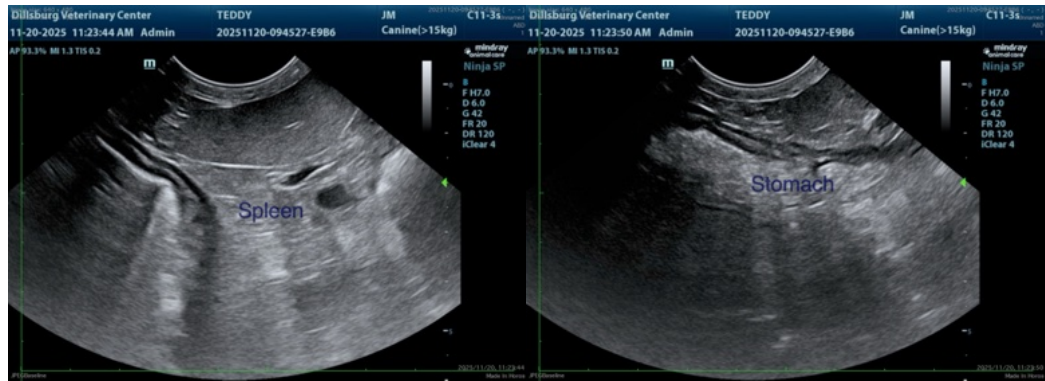
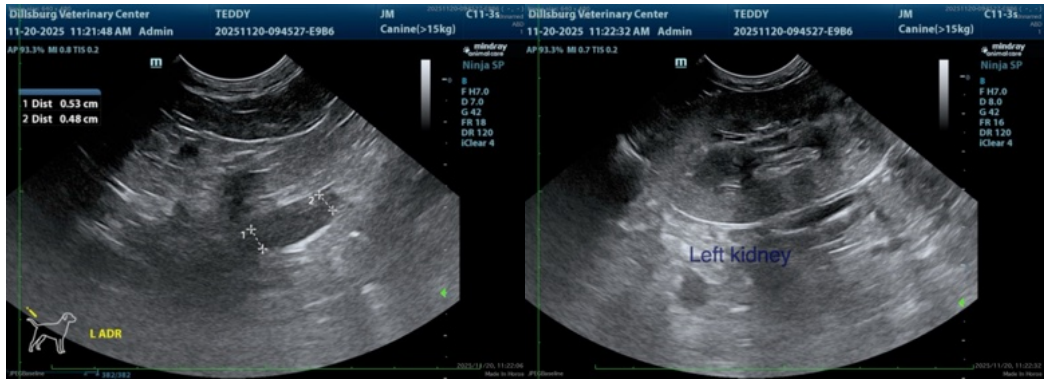
Dr. Pryor

INVOICE

68876

DATE

11/20/25





PATIENT

Teddy Cox

SPECIES

Canine

BREED

Beagle Mix

SEX

Neutered male

AGE

9 years

WEIGHT

36 lbs

INTERPRETED BY

Remo Lobetti, BVSc,
MMedVet (Med),
PhD, Dipl. ECVIM

IMAGING PERFORMED BY

Tasha

HOSPITAL NAME

Dillsburg VC

REFERRING VET

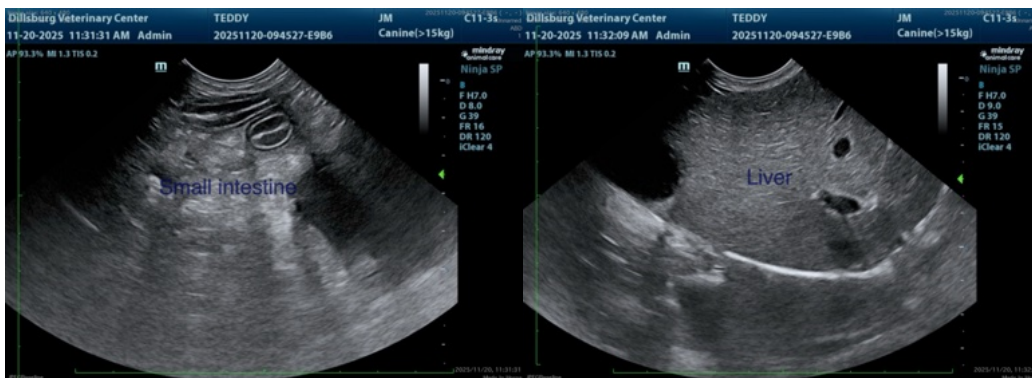
Dr. Pryor

INVOICE

68876

DATE

11/20/25



The information and recommendations provided are based on the images presented by the referring veterinarian/sonographer. No evaluation can be communicated regarding pathology that was not visible in the image/video clips provided.

Thank you for this referral. If the clinical or image interpretation does not parallel your findings or if I can be of any further assistance please contact me.

Remo Lobetti, BVSc, MMedVet (Med), PhD, Dipl. ECVIM (Internal Medicine)

info@sonopath.com