



## PATIENT

Daisy Herrington

## SPECIES

Canine

## BREED

Boxer Mix

## SEX

Spayed female

## AGE

7 years

## WEIGHT

62 lbs

## INTERPRETED BY

Remo Lobetti, BVSc,  
MMedVet (Med),  
PhD, Dipl. ECVIM

## IMAGING PERFORMED BY

Dr. Otto Williams

## HOSPITAL NAME

Animal Care Center of  
Smyrna

## REFERRING VET

Dr. Williams

## INVOICE

68822

## DATE

11/19/25

## PRESENTING CLINICAL SIGNS

History: Not eating as much as usual

Calcium 11.5 mg/dl 9.0-11.0 Magnesium 3.5 mg/dl 1.6- 3.3 Sodium 152 mEq/l 140-150 Total Protein 7.2 g/dL 5.1-6.9 Albumin 4.3 g/dl 2.7-3.9 ALT 530 U/L 17-115 GGT 11 U/L <9

## ULTRASONOGRAPHIC EXAMINATION OF THE ABDOMEN

### *Urinary System*

The urinary bladder is full with a normal thickness and smooth appearance of the wall. Normal anechoic urine with no sediment or uroliths evident.

Normal appearance of the trigone area, proximal urethra, and iliac blood vessels.

Normal appearance and size of the iliac lymph nodes. Ureters not visualized, which can be considered a normal finding.

Normal renal size (left measured 5.5 cm, right measured 5.9 cm), architecture, echogenic appearance, cortico-medullary differentiation, which maintains a 1:3 cortex to medulla ratio, pelvis, and capsule. No infarcts, mineralization or renoliths evident.

### *Adrenal Glands*

Normal shape, echogenic appearance, size, position, and appearance of the visible peri-adrenal vasculature. Left adrenal gland measured 0.51 cm and 0.58 cm in width. The right adrenal gland measured 0.59 cm in width.

### *Spleen*

Normal size and echogenic appearance. Smooth homogenous parenchyma and regular curvilinear capsule. Normal volume of the splenic vasculature without any overt congestion or thrombosis evident.

No inflammatory, neoplastic, infarction, or infiltrative changes evident. The spleen measured 2.1 cm in width.

### *Liver*

Normal size with a diffuse, increased echogenic and coarse appearance, prominent portal markings, and regular curvilinear capsule. No nodules or masses evident. Normal appearance of the hepatic and portal vasculature.

### *Gallbladder*

The gallbladder is full containing normal anechoic bile. Normal thickness and echogenic appearance of the wall. Normal size and appearance of the cystic and common bile duct.



**PATIENT**

Daisy Herrington

**SPECIES**

Canine

**BREED**

Boxer Mix

**SEX**

Spayed female

**AGE**

7 years

**WEIGHT**

62 lbs

**INTERPRETED BY**

Remo Lobetti, BVSc,  
MMedVet (Med),  
PhD, Dipl. ECVIM

**IMAGING PERFORMED BY**

Dr. Otto Williams

**HOSPITAL NAME**

Animal Care Center of  
Smyrna

**REFERRING VET**

Dr. Williams

**INVOICE**

68822

**DATE**

11/19/25

**Gastrointestinal**

Normal appearance of the stomach, duodenum, small intestine, ileo-cecal junction, and colon with no loss of layering, 1:3 muscularis to mucosa ratio, normal wall thickness and peristaltic activity, and no distension of the lumen. A small amount of ingesta was present in the stomach, compatible with a recent meal.

**Pancreas**

The visible sections of the pancreas are of normal size and echogenic appearance with a regular capsule. Normal echogenic appearance of the mesentery and fat surrounding the pancreas.

**Free Abdomen**

Normal mesenteric lymph nodes.  
No ascites evident.

**ULTRASONOGRAPHIC FINDINGS**

- Hepatopathy.

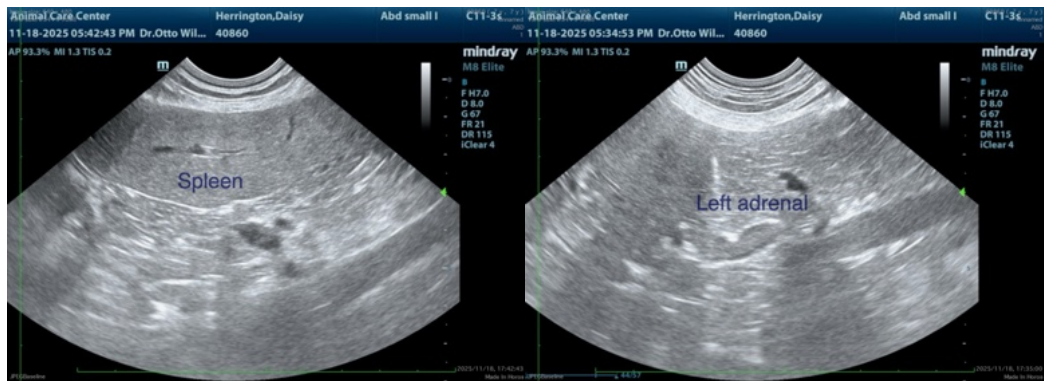
**INTERPRETATION OF THE FINDINGS & FURTHER RECOMMENDATIONS**

The likely etiologies for the hepatopathy would be reactive hyperplasia, early nodular hyperplasia, vacuolar and metabolic with hepatitis and infiltrative neoplasia a less likely differential diagnosis.

Further assessment would be FNA cytology of the liver; however, a tru cut or wedge biopsy may be required for a final etiological diagnosis.

Specific therapy would be dependent on an etiological diagnosis.

Symptomatic management that can be considered would be the use of Ursodiol with regular monitoring of liver enzyme activity.





**PATIENT**

Daisy Herrington

**SPECIES**

Canine

**BREED**

Boxer Mix

**SEX**

Spayed female

**AGE**

7 years

**WEIGHT**

62 lbs

**INTERPRETED BY**

Remo Lobetti, BVSc,  
MMedVet (Med),  
PhD, Dipl. ECVIM

**IMAGING PERFORMED BY**

Dr. Otto Williams

**HOSPITAL NAME**

Animal Care Center of  
Smyrna

**REFERRING VET**

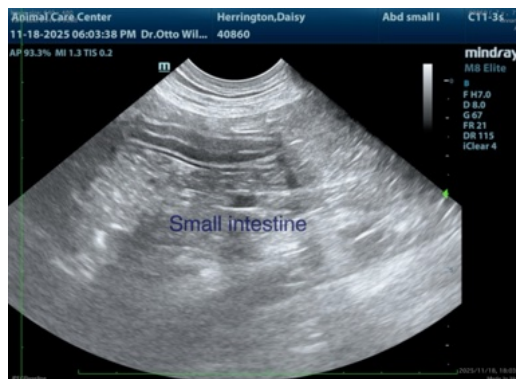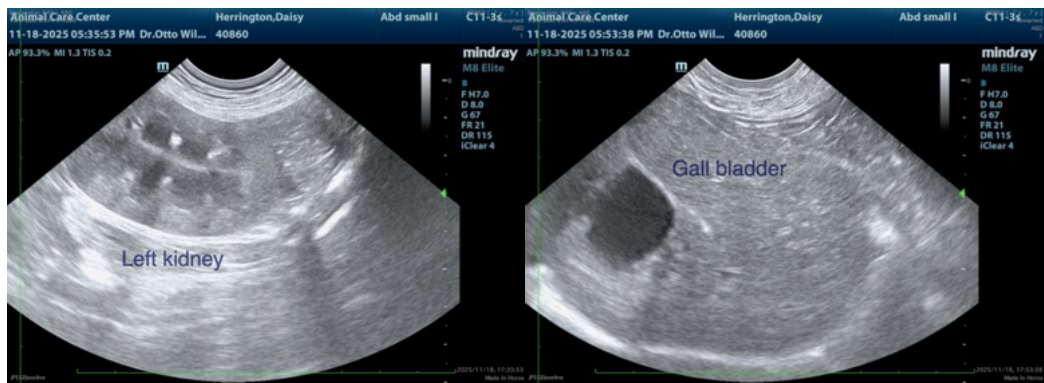
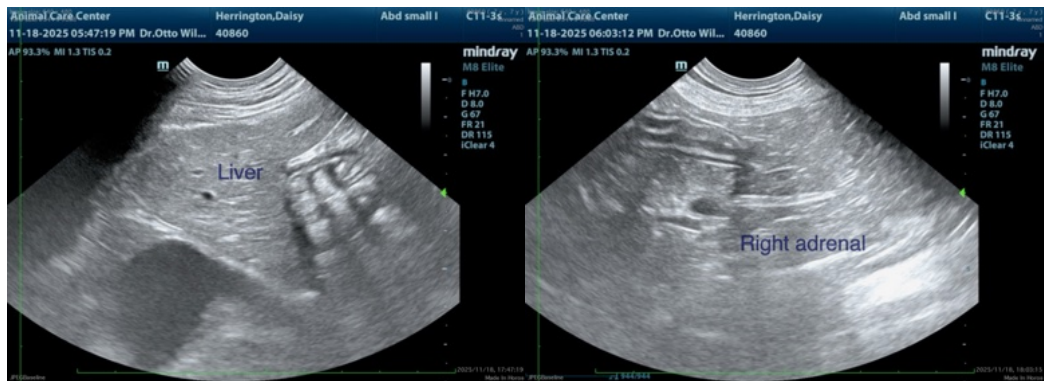
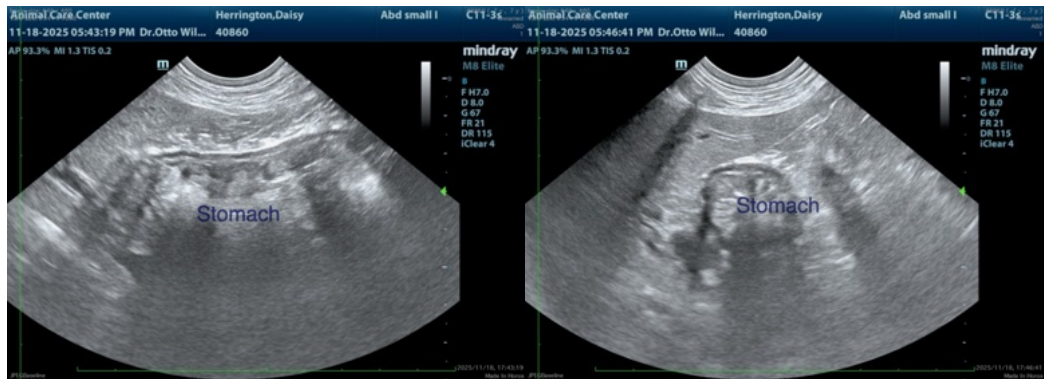
Dr. Williams

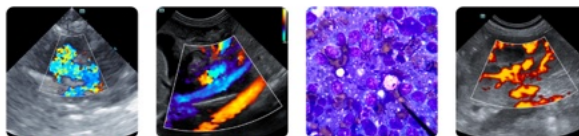
**INVOICE**

68822

**DATE**

11/19/25





## PATIENT

Daisy Herrington

## SPECIES

Canine

## BREED

Boxer Mix

## SEX

Spayed female

## AGE

7 years

## WEIGHT

62 lbs

## INTERPRETED BY

Remo Lobetti, BVSc,  
MMedVet (Med),  
PhD, Dipl. ECVIM

## IMAGING PERFORMED BY

Dr. Otto Williams

## HOSPITAL NAME

Animal Care Center of  
Smyrna

## REFERRING VET

Dr. Williams

## INVOICE

68822

## DATE

11/19/25

The information and recommendations provided are based on the images presented by the referring veterinarian/sonographer. No evaluation can be communicated regarding pathology that was not visible in the image/video clips provided.

Thank you for this referral. If the clinical or image interpretation does not parallel your findings or if I can be of any further assistance please contact me.

Remo Lobetti, BVSc, MMedVet (Med), PhD, Dipl. ECVIM (Internal Medicine)

[info@sonopath.com](mailto:info@sonopath.com)