



PATIENT

Bane Gabusi

SPECIES

Canine

BREED

Australian Shepherd

SEX

Neutered male

AGE

8 years

WEIGHT

69.2 lbs

INTERPRETED BY

Remo Lobetti, BVSc,
MMedVet (Med),
PhD, Dipl. ECVIM

IMAGING PERFORMED BY

Julie Kang

HOSPITAL NAME

Sabino VC

REFERRING VET

Dr. Pavlikowski

INVOICE

68860

DATE

11/19/25

PRESENTING CLINICAL SIGNS

History: 10/25/25: Eval for weight gain (+4 lb/yr, no diet changes), lethargy on walks, and HL weakness (shakiness, difficulty squatting, trouble rising, occasional curb falls). During 1.5-mi walks P stops frequently; excited to start but becomes reluctant once walking. PU/PD (nocturia 3–4×/night), PP, heat-seeking.

10/25/25: Monocytes 909; Chem21—ALT 141, ALKP 1659; USG 1.015; TT4 1.4. 11/4/25 LDDST: resting cortisol 5.5; 4-hr 0.2; 8-hr 0.3.

ULTRASONOGRAPHIC EXAMINATION OF THE ABDOMEN

Urinary System

The urinary bladder is full with a normal thickness and smooth appearance of the wall. Normal anechoic urine with no sediment or uroliths evident.

Normal appearance of the trigone area, proximal urethra, and iliac blood vessels.

Normal appearance and size of the iliac lymph nodes (0.5 x 0.9 cm). Ureters not visualized, which can be considered a normal finding.

Normal renal size (left measured 7.4 cm, right measured 7.4 cm), architecture, echogenic appearance, cortico-medullary differentiation, which maintains a 1:3 cortex to medulla ratio, pelvis, and capsule. No infarcts, mineralization or renoliths evident.

The prostate is small and hypoechogenic.

Adrenal Glands

Normal shape, echogenic appearance, size, position, and appearance of the visible peri-adrenal vasculature. Left adrenal gland measured 2.94 cm in length x 0.56 cm and 0.64 cm in width. The right adrenal gland measured 2.74 cm in length x 0.45 cm and 0.77 cm in width.

Spleen

Normal size and echogenic appearance. Smooth homogenous parenchyma and regular curvilinear capsule. Normal volume of the splenic vasculature without any overt congestion or thrombosis evident. No inflammatory, neoplastic, infarction, or infiltrative changes evident. The spleen measured 2.2 cm in width.

Liver

Normal size with a diffuse increased echogenic appearance, decreased portal markings, and regular curvilinear capsule. No nodules or masses evident. Normal appearance of the hepatic and portal vasculature.



PATIENT

Bane Gabusi

SPECIES

Canine

BREED

Australian Shepherd

SEX

Neutered male

AGE

8 years

WEIGHT

69.2 lbs

INTERPRETED BY

Remo Lobetti, BVSc,
MMedVet (Med),
PhD, Dipl. ECVIM

IMAGING PERFORMED BY

Julie Kang

HOSPITAL NAME

Sabino VC

REFERRING VET

Dr. Pavlikowski

INVOICE

68860

DATE

11/19/25

Gallbladder

The gallbladder is full containing normal anechoic bile. Normal thickness and echogenic appearance of the wall. Normal size and appearance of the cystic and common bile duct.

Gastrointestinal

Normal appearance of the stomach, duodenum, small intestine, ileo-cecal junction, and colon with no loss of layering, 1:3 muscularis to mucosa ratio, normal wall thickness and peristaltic activity, and no distension of the lumen.

Pancreas

The visible sections of the pancreas are of normal size and echogenic appearance with a regular capsule. Normal echogenic appearance of the mesentery and fat surrounding the pancreas.

Free Abdomen

Normal mesenteric lymph nodes.

No ascites evident.

ULTRASONOGRAPHIC FINDINGS

- Hepatopathy.

INTERPRETATION OF THE FINDINGS & FURTHER RECOMMENDATIONS

The likely etiologies for the hepatopathy would be reactive hyperplasia, vacuolar and metabolic with hepatitis and infiltrative neoplasia a highly unlikely differential diagnosis.

A differential diagnosis for the hepatopathy would be intrahepatic fat accumulation.

On this ultrasound there is no obvious etiology for the presenting clinical signs.

Further assessment of the hepatopathy that can be considered would be FNA cytology. However, the a tru cut or wedge biopsy may be required for a final etiological diagnosis.

With the presenting clinical signs spinal and orthopedic conditions should be considered.

Specific therapy would be dependent on an etiological diagnosis.



PATIENT

Bane Gabusi

SPECIES

Canine

BREED

Australian Shepherd

SEX

Neutered male

AGE

8 years

WEIGHT

69.2 lbs

INTERPRETED BY

Remo Lobetti, BVSc,
MMedVet (Med),
PhD, Dipl. ECVIM

IMAGING PERFORMED BY

Julie Kang

HOSPITAL NAME

Sabino VC

REFERRING VET

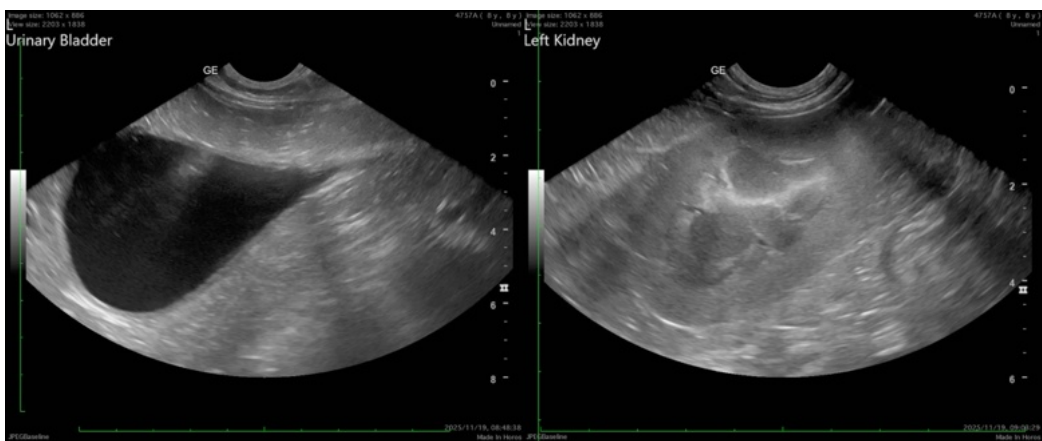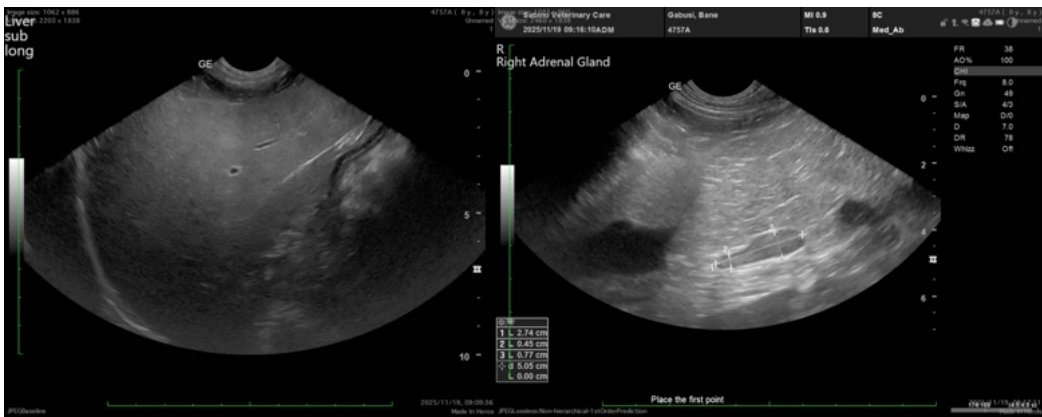
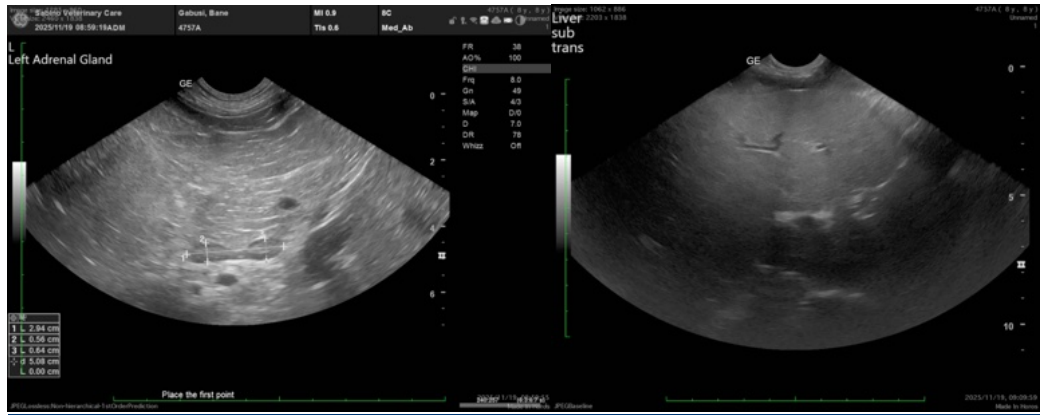
Dr. Pavlikowski

INVOICE

68860

DATE

11/19/25





PATIENT

Bane Gabusi

SPECIES

Canine

BREED

Australian Shepherd

SEX

Neutered male

AGE

8 years

WEIGHT

69.2 lbs

INTERPRETED BY

Remo Lobetti, BVSc,
MMedVet (Med),
PhD, Dipl. ECVIM

IMAGING PERFORMED BY

Julie Kang

HOSPITAL NAME

Sabino VC

REFERRING VET

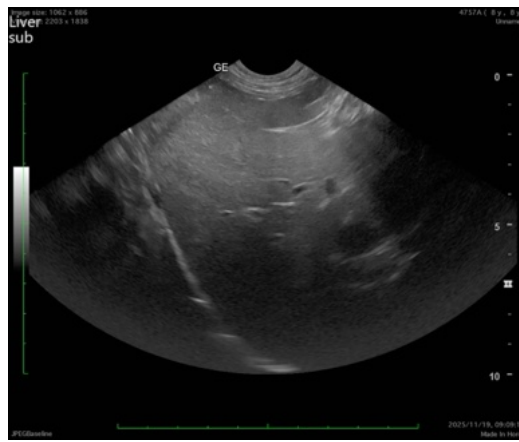
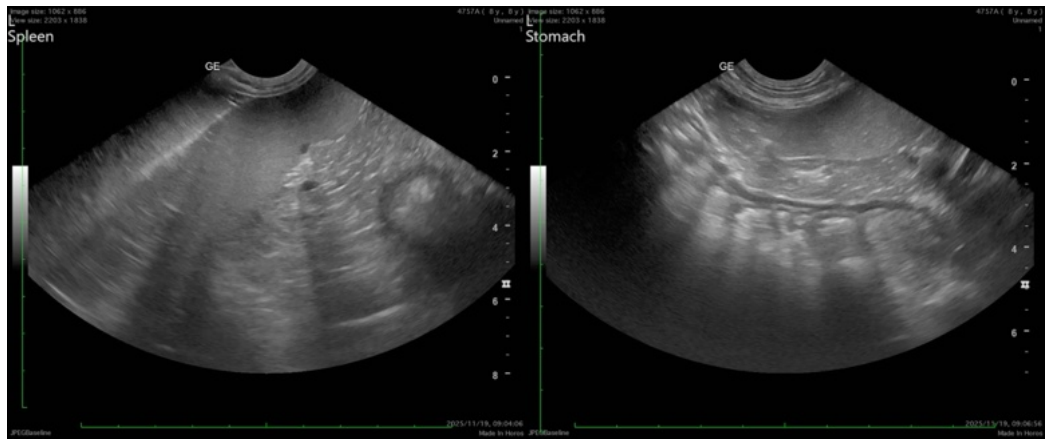
Dr. Pavlikowski

INVOICE

68860

DATE

11/19/25



The information and recommendations provided are based on the images presented by the referring veterinarian/sonographer. No evaluation can be communicated regarding pathology that was not visible in the image/video clips provided.

Thank you for this referral. If the clinical or image interpretation does not parallel your findings or if I can be of any further assistance please contact me.

Remo Lobetti, BVSc, MMedVet (Med), PhD, Dipl. ECVIM (Internal Medicine)

info@sonopath.com