



## PATIENT

Sammy Wieboldt

## SPECIES

Canine

## BREED

Whippet Mix

## SEX

Neutered male

## AGE

12 years

## WEIGHT

51.7 lbs

## INTERPRETED BY

Remo Lobetti, BVSc,  
MMedVet (Med),  
PhD, Dipl. ECVIM

## IMAGING PERFORMED BY

Jessy Butcher

## HOSPITAL NAME

Healing Paws

## REFERRING VET

Dr. Klickman

## INVOICE

68774

## DATE

11/18/25

## PRESENTING CLINICAL SIGNS

History: Original owner moved out of country, Sammy has been rehomed to current owner. Decreased appetite, PUPD, anxiety. Past history includes "sensitive stomach" and recurrent skin issues of unknown origin. Appetite worse on prozac, has been eating better since stopped and added famotidine, anxiety improving on calming supplements.

Abnormal PE/Chem/CBC/UA Results: Full bloodwork done for inappetence found mildly increased ALT, AlkP, USG 1.011, otherwise NSF.

## ULTRASONOGRAPHIC EXAMINATION OF THE ABDOMEN

### *Urinary System*

The urinary bladder is full with a normal thickness and smooth appearance of the wall. Normal anechoic urine with no sediment or uroliths evident.

Normal appearance of the trigone area, proximal urethra, and iliac blood vessels.

Normal appearance and size of the iliac lymph nodes. Ureters not visualized, which can be considered a normal finding.

Normal renal size (left measured 5.8 cm, right measured 6.2 cm), architecture, echogenic appearance, cortico-medullary differentiation, which maintains a 1:3 cortex to medulla ratio, pelvis, and capsule. No infarcts, mineralization or renoliths evident.

The prostate is small and hypoechogenic.

### *Adrenal Glands*

The left adrenal gland is normal in shape, echogenic appearance, size, position, and appearance of the visible peri-adrenal vasculature. Left adrenal gland measured 0.49 cm and 0.55 cm in width. The right adrenal gland was not clearly visualized, but appears to be of normal shape, echogenic appearance and size.

### *Spleen*

Normal size and echogenic appearance. Smooth homogenous parenchyma and regular curvilinear capsule. Normal volume of the splenic vasculature without any overt congestion or thrombosis evident. No inflammatory, neoplastic, infarction, or infiltrative changes evident. The spleen measured 1.8 cm in width.

### *Liver*

Normal size, echogenic appearance, portal markings, and regular curvilinear capsule. No nodules or masses evident. Normal appearance of the hepatic and portal vasculature.



## PATIENT

Sammy Wieboldt

## SPECIES

Canine

## BREED

Whippet Mix

## SEX

Neutered male

## AGE

12 years

## WEIGHT

51.7 lbs

## INTERPRETED BY

Remo Lobetti, BVSc,  
MMedVet (Med),  
PhD, Dipl. ECVIM

## IMAGING PERFORMED BY

Jessy Butcher

## HOSPITAL NAME

Healing Paws

## REFERRING VET

Dr. Klickman

## INVOICE

68774

## DATE

11/18/25

## Gallbladder

The gallbladder is full containing normal anechoic bile. Normal thickness and echogenic appearance of the wall. Normal size and appearance of the cystic and common bile duct.

## Gastrointestinal

Normal appearance of the stomach, duodenum, small intestine, ileo-cecal junction, and colon with no loss of layering, 1:3 muscularis to mucosa ratio, normal wall thickness and peristaltic activity, and no distension of the lumen.

## Pancreas

The visible sections of the pancreas are of normal size and echogenic appearance with a regular capsule. Normal echogenic appearance of the mesentery and fat surrounding the pancreas.

## Free Abdomen

Normal mesenteric lymph nodes.

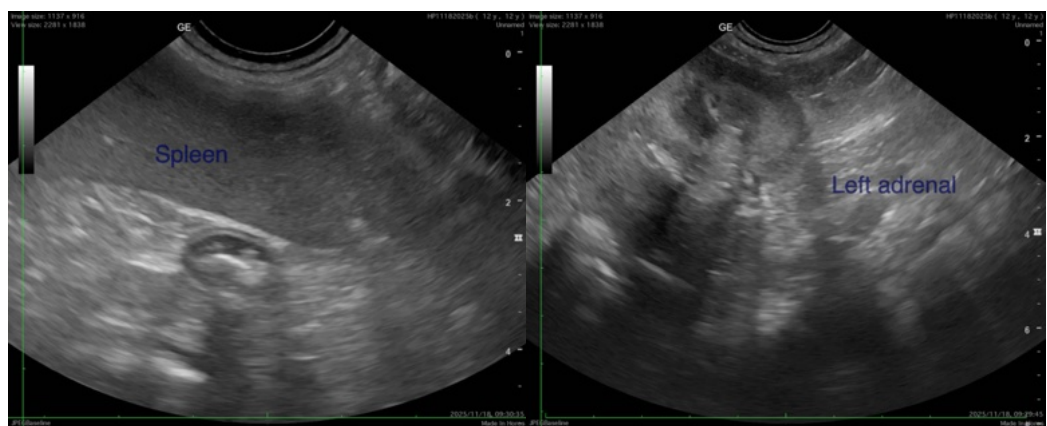
No ascites evident.

## ULTRASONOGRAPHIC FINDINGS

- Normal ultrasound examination of the abdomen.

## INTERPRETATION OF THE FINDINGS & FURTHER RECOMMENDATIONS

No specific therapy is recommended at this time.





## PATIENT

Sammy Wieboldt

## SPECIES

Canine

## BREED

Whippet Mix

## SEX

Neutered male

## AGE

12 years

## WEIGHT

51.7 lbs

## INTERPRETED BY

Remo Lobetti, BVSc,  
MMedVet (Med),  
PhD, Dipl. ECVIM

## IMAGING PERFORMED BY

Jessy Butcher

## HOSPITAL NAME

Healing Paws

## REFERRING VET

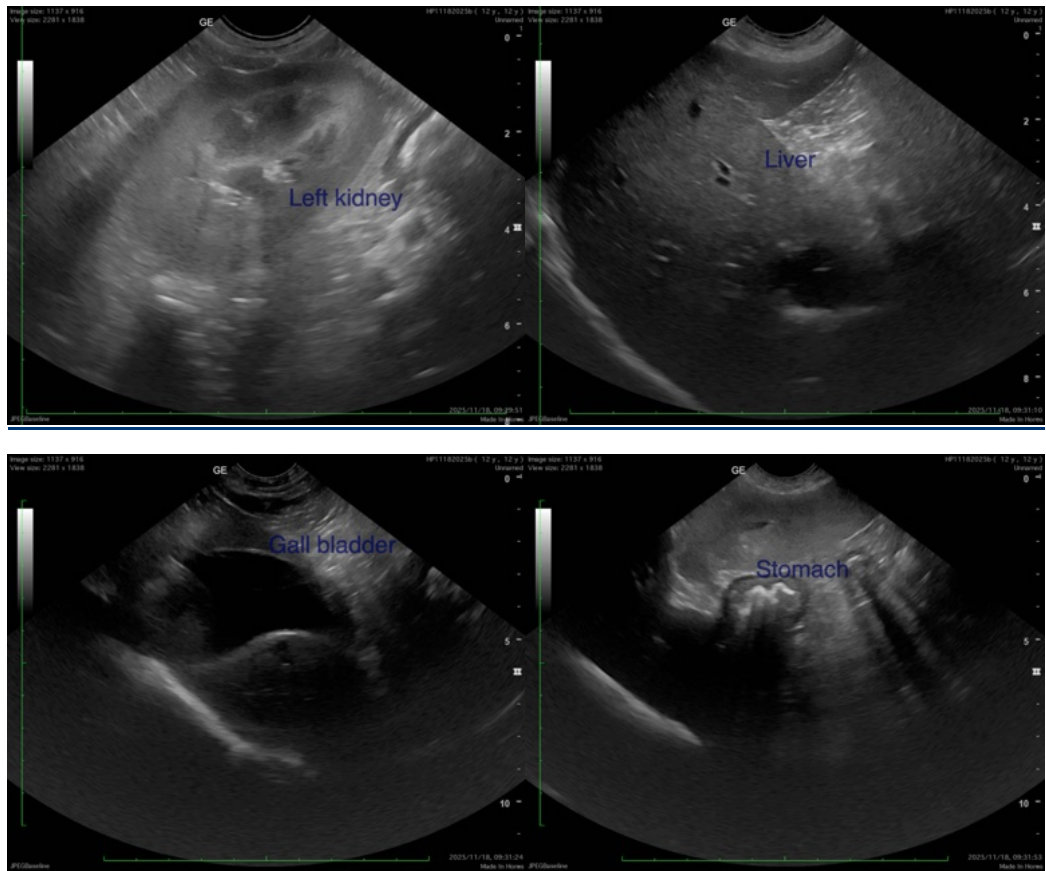
Dr. Klickman

## INVOICE

68774

## DATE

11/18/25



The information and recommendations provided are based on the images presented by the referring veterinarian/sonographer. No evaluation can be communicated regarding pathology that was not visible in the image/video clips provided.

Thank you for this referral. If the clinical or image interpretation does not parallel your findings or if I can be of any further assistance please contact me.

Remo Lobetti, BVSc, MMedVet (Med), PhD, Dipl. ECVIM (Internal Medicine)

[info@sonopath.com](mailto:info@sonopath.com)