



PATIENT

Cubby Roller

SPECIES

Canine

BREED

Yorkshire Terrier Mix

SEX

Neutered male

AGE

13 years

WEIGHT

9.3 lbs

INTERPRETED BY

Remo Lobetti, BVSc,
MMedVet (Med),
PhD, Dipl. ECVIM

IMAGING PERFORMED BY

Dr. Stranzl

HOSPITAL NAME

Dakota VC

REFERRING VET

Dr. Stranzl

INVOICE

68783

DATE

11/18/25

PRESENTING CLINICAL SIGNS

History: Patient presented for wellness, had excessive bleeding from injection site, petechia on belly
Hx Cushing's disease and diabetes
CBC/chem - PLTs extremely low 3, Tbili ele 1.9; otherwise NSF -> Tbili r/o evans starting but currently
ITP PT/PTT - WNL U/A free catch - pending

ULTRASONOGRAPHIC EXAMINATION OF THE ABDOMEN

Urinary System

The urinary bladder is full with a normal thickness and smooth appearance of the wall. Normal anechoic urine with no sediment or uroliths evident.

Normal appearance of the trigone area, proximal urethra, and iliac blood vessels.

Normal appearance and size of the iliac lymph nodes. Ureters not visualized, which can be considered a normal finding.

Normal renal size (left measured 3.6 cm, right measured 3.8 cm), architecture, echogenic appearance, cortico-medullary differentiation, which maintains a 1:3 cortex to medulla ratio, pelvis, and capsule. No infarcts, mineralization or renoliths evident.

The prostate is small and hypoechogenic.

Adrenal Glands

The left adrenal gland was not clearly visualized, but appears to be of normal shape, echogenic appearance. The right adrenal gland was not clearly visualized.

Spleen

Normal size and echogenic appearance. Smooth homogenous parenchyma and regular curvilinear capsule. Normal volume of the splenic vasculature without any overt congestion or thrombosis evident. No inflammatory, neoplastic, infarction, or infiltrative changes evident. The spleen measured 1.5 cm in width.

Liver

Normal size, echogenic appearance, portal markings, and regular curvilinear capsule. No nodules or masses evident. Normal appearance of the hepatic and portal vasculature.

Gallbladder

The gallbladder is full containing normal anechoic bile. Normal thickness and echogenic appearance of the wall. Normal size and appearance of the cystic and common bile duct.



PATIENT

Cubby Roller

SPECIES

Canine

BREED

Yorkshire Terrier Mix

SEX

Neutered male

AGE

13 years

WEIGHT

9.3 lbs

INTERPRETED BY

Remo Lobetti, BVSc,
MMedVet (Med),
PhD, Dipl. ECVIM

IMAGING PERFORMED BY

Dr. Stranzl

HOSPITAL NAME

Dakota VC

REFERRING VET

Dr. Stranzl

INVOICE

68783

DATE

11/18/25

Gastrointestinal

Normal appearance of the stomach, duodenum, small intestine, ileo-cecal junction, and colon with no loss of layering, 1:3 muscularis to mucosa ratio, normal wall thickness and peristaltic activity, and no distension of the lumen. A moderate amount of ingesta is present within the stomach. This is compatible with a recent meal. Fecal material is present in the colon.

Pancreas

The visible sections of the pancreas are of normal size and echogenic appearance with a regular capsule. Normal echogenic appearance of the mesentery and fat surrounding the pancreas.

Free Abdomen

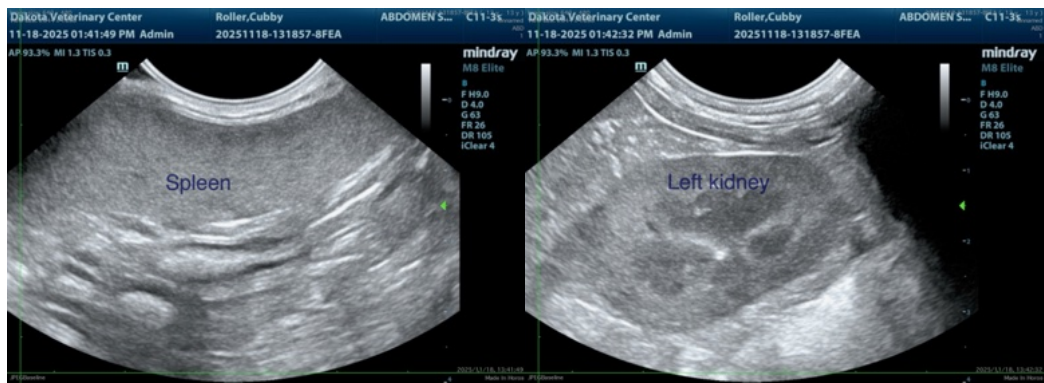
Normal mesenteric lymph nodes.
No ascites evident.

ULTRASONOGRAPHIC FINDINGS

- Normal ultrasound examination of the abdomen.

INTERPRETATION OF THE FINDINGS & FURTHER RECOMMENDATIONS

On this ultrasound there is no obvious trigger for the immune mediated thrombocytopenia.





PATIENT

Cubby Roller

SPECIES

Canine

BREED

Yorkshire Terrier Mix

SEX

Neutered male

AGE

13 years

WEIGHT

9.3 lbs

INTERPRETED BY

Remo Lobetti, BVSc,
MMedVet (Med),
PhD, Dipl. ECVIM

IMAGING PERFORMED BY

Dr. Stranzl

HOSPITAL NAME

Dakota VC

REFERRING VET

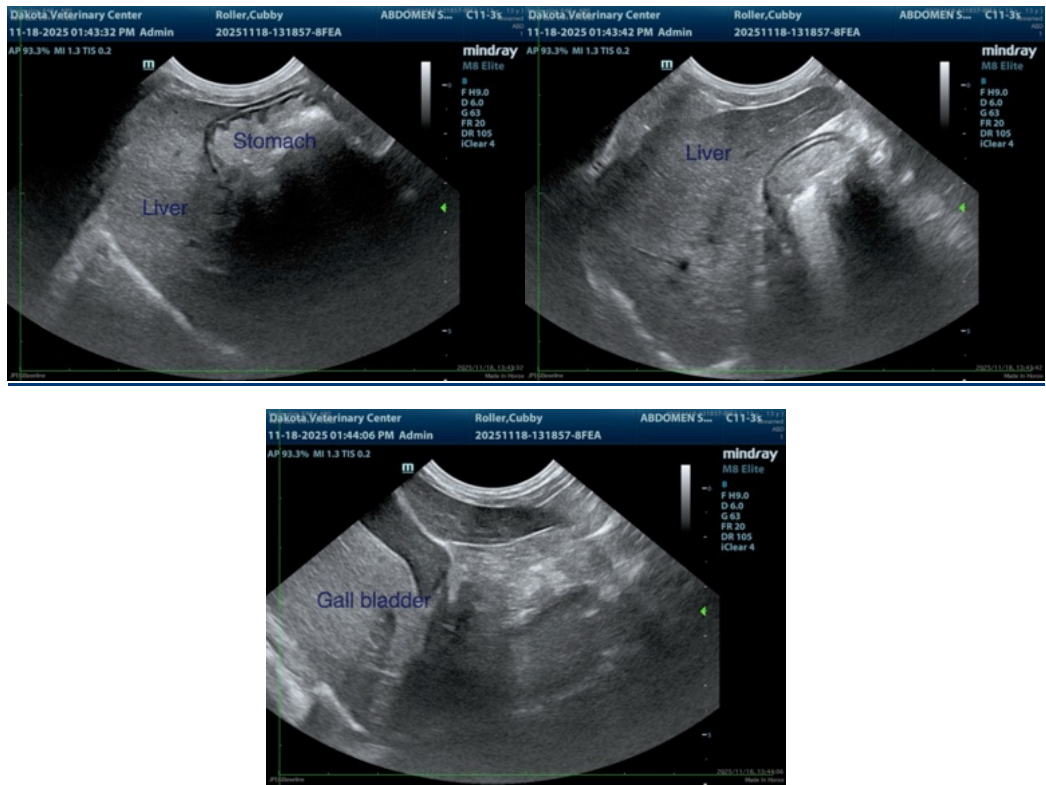
Dr. Stranzl

INVOICE

68783

DATE

11/18/25



The information and recommendations provided are based on the images presented by the referring veterinarian/sonographer. No evaluation can be communicated regarding pathology that was not visible in the image/video clips provided.

Thank you for this referral. If the clinical or image interpretation does not parallel your findings or if I can be of any further assistance please contact me.

Remo Lobetti, BVSc, MMedVet (Med), PhD, Dipl. ECVIM (Internal Medicine)

info@sonopath.com