



PATIENT

Bubbles Hunt

SPECIES

Canine

BREED

Pug

SEX

Spayed female

AGE

8 years

WEIGHT

10 lbs

INTERPRETED BY

Remo Lobetti, BVSc,
MMedVet (Med),
PhD, Dipl. ECVIM

IMAGING PERFORMED BY

Heather

HOSPITAL NAME

Animal Care Center of
Flanders

REFERRING VET

Dr. Villari

INVOICE

68789

DATE

11/18/25

PRESENTING CLINICAL SIGNS

History: inappetence, diarrhea with mucus, eclipse 10/29 - colopathy - no lymphoma metronidazole, b-12 today, cerenia today
CBC/Chem WNL, except low alb - 1.9

ULTRASONOGRAPHIC EXAMINATION OF THE ABDOMEN

Urinary System

The urinary bladder is full with a normal thickness and smooth appearance of the wall. A scant amount of floating, hyperechogenic sediment.

Normal appearance of the trigone area, proximal urethra, and iliac blood vessels.

Normal appearance and size of the iliac lymph nodes. Ureters not visualized, which can be considered a normal finding.

Normal renal size (left measured 3.2 cm, right measured 3.3 cm), architecture, echogenic appearance, cortico-medullary differentiation, which maintains a 1:3 cortex to medulla ratio, pelvis, and capsule. No infarcts, mineralization or renoliths evident. Normal color flow pattern is evident in both kidneys.

Adrenal Glands

The adrenal glands are not clearly visualized, but appear to be of normal shape, echogenic appearance and size.

Spleen

Normal size and echogenic appearance. Smooth homogenous parenchyma and regular curvilinear capsule. Normal volume of the splenic vasculature without any overt congestion or thrombosis evident. No inflammatory, neoplastic, infarction, or infiltrative changes evident. The spleen measured 0.9 cm in width.

Liver

Normal size, echogenic appearance, portal markings, and regular curvilinear capsule. No nodules or masses evident. Normal appearance of the hepatic and portal vasculature.

Gallbladder

The gallbladder is full containing normal anechoic bile. Normal thickness and echogenic appearance of the wall. Normal size and appearance of the cystic and common bile duct.



PATIENT

Bubbles Hunt

SPECIES

Canine

BREED

Pug

SEX

Spayed female

AGE

8 years

WEIGHT

10 lbs

INTERPRETED BY

Remo Lobetti, BVSc,
MMedVet (Med),
PhD, Dipl. ECVIM

IMAGING PERFORMED BY

Heather

HOSPITAL NAME

Animal Care Center of
Flanders

REFERRING VET

Dr. Villari

INVOICE

68789

DATE

11/18/25

Gastrointestinal

Normal appearance of the stomach, duodenum, small intestine, and ileo-cecal junction with no loss of layering, 1:3 muscularis to mucosa ratio, normal wall thickness and peristaltic activity, and no distension of the lumen. Mild thickening of the colon measuring up to 0.33 cm with no loss of layering maintaining a 1:3 muscularis to mucosa ratio and containing a moderate amount of liquid fecal material. The small intestine measures up to 0.4 cm.

Pancreas

The visible sections of the pancreas are of normal size and echogenic appearance with a regular capsule. Normal echogenic appearance of the mesentery and fat surrounding the pancreas.

Free Abdomen

Normal mesenteric lymph nodes.

No ascites evident.

ULTRASONOGRAPHIC FINDINGS

- Colonic thickening.

INTERPRETATION OF THE FINDINGS & FURTHER RECOMMENDATIONS

The thickening of the colon would be in line with the diagnosis of the colonopathy as per the patient's history. Possible etiologies are inflammatory bowel disease, parasitic disease, granulomatous colitis and idiopathic colitis. As colonic pathology should not result in hypoalbuminemia, an underlying enteropathy of the small intestine needs to be considered with possible etiologies being parasitic enteritis, dietary hypersensitivity and inflammatory bowel disease.

Further assessment that can be considered would be fecal analysis (if not already done) and endoscopy of the upper GI tract with biopsies.

Specific therapy would be dependent on an etiological diagnosis.

Additional symptomatic management that can be considered would be feeding a novel protein/hypoallergenic diet and possibly a course of Prednisolone.



PATIENT

Bubbles Hunt

SPECIES

Canine

BREED

Pug

SEX

Spayed female

AGE

8 years

WEIGHT

10 lbs

INTERPRETED BY

Remo Lobetti, BVSc,
MMedVet (Med),
PhD, Dipl. ECVIM

IMAGING PERFORMED BY

Heather

HOSPITAL NAME

Animal Care Center of
Flanders

REFERRING VET

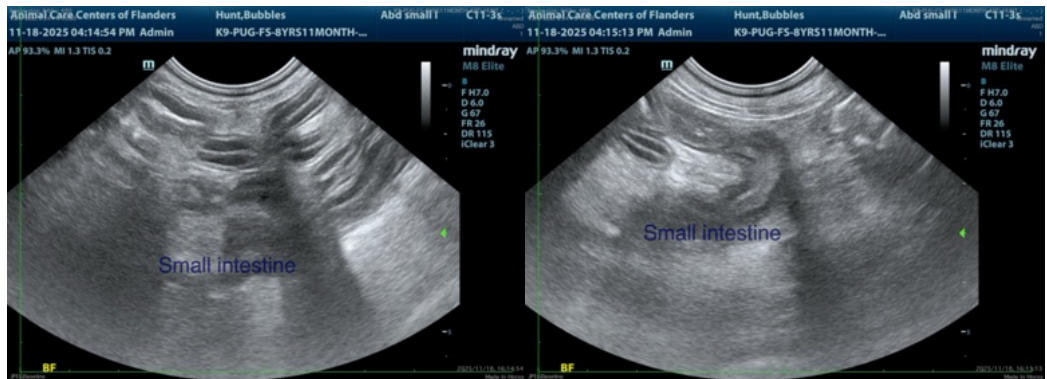
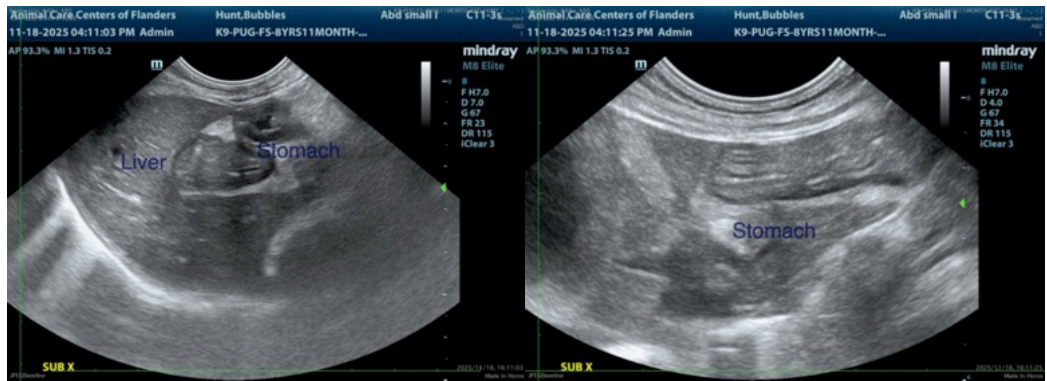
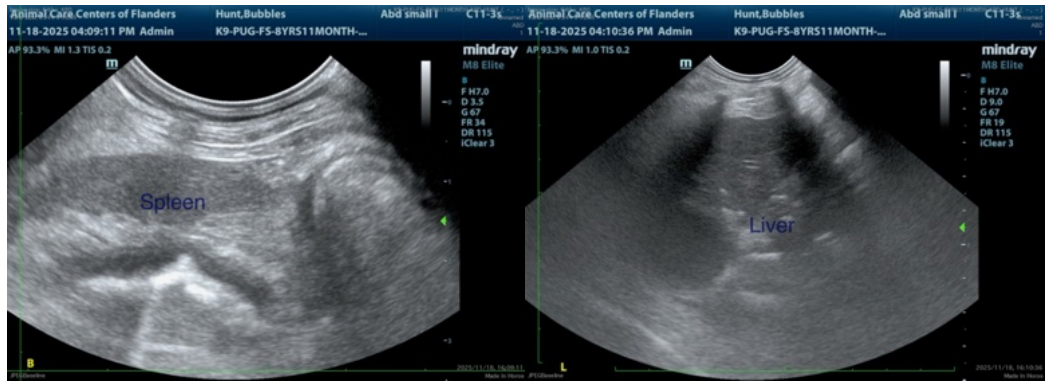
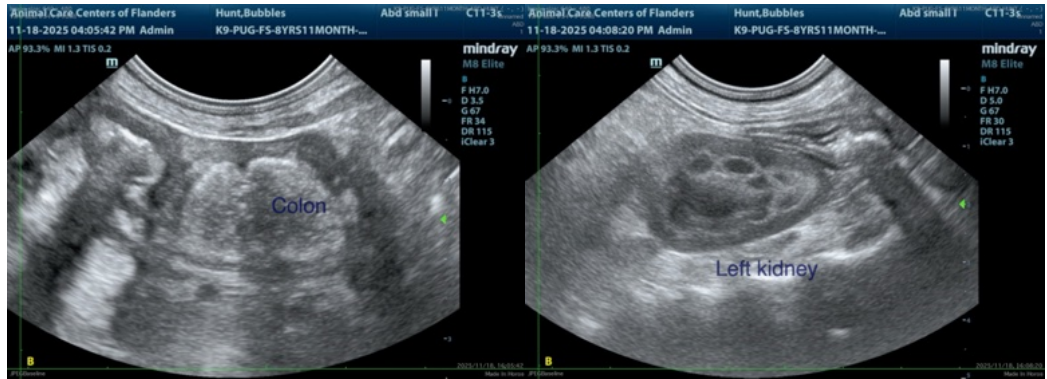
Dr. Villari

INVOICE

68789

DATE

11/18/25





PATIENT

Bubbles Hunt

SPECIES

Canine

BREED

Pug

SEX

Spayed female

AGE

8 years

WEIGHT

10 lbs

INTERPRETED BY

Remo Lobetti, BVSc,
MMedVet (Med),
PhD, Dipl. ECVIM

IMAGING PERFORMED BY

Heather

HOSPITAL NAME

Animal Care Center of
Flanders

REFERRING VET

Dr. Villari

INVOICE

68789

DATE

11/18/25

The information and recommendations provided are based on the images presented by the referring veterinarian/sonographer. No evaluation can be communicated regarding pathology that was not visible in the image/video clips provided.

Thank you for this referral. If the clinical or image interpretation does not parallel your findings or if I can be of any further assistance please contact me.

Remo Lobetti, BVSc, MMedVet (Med), PhD, Dipl. ECVIM (Internal Medicine)

info@sonopath.com