



PATIENT

Bella Lopez

SPECIES

Canine

BREED

Mastiff

SEX

Spayed female

AGE

7 years

WEIGHT

105.9 lbs

INTERPRETED BY

Remo Lobetti, BVSc,
MMedVet (Med),
PhD, Dipl. ECVIM

IMAGING PERFORMED BY

Dr. Brittani Nicolaci/
Dr. Logas

HOSPITAL NAME

Bradenton VH

REFERRING VET

Dr. Nicolai

INVOICE

68743

DATE

11/17/25

PRESENTING CLINICAL SIGNS

History: difficulty passing stool for several weeks and there is now blood in the stool. x-rays show soft stool burden in distal colon, ow relatively unremarkable. BW significant for elevated globulins, ow unremarkable (pt does have an ear infection and allergic skin disease). GI parasite PCR is negative. pt has a significant proctitis (ulcerated tissue, friable tissue, pain with palpation) but ow unremarkable rectal exam.

ULTRASONOGRAPHIC EXAMINATION OF THE ABDOMEN

Urinary System

The urinary bladder is small with a normal thickness and smooth appearance of the wall. Normal anechoic urine with no sediment or uroliths evident.

Normal appearance of the trigone area, proximal urethra, and iliac blood vessels.

Normal appearance and size of the iliac lymph nodes. Ureters not visualized, which can be considered a normal finding.

Normal renal size (left measured 7.6 cm, right measured 7.8 cm), architecture, echogenic appearance, cortico-medullary differentiation, which maintains a 1:3 cortex to medulla ratio, pelvis, and capsule. No infarcts, mineralization or renoliths evident.

Adrenal Glands

The adrenal glands are not visualized.

Spleen

Normal size and echogenic appearance. Smooth homogenous parenchyma and regular curvilinear capsule. Normal volume of the splenic vasculature without any overt congestion or thrombosis evident. No inflammatory, neoplastic, infarction, or infiltrative changes evident. The spleen measured 3.0 cm in width.

Liver

Normal size, echogenic appearance, portal markings, and regular curvilinear capsule. No nodules or masses evident. Normal appearance of the hepatic and portal vasculature.

Gallbladder

The gallbladder is small containing normal anechoic bile. Normal thickness and echogenic appearance of the wall. Normal size and appearance of the cystic and common bile duct.



PATIENT

Bella Lopez

SPECIES

Canine

BREED

Mastiff

SEX

Spayed female

AGE

7 years

WEIGHT

105.9 lbs

INTERPRETED BY

Remo Lobetti, BVSc,
MMedVet (Med),
PhD, Dipl. ECVIM

IMAGING PERFORMED BY

Dr. Brittani Nicolaci/
Dr. Logas

HOSPITAL NAME

Bradenton VH

REFERRING VET

Dr. Nicolai

INVOICE

68743

DATE

11/17/25

Gastrointestinal

Normal appearance of the stomach, duodenum, small intestine, ileo-cecal junction, and colon with no loss of layering, 1:3 muscularis to mucosa ratio, normal wall thickness and peristaltic activity, and no distension of the lumen. Fecal material is present in the colon.

Pancreas

The visible sections of the pancreas are of normal size and echogenic appearance with a regular capsule. Normal echogenic appearance of the mesentery and fat surrounding the pancreas.

Free Abdomen

Normal mesenteric lymph nodes.

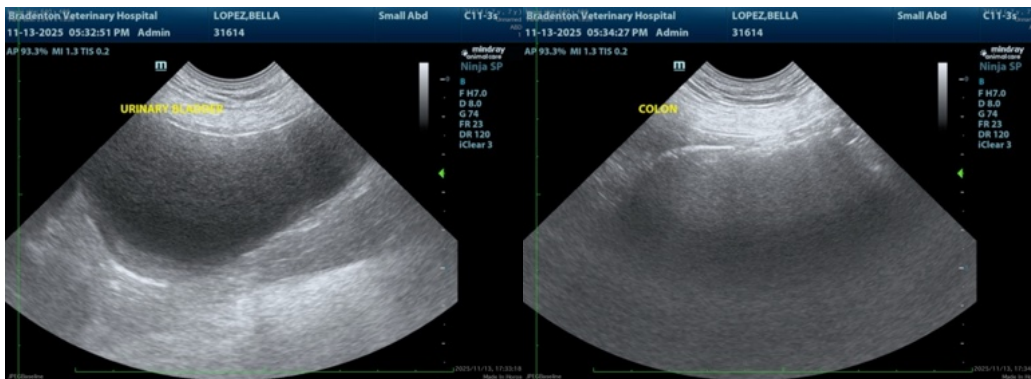
No ascites evident.

ULTRASONOGRAPHIC FINDINGS

- Normal ultrasound examination of the abdomen.

INTERPRETATION OF THE FINDINGS & FURTHER RECOMMENDATIONS

On this ultrasound there is no obvious extension of the proctitis into the distal colon.





PATIENT

Bella Lopez

SPECIES

Canine

BREED

Mastiff

SEX

Spayed female

AGE

7 years

WEIGHT

105.9 lbs

INTERPRETED BY

Remo Lobetti, BVSc,
MMedVet (Med),
PhD, Dipl. ECVIM

IMAGING PERFORMED BY

Dr. Brittani Nicolaci/
Dr. Logas

HOSPITAL NAME

Bradenton VH

REFERRING VET

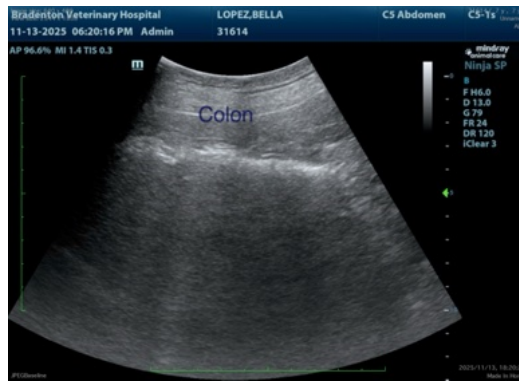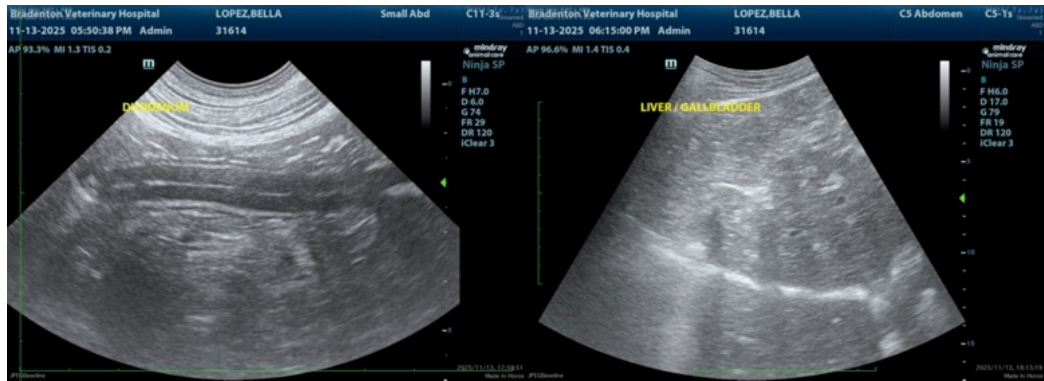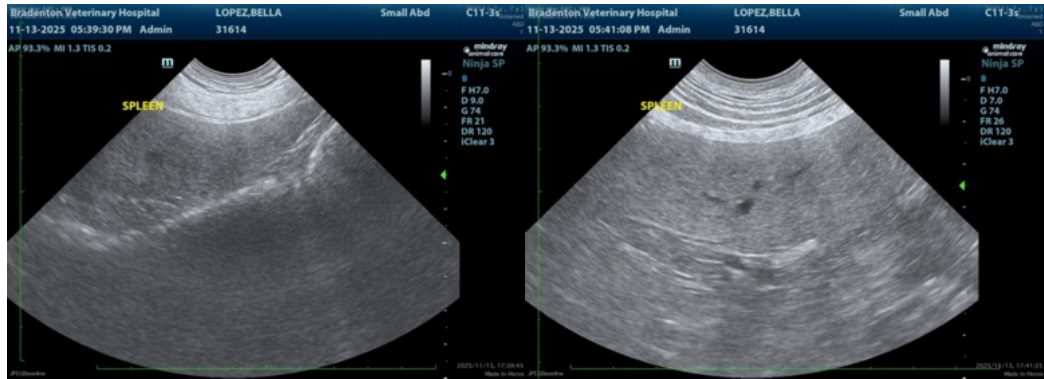
Dr. Nicolai

INVOICE

68743

DATE

11/17/25



The information and recommendations provided are based on the images presented by the referring veterinarian/sonographer. No evaluation can be communicated regarding pathology that was not visible in the image/video clips provided.

Thank you for this referral. If the clinical or image interpretation does not parallel your findings or if I can be of any further assistance please contact me.

Remo Lobetti, BVSc, MMedVet (Med), PhD, Dipl. ECVIM (Internal Medicine)

info@sonopath.com