



## PATIENT

Fluffy Kauffelt

## SPECIES

Feline

## BREED

Sphynx

## SEX

Spayed female

## AGE

5 years

## WEIGHT

5.6 lbs

## INTERPRETED BY

Remo Lobetti, BVSc,  
MMedVet (Med),  
PhD, Dipl. ECVIM

## IMAGING PERFORMED BY

Dr. Isaac

## HOSPITAL NAME

Valley West & Elk  
Valley VH

## REFERRING VET

Dr. Isaac

## INVOICE

68605

## DATE

11/12/25

## PRESENTING CLINICAL SIGNS

History: History of weight loss. Occasional vomiting. Normal appetite. Eating OTC Royal Canin wet and dry food. Adopted in California, unsure of entire history prior to adoption.  
Abnormal PE/Chem/CBC/UA Results: Slightly fractious, difficult to do a full exam without sedation. Leukocytosis (22,000) characterized mostly by neutrophilia and monocytosis. Slightly decreased Cr (0.5) Normal T4. USPG 1.021 with no proteinuria.

## ULTRASONOGRAPHIC EXAMINATION OF THE ABDOMEN

### *Urinary System*

The urinary bladder is small with a normal thickness and smooth appearance of the wall. A moderate amount of floating, hyperechogenic sediment.

Normal appearance of the trigone area, proximal urethra, and iliac blood vessels.

Normal appearance and size of the iliac lymph nodes. Ureters not visualized, which can be considered a normal finding.

Normal renal size (left measured 4.1 cm, right measured 3.8 cm), architecture, echogenic appearance, cortico-medullary differentiation, which maintains a 1:3 cortex to medulla ratio, pelvis, and capsule. No infarcts, mineralization or renoliths evident.

### *Adrenal Glands*

Normal shape, echogenic appearance, size, position, and appearance of the visible peri-adrenal vasculature. Left adrenal gland measured 0.8 cm in length x 0.38 cm in width. The right adrenal gland measured 0.35 cm in width.

### *Spleen*

Normal size and echogenic appearance. Smooth homogenous parenchyma and regular curvilinear capsule. Normal volume of the splenic vasculature without any overt congestion or thrombosis evident. No inflammatory, neoplastic, infarction, or infiltrative changes evident. The spleen measured 0.6 cm in width.

### *Liver*

Normal size, echogenic appearance, portal markings, and regular curvilinear capsule. No nodules or masses evident. Normal appearance of the hepatic and portal vasculature.

### *Gallbladder*

The gallbladder is full containing normal anechoic bile. Normal thickness and echogenic appearance of the wall. Normal size and appearance of the cystic and common bile duct.



## PATIENT

Fluffy Kauffelt

## SPECIES

Feline

## BREED

Sphynx

## SEX

Spayed female

## AGE

5 years

## WEIGHT

5.6 lbs

## INTERPRETED BY

Remo Lobetti, BVSc,  
MMedVet (Med),  
PhD, Dipl. ECVIM

## IMAGING PERFORMED BY

Dr. Isaac

## HOSPITAL NAME

Valley West & Elk  
Valley VH

## REFERRING VET

Dr. Isaac

## INVOICE

68605

## DATE

11/12/25

## *Gastrointestinal*

Normal appearance of the stomach, duodenum, ileo-cecal junction, and colon with no loss of layering, 1:3 muscularis to mucosa ratio, normal wall thickness and peristaltic activity, and no distension of the lumen. Segmental thickening of the small intestine (up to 0.35 cm) with no loss of layering, but with segmental increase in the muscularis to mucosa ratio, normal peristaltic activity and no distension of the lumen.

## *Pancreas*

The visible sections of the pancreas are of normal size and echogenic appearance with a regular capsule. Normal echogenic appearance of the mesentery and fat surrounding the pancreas.

## *Free Abdomen*

Prominent mesenteric lymph nodes measuring up to 0.5 x 1.0 cm in size with a slightly rounded shape, but maintained a normal echogenic appearance. There was hyperechogenic appearance of the mesentery surrounding the lymph nodes.

No ascites evident.

## ULTRASONOGRAPHIC FINDINGS

- Enteropathy.
- Mesenteric lymphadenomegaly.
- Urinary bladder sediment.

## INTERPRETATION OF THE FINDINGS & FURTHER RECOMMENDATIONS

Etiologies for the enteropathy would be parasitic enteritis, dietary hypersensitivity and inflammatory bowel disease with emerging lymphoma a less likely differential diagnosis.

The most likely etiology for the mesenteric lymphadenomegaly would be reactive hyperplasia with lymphadenitis and infiltrative neoplasia a less likely differential diagnosis.

The most likely etiology for the urinary bladder sediment would be incidental debris.

Further assessment would be fecal analysis, cobalamin and folate assay and endoscopy of the upper GI tract with biopsies.

Specific therapy would be dependent on an etiological diagnosis. Symptomatic management that can be considered would be feeding small frequent meals of a novel protein/hypoallergenic diet, course of Fenbendazole, cobalamin supplementation and if there is still not a satisfactory improvement then a course of Prednisolone would then be indicated.



**PATIENT**

Fluffy Kauffelt

**SPECIES**

Feline

**BREED**

Sphynx

**SEX**

Spayed female

**AGE**

5 years

**WEIGHT**

5.6 lbs

**INTERPRETED BY**

Remo Lobetti, BVSc,  
MMedVet (Med),  
PhD, Dipl. ECVIM

**IMAGING PERFORMED BY**

Dr. Isaac

**HOSPITAL NAME**

Valley West & Elk  
Valley VH

**REFERRING VET**

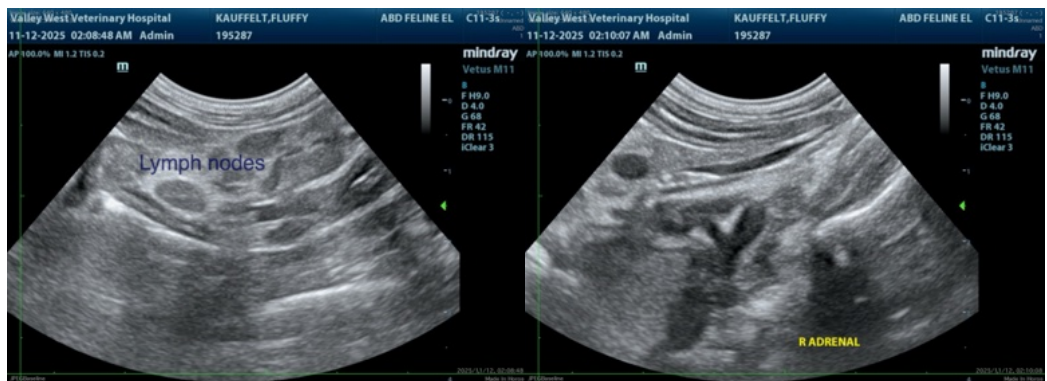
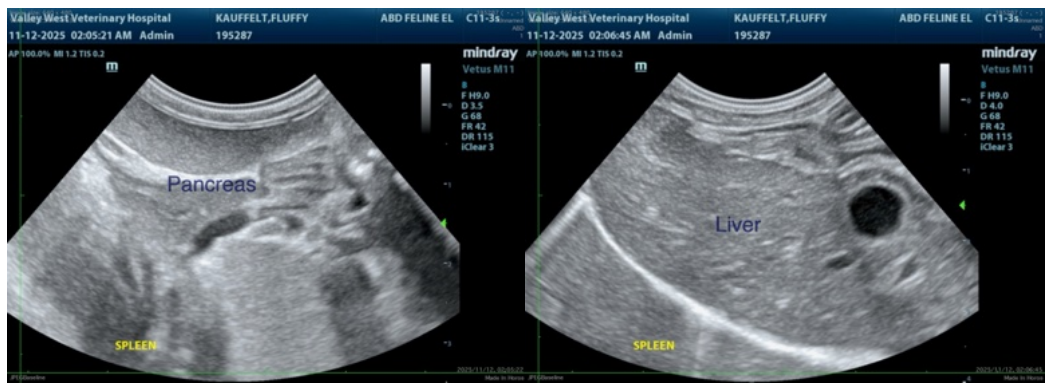
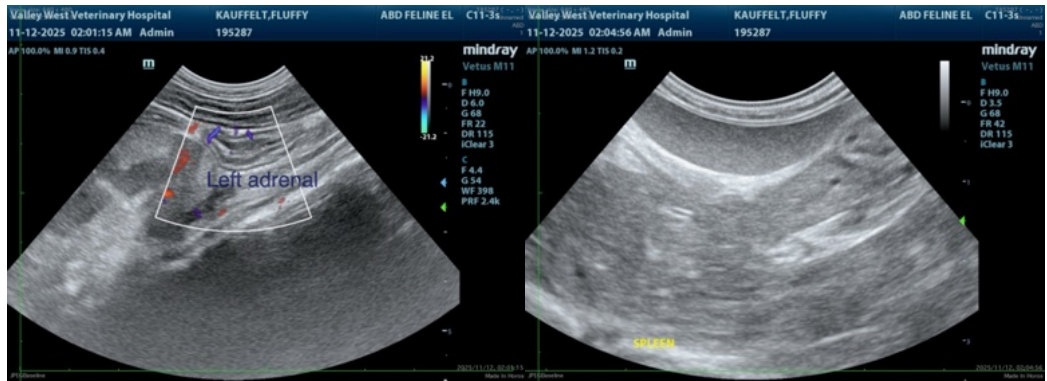
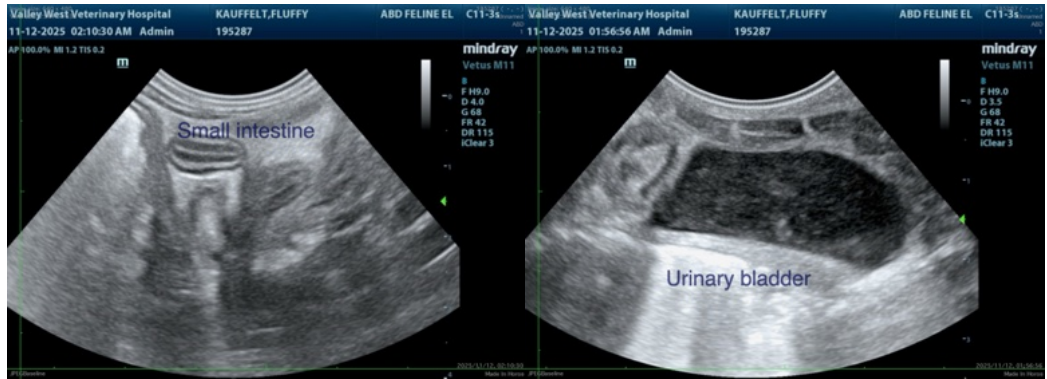
Dr. Isaac

**INVOICE**

68605

**DATE**

11/12/25





## PATIENT

Fluffy Kauffelt

## SPECIES

Feline

## BREED

Sphynx

## SEX

Spayed female

## AGE

5 years

## WEIGHT

5.6 lbs

## INTERPRETED BY

Remo Lobetti, BVSc,  
MMedVet (Med),  
PhD, Dipl. ECVIM

## IMAGING PERFORMED BY

Dr. Isaac

## HOSPITAL NAME

Valley West & Elk  
Valley VH

## REFERRING VET

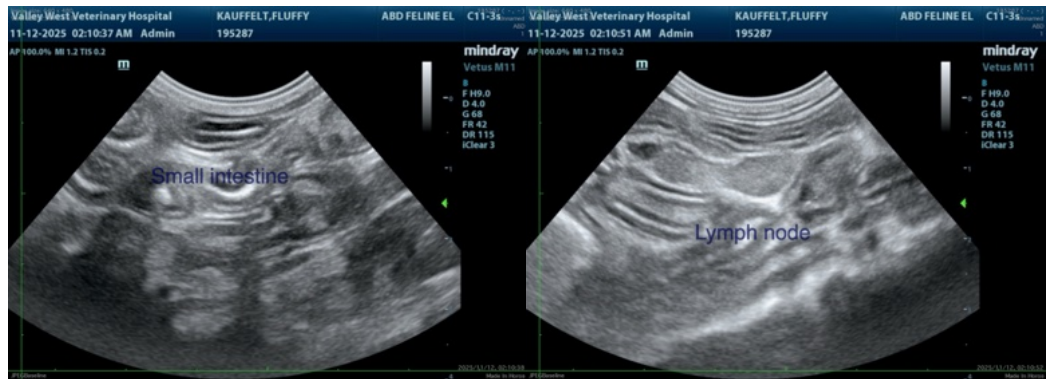
Dr. Isaac

## INVOICE

68605

## DATE

11/12/25



The information and recommendations provided are based on the images presented by the referring veterinarian/sonographer. No evaluation can be communicated regarding pathology that was not visible in the image/video clips provided.

Thank you for this referral. If the clinical or image interpretation does not parallel your findings or if I can be of any further assistance please contact me.

Remo Lobetti, BVSc, MMedVet (Med), PhD, Dipl. ECVIM (Internal Medicine)

[info@sonopath.com](mailto:info@sonopath.com)