



## PATIENT

Charlie Gardiner

## SPECIES

Canine

## BREED

## SEX

Neutered male

## AGE

8 years

## WEIGHT

67 lbs

## INTERPRETED BY

Remo Lobetti, BVSc,  
MMedVet (Med),  
PhD, Dipl. ECVIM

## IMAGING PERFORMED BY

Brian Klug

## HOSPITAL NAME

Sondel Family VC

## REFERRING VET

Dr. Frankenthal

## INVOICE

68590

## DATE

11/11/25

## PRESENTING CLINICAL SIGNS

History: Recurrent GI issues with decreased appetite, lethargy, and new onset PUPD. Air licking at night, picky eating. Previously improved with pancreatitis treatment but continues to be an issue. 3 lbs weight loss in 1 month. Current diet: boiled chicken, sweet potatoes, and carrots.  
Abnormal PE/Chem/CBC/UA Results: CBC: wnl CHEM: Cr 1.4, rest WNL HWT: wnl PLI: WNL T4: wnl Resting cortisol WNL GI Panel pending

## ULTRASONOGRAPHIC EXAMINATION OF THE ABDOMEN

### *Urinary System*

The urinary bladder is full with a normal thickness and smooth appearance of the wall. Normal anechoic urine with no sediment or uroliths evident.

Normal appearance of the trigone area, proximal urethra, and iliac blood vessels.

Normal appearance and size of the iliac lymph nodes. Ureters not visualized, which can be considered a normal finding.

Normal renal size (left measured 6.8 cm, right measured 6.8 cm), architecture, echogenic appearance, cortico-medullary differentiation, which maintains a 1:3 cortex to medulla ratio, pelvis, and capsule. No infarcts, mineralization or renoliths evident.

The prostate is small and hypoechogenic measuring 1.3 cm in width.

### *Adrenal Glands*

Normal shape, echogenic appearance, size, position, and appearance of the visible peri-adrenal vasculature. Left adrenal gland measured 0.71 cm and 0.6 cm in width. The right adrenal gland measured 0.69 cm in width.

### *Spleen*

Normal size and echogenic appearance. Smooth homogenous parenchyma and regular curvilinear capsule. Normal volume of the splenic vasculature without any overt congestion or thrombosis evident. No inflammatory, neoplastic, infarction, or infiltrative changes evident. The spleen measured 2.4 cm in width.

### *Liver*

Normal size, echogenic appearance, portal markings, and regular curvilinear capsule. No nodules or masses evident. Normal appearance of the hepatic and portal vasculature.



## PATIENT

Charlie Gardiner

## SPECIES

Canine

## BREED

## SEX

Neutered male

## AGE

8 years

## WEIGHT

67 lbs

## INTERPRETED BY

Remo Lobetti, BVSc,  
MMedVet (Med),  
PhD, Dipl. ECVIM

## IMAGING PERFORMED BY

Brian Klug

## HOSPITAL NAME

Sondel Family VC

## REFERRING VET

Dr. Frankenthal

## INVOICE

68590

## DATE

11/11/25

## ***Gallbladder***

The gallbladder is full containing normal anechoic bile. Normal thickness and echogenic appearance of the wall. Normal size and appearance of the cystic and common bile duct.

## ***Gastrointestinal***

Normal appearance of the stomach, duodenum, small intestine, ileo-cecal junction, and colon with no loss of layering, 1:3 muscularis to mucosa ratio, normal wall thickness and peristaltic activity, and no distension of the lumen. The duodenum measured 0.39 cm, small intestine 0.33 cm.

## ***Pancreas***

Normal size and echogenic appearance with a regular capsule. Normal echogenic appearance of the mesentery and fat surrounding the pancreas.

## ***Free Abdomen***

Normal mesenteric lymph nodes.

No ascites evident.

## **ULTRASONOGRAPHIC FINDINGS**

- Normal ultrasound examination of the abdomen.

## **INTERPRETATION OF THE FINDINGS & FURTHER RECOMMENDATIONS**

On this ultrasound there is no obvious etiology for the presenting clinical signs. Although the GI tract appears ultrasonographically normal, with the presenting clinical signs and underlying enteropathy, parasitic enteritis, dietary hypersensitivity and inflammatory bowel disease should still be considered.

Further assessment and therapy needs to be based on the pending results, but could include fecal analysis and endoscopy of the upper GI tract with biopsies.

Symptomatic management that can be considered would be feeding a novel protein/hypoallergenic diet, cobalamin supplementation (if indicated), course of Fenbendazole and if there is still not a satisfactory improvement then a course of Prednisolone would then be indicated.



## PATIENT

Charlie Gardiner

## SPECIES

Canine

## BREED

## SEX

Neutered male

## AGE

8 years

## WEIGHT

67 lbs

## INTERPRETED BY

Remo Lobetti, BVSc,  
MMedVet (Med),  
PhD, Dipl. ECVIM

## IMAGING PERFORMED BY

Brian Klug

## HOSPITAL NAME

Sondel Family VC

## REFERRING VET

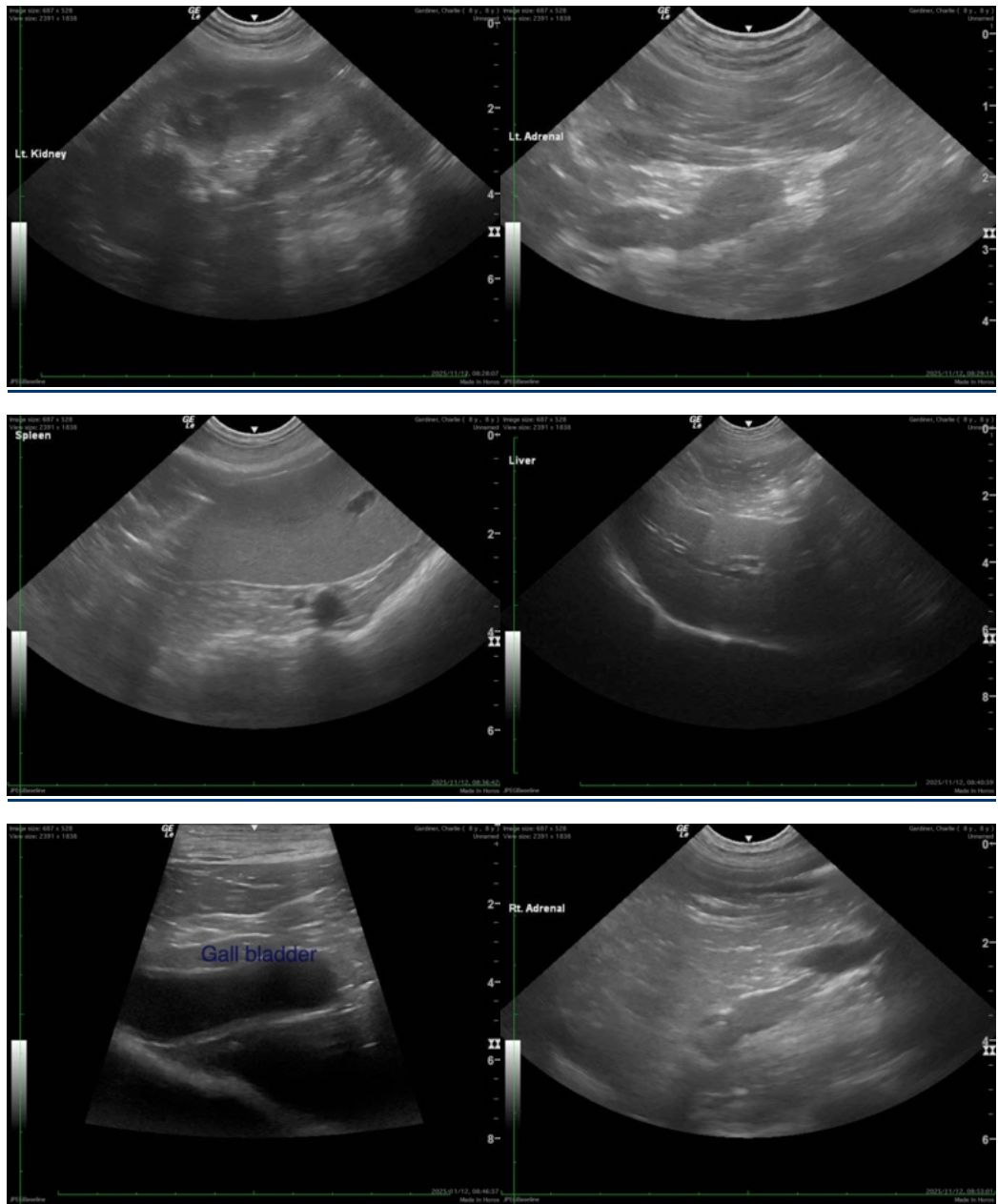
Dr. Frankenthal

## INVOICE

68590

## DATE

11/11/25





**PATIENT**

Charlie Gardiner

**SPECIES**

Canine

**BREED**

**SEX**

Neutered male

**AGE**

8 years

**WEIGHT**

67 lbs

**INTERPRETED BY**

Remo Lobetti, BVSc,  
MMedVet (Med),  
PhD, Dipl. ECVIM

**IMAGING PERFORMED BY**

Brian Klug

**HOSPITAL NAME**

Sondel Family VC

**REFERRING VET**

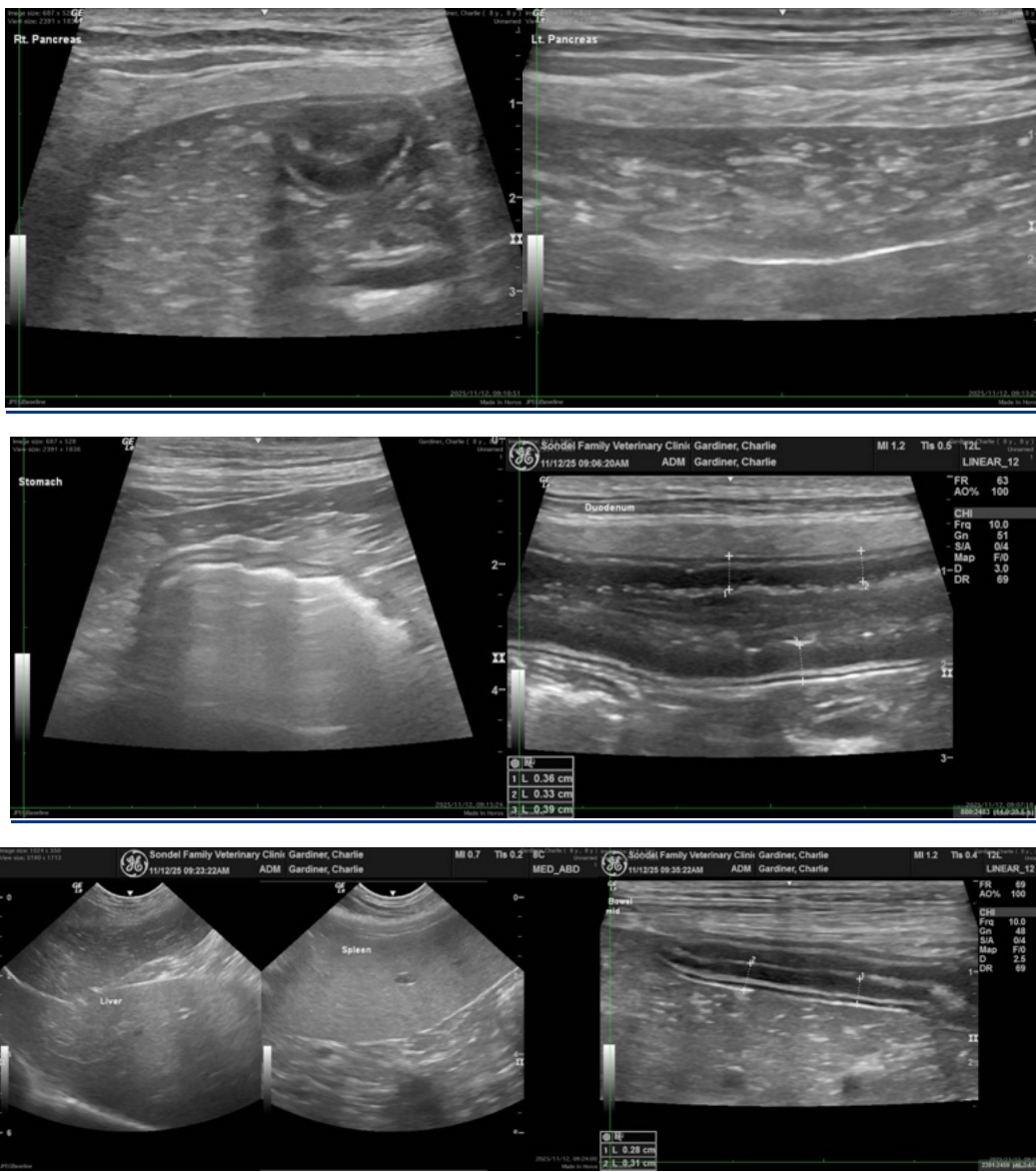
Dr. Frankenthal

**INVOICE**

68590

**DATE**

11/11/25



The information and recommendations provided are based on the images presented by the referring veterinarian/sonographer. No evaluation can be communicated regarding pathology that was not visible in the image/video clips provided.

Thank you for this referral. If the clinical or image interpretation does not parallel your findings or if I can be of any further assistance please contact me.

Remo Lobetti, BVSc, MMedVet (Med), PhD, Dipl. ECVIM (Internal Medicine)

[info@sonopath.com](mailto:info@sonopath.com)