



PATIENT

Tycho Carter

SPECIES

Canine

BREED

Poodle

SEX

Neutered male

AGE

5 years

WEIGHT

39.5 lbs

INTERPRETED BY

Remo Lobetti, BVSc,
MMedVet (Med),
PhD, Dipl. ECVIM

IMAGING PERFORMED BY

Dr. Wagner

HOSPITAL NAME

Angeles Clinic for
Animals

REFERRING VET

Dr. Wagner

INVOICE

68586

DATE

11/11/25

PRESENTING CLINICAL SIGNS

History: Owner reports approx 1 month duration right sided pain, increased thirst/urination.

Appetite good. No medication/toxin exposure.

Abnormal PE/Chem/CBC/UA Results: CBC - NSF Chem - BUN 30, Creat 2.3, ALP 274, ALT 12 UA - USG 1.014. 3+ protein, >100 RBC; UP:C 5.8 4dx negative **lepto PCR, repeat UA w/UP:C and culture pending on non-bloody sample***

ULTRASONOGRAPHIC EXAMINATION OF THE ABDOMEN

Urinary System

The urinary bladder is full with a normal thickness and smooth appearance of the wall. Normal anechoic urine with no sediment or uroliths evident.

Normal appearance of the trigone area, proximal urethra, and iliac blood vessels.

Normal appearance and size of the iliac lymph nodes. Ureters not visualized, which can be considered a normal finding.

Normal renal size (left measured 5.9 cm, right measured 6.0 cm), architecture, echogenic appearance, cortico-medullary differentiation, which maintains a 1:3 cortex to medulla ratio, pelvis, and capsule. No infarcts, mineralization or renoliths evident. normal color flow pattern is noted in both kidneys.

The prostate is small and hypoechogenic.

Adrenal Glands

Normal shape, echogenic appearance, size, position, and appearance of the visible peri-adrenal vasculature. Left adrenal gland measured 0.43 cm in width. The right adrenal gland measured 0.46 cm in width.

Spleen

Normal size and echogenic appearance. Smooth homogenous parenchyma and regular curvilinear capsule. Normal volume of the splenic vasculature without any overt congestion or thrombosis evident. No inflammatory, neoplastic, infarction, or infiltrative changes evident. The spleen measured 2.0 cm in width.

Liver

The liver is small in size with normal echogenic appearance, portal markings, and regular curvilinear capsule. No nodules or masses evident. Normal appearance of the hepatic and portal vasculature.



PATIENT

Tycho Carter

SPECIES

Canine

BREED

Poodle

SEX

Neutered male

AGE

5 years

WEIGHT

39.5 lbs

INTERPRETED BY

Remo Lobetti, BVSc,
MMedVet (Med),
PhD, Dipl. ECVIM

IMAGING PERFORMED BY

Dr. Wagner

HOSPITAL NAME

Angeles Clinic for
Animals

REFERRING VET

Dr. Wagner

INVOICE

68586

DATE

11/11/25

Gallbladder

The gallbladder is small containing normal anechoic bile. Normal thickness and echogenic appearance of the wall. Normal size and appearance of the cystic and common bile duct.

Gastrointestinal

Normal appearance of the stomach, duodenum, small intestine, ileo-cecal junction, and colon with no loss of layering, 1:3 muscularis to mucosa ratio, normal wall thickness and peristaltic activity, and no distension of the lumen.

Pancreas

The visible sections of the pancreas are of normal size and echogenic appearance with a regular capsule. Normal echogenic appearance of the mesentery and fat surrounding the pancreas.

Free Abdomen

Normal mesenteric lymph nodes.

No ascites evident.

ULTRASONOGRAPHIC FINDINGS

- Normal ultrasound examination of the abdomen.

INTERPRETATION OF THE FINDINGS & FURTHER RECOMMENDATIONS

On this ultrasound there is no obvious etiology for the presenting clinical signs.

With the presenting clinical sign of right-sided pain, spinal, orthopedic and muscular conditions should be considered.

Further assessment would be full neurological and orthopedic examinations and if not already done survey spinal radiographs.

Specific therapy would be dependent on an etiological diagnosis.



PATIENT

Tycho Carter

SPECIES

Canine

BREED

Poodle

SEX

Neutered male

AGE

5 years

WEIGHT

39.5 lbs

INTERPRETED BY

Remo Lobetti, BVSc,
MMedVet (Med),
PhD, Dipl. ECVIM

IMAGING PERFORMED BY

Dr. Wagner

HOSPITAL NAME

Angeles Clinic for
Animals

REFERRING VET

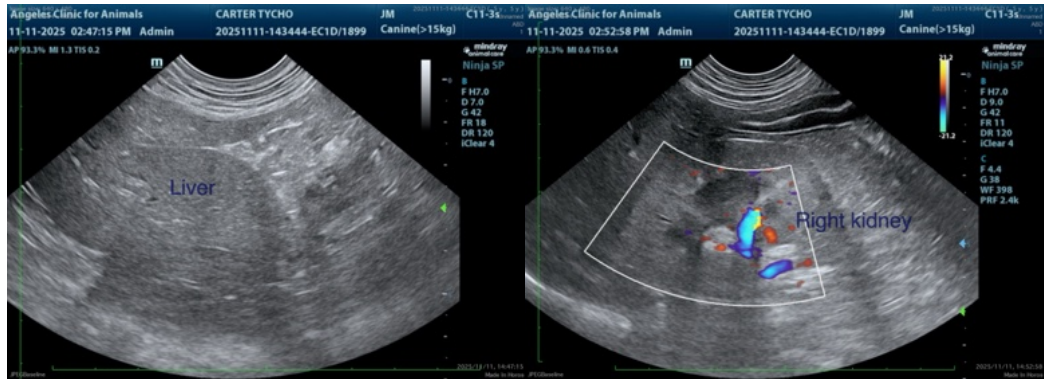
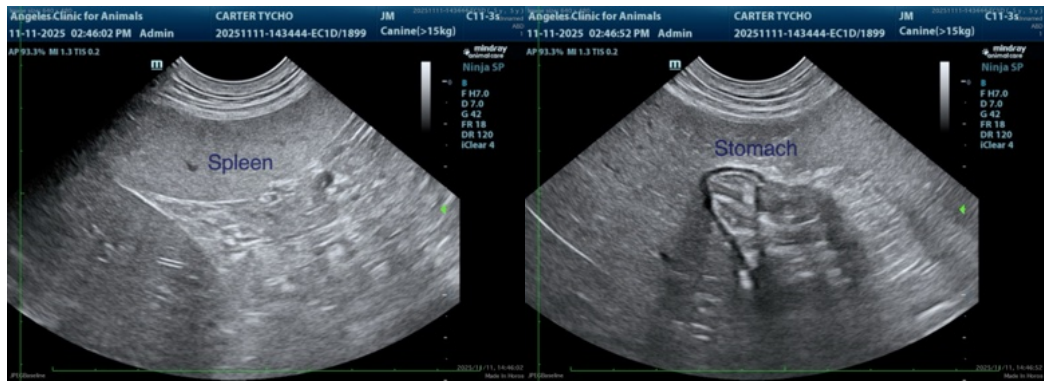
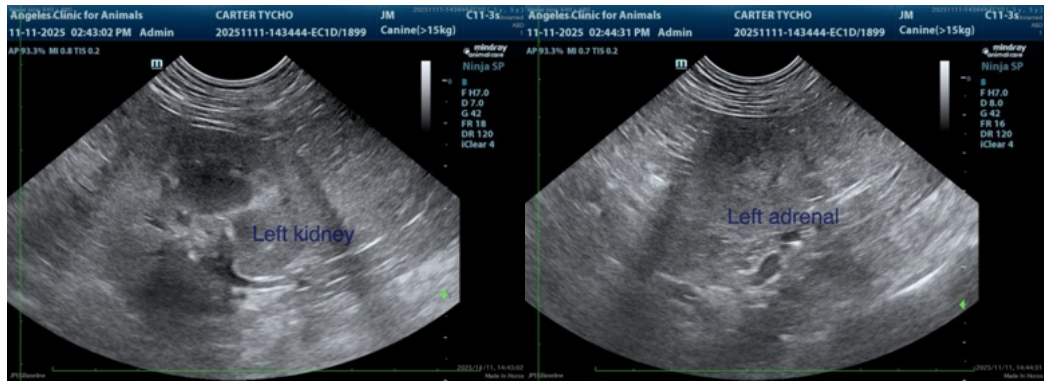
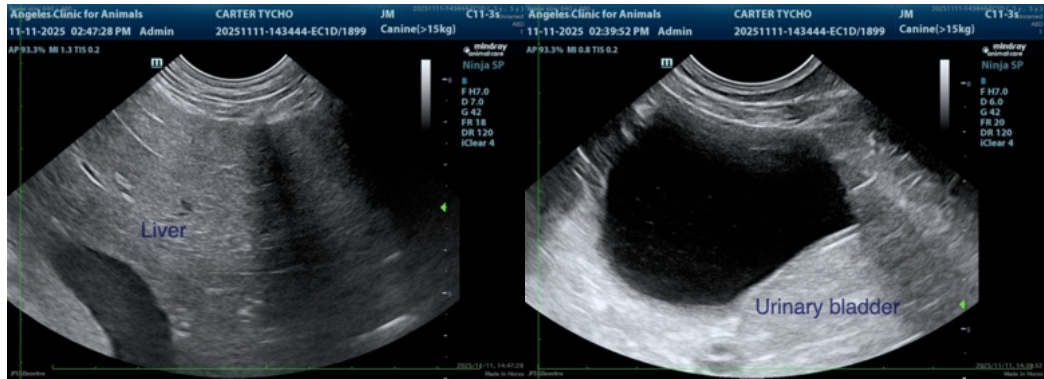
Dr. Wagner

INVOICE

68586

DATE

11/11/25





PATIENT

Tycho Carter

SPECIES

Canine

BREED

Poodle

SEX

Neutered male

AGE

5 years

WEIGHT

39.5 lbs

INTERPRETED BY

Remo Lobetti, BVSc,
MMedVet (Med),
PhD, Dipl. ECVIM

IMAGING PERFORMED BY

Dr. Wagner

HOSPITAL NAME

Angeles Clinic for
Animals

REFERRING VET

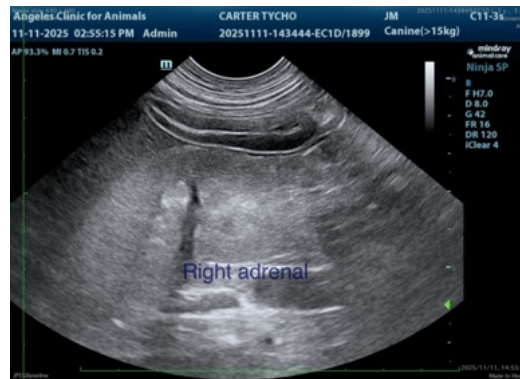Dr. Wagner

INVOICE

68586

DATE

11/11/25



The information and recommendations provided are based on the images presented by the referring veterinarian/sonographer. No evaluation can be communicated regarding pathology that was not visible in the image/video clips provided.

Thank you for this referral. If the clinical or image interpretation does not parallel your findings or if I can be of any further assistance please contact me.

Remo Lobetti, BVSc, MMedVet (Med), PhD, Dipl. ECVIM (Internal Medicine)

info@sonopath.com