



PATIENT

Toby Martini

SPECIES

Canine

BREED

King Charles Cavalier

SEX

Male

AGE

1 year

WEIGHT

15.4 lbs

INTERPRETED BY

Remo Lobetti, BVSc,
MMedVet (Med),
PhD, Dipl. ECVIM

IMAGING PERFORMED BY

Dr. Tessa Fiamengo

HOSPITAL NAME

Slade VH

REFERRING VET

Dr. Fiamengo

INVOICE

68520

DATE

11/10/25

PRESENTING CLINICAL SIGNS

History: Was intact at time of ultrasound and neutered afterwards same day. Urinalysis keeps having WBC and RBC's despite resolution of prior UTI confirmed by culture. Wanting to check urinary tract and kidneys specifically to rule out any concerns.

ULTRASONOGRAPHIC EXAMINATION OF THE ABDOMEN

Urinary System

The urinary bladder is small with a normal thickness and smooth appearance of the wall. Normal anechoic urine with no sediment or uroliths evident.

Normal appearance of the trigone area, proximal urethra, and iliac blood vessels.

Normal appearance and size of the iliac lymph nodes. Ureters not visualized, which can be considered a normal finding.

Normal renal size (left measured 4.1 cm, right measured 4.5 cm), architecture, echogenic appearance, cortico-medullary differentiation, which maintains a 1:3 cortex to medulla ratio, pelvis, and capsule. No infarcts, mineralization or renoliths evident. Normal color flow pattern is evident in both kidneys.

The prostate is normal in size and appearance with a regular curvilinear capsule and a normal appearance of the periprostatic tissue. A small parenchymal cyst is evident measuring 0.8 cm in size. The prostate measured 2.2 x 2.3 cm.

Adrenal Glands

The left adrenal gland is normal in shape, echogenic appearance, size, position, and appearance of the visible peri-adrenal vasculature. Left adrenal gland measured 0.35 cm in width. The right adrenal gland was not clearly visualized, but appears to be of normal shape, echogenic appearance and size.

Spleen

Normal size and echogenic appearance. Smooth homogenous parenchyma and regular curvilinear capsule. Normal volume of the splenic vasculature without any overt congestion or thrombosis evident. No inflammatory, neoplastic, infarction, or infiltrative changes evident. The spleen measured 0.7 cm in width.

Liver

Normal size, echogenic appearance, portal markings, and regular curvilinear capsule. No nodules or masses evident. Normal appearance of the hepatic and portal vasculature.



PATIENT

Toby Martini

SPECIES

Canine

BREED

King Charles Cavalier

SEX

Male

AGE

1 year

WEIGHT

15.4 lbs

INTERPRETED BY

Remo Lobetti, BVSc,
MMedVet (Med),
PhD, Dipl. ECVIM

IMAGING PERFORMED BY

Dr. Tessa Fiamengo

HOSPITAL NAME

Slade VH

REFERRING VET

Dr. Fiamengo

INVOICE

68520

DATE

11/10/25

Gallbladder

The gallbladder is full containing normal anechoic bile. Normal thickness and echogenic appearance of the wall. Normal size and appearance of the cystic and common bile duct.

Gastrointestinal

Normal appearance of the stomach, duodenum, small intestine, ileo-cecal junction, and colon with no loss of layering, 1:3 muscularis to mucosa ratio, normal wall thickness and peristaltic activity, and no distension of the lumen.

Pancreas

The visible sections of the pancreas are of normal size and echogenic appearance with a regular capsule. Normal echogenic appearance of the mesentery and fat surrounding the pancreas.

Free Abdomen

Normal mesenteric lymph nodes.

No ascites evident.

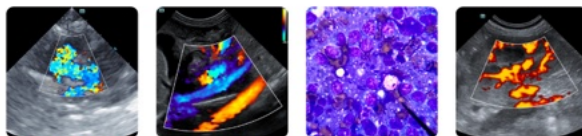
ULTRASONOGRAPHIC FINDINGS

- Prostatic cyst.

INTERPRETATION OF THE FINDINGS & FURTHER RECOMMENDATIONS

Hematuria can most likely be ascribed to the prostatic cyst.

As the patient has now been castrated the cyst should resolve. However, ultrasound monitoring would be recommended and if there is no resolution then percutaneous drainage would be indicated. The fluid should be submitted for cytology and culture.



PATIENT

Toby Martini

SPECIES

Canine

BREED

King Charles Cavalier

SEX

Male

AGE

1 year

WEIGHT

15.4 lbs

INTERPRETED BY

Remo Lobetti, BVSc,
MMedVet (Med),
PhD, Dipl. ECVIM

IMAGING PERFORMED BY

Dr. Tessa Fiamengo

HOSPITAL NAME

Slade VH

REFERRING VET

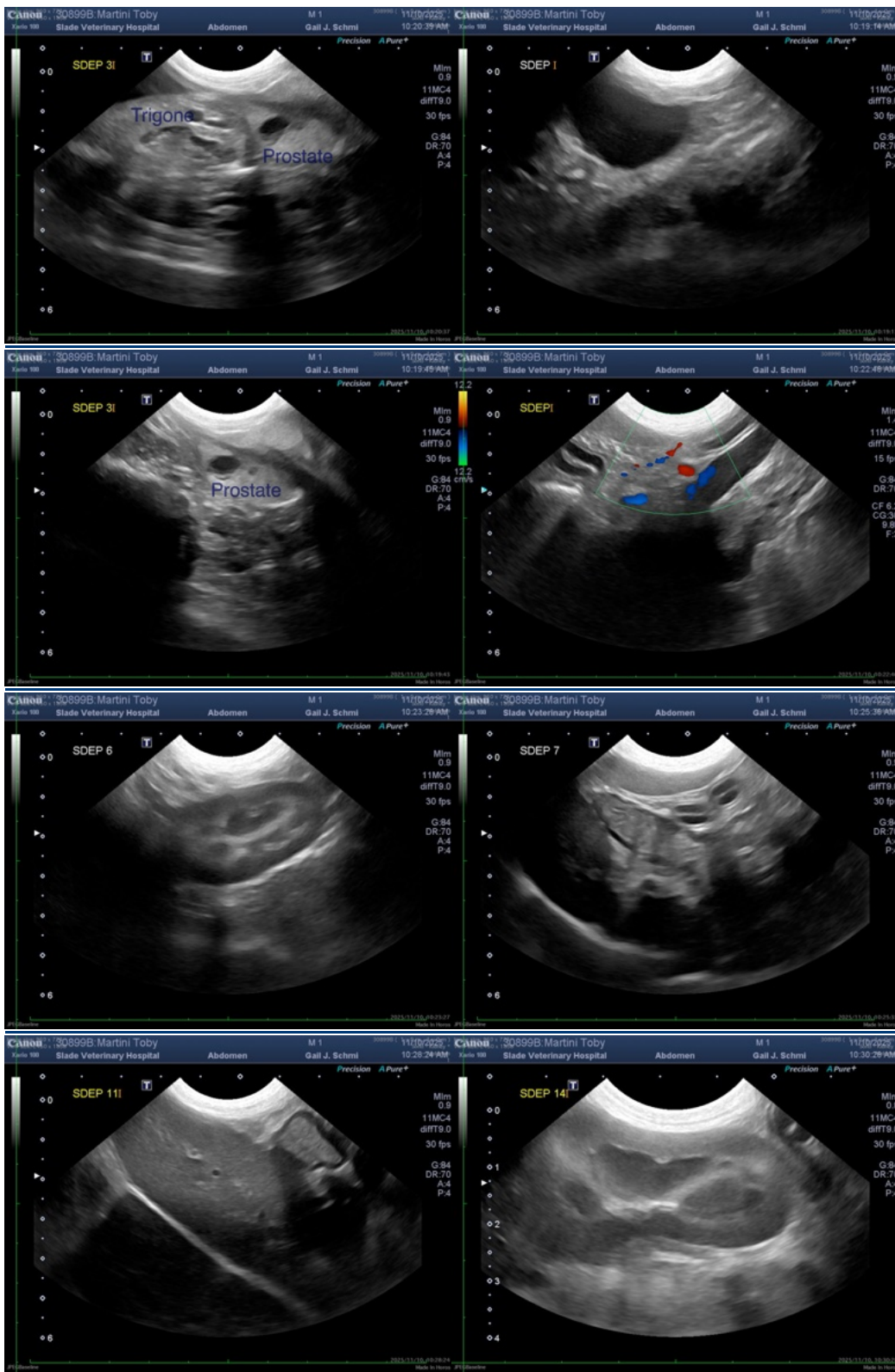
Dr. Fiamengo

INVOICE

68520

DATE

11/10/25





PATIENT

Toby Martini

The information and recommendations provided are based on the images presented by the referring veterinarian/sonographer. No evaluation can be communicated regarding pathology that was not visible in the image/video clips provided.

SPECIES

Canine

Thank you for this referral. If the clinical or image interpretation does not parallel your findings or if I can be of any further assistance please contact me.

BREED

King Charles Cavalier

Remo Lobetti, BVSc, MMedVet (Med), PhD, Dipl. ECVIM (Internal Medicine)

info@sonopath.com

SEX

Male

AGE

1 year

WEIGHT

15.4 lbs

INTERPRETED BY

Remo Lobetti, BVSc,
MMedVet (Med),
PhD, Dipl. ECVIM

IMAGING PERFORMED BY

Dr. Tessa Fiamengo

HOSPITAL NAME

Slade VH

REFERRING VET

Dr. Fiamengo

INVOICE

68520

DATE

11/10/25