

PATIENT

Munchkin Beardslee

SPECIES

Canine

BREED

Coton de Tulear

SEX

Spayed female

AGE

7 years

WEIGHT

8 lbs

INTERPRETED BY

Remo Lobetti, BVSc,
MMedVet (Med),
PhD, Dipl. ECVIM

IMAGING PERFORMED BY

Dr. Coe

HOSPITAL NAME

Riverside Animal Clinic

REFERRING VET

Dr. Cline

INVOICE

69962

DATE

1/9/26

PRESENTING CLINICAL SIGNS

History: Mildly elevated ALT (399) and AST (119) noted at time of COHAT 11/18/2025. Proceeded with COHAT, Rx: Denamarin for 30 days following procedure. Recheck ALT 12/19/2025 = 769, AST = 123. No diet changes. Eats lams Small bites ad lib. Does get table scraps/people food. No reported GI signs. Meds: Simparica Trio. Nothing else regularly. Trazodone PRN situational anxiety/trips. Abnormal PE/Chem/CBC/UA Results: Progressive elevation ALT/AST. TBili, ALKP, and GGT WRI. BUN/Crea/PCV WNL. No CBC or complete chemistry performed. HW-4DX = Negative 11/2025.

ULTRASONOGRAPHIC EXAMINATION OF THE ABDOMEN

Urinary System

The urinary bladder is full with a normal thickness and smooth appearance of the wall. Normal anechoic urine with no sediment or uroliths evident.

Normal appearance of the trigone area, proximal urethra, and iliac blood vessels.

Normal appearance and size of the iliac lymph nodes. Ureters not visualized, which can be considered a normal finding.

Normal renal size (left measured 3.3 cm, right measured 2.7 cm), architecture, echogenic appearance, cortico-medullary differentiation, which maintains a 1:3 cortex to medulla ratio, pelvis, and capsule. No infarcts, mineralization or renoliths evident. Normal color flow pattern is evident in both kidneys.

Adrenal Glands

Normal shape, echogenic appearance, size, position, and appearance of the visible peri-adrenal vasculature. Left adrenal gland measured 1.36 cm in length x 0.41 cm and 0.46 cm in width. The right adrenal gland measured 1.04 cm in length x 0.33 cm and 0.26 cm in width.

Spleen

Normal size and echogenic appearance. Smooth homogenous parenchyma and regular curvilinear capsule. Normal volume of the splenic vasculature without any overt congestion or thrombosis evident. No inflammatory, neoplastic, infarction, or infiltrative changes evident. The spleen measured 1.5 cm in width.

Liver

Normal size, echogenic appearance, portal markings, and regular curvilinear capsule. No nodules or masses evident. Normal appearance of the hepatic and portal vasculature.



PATIENT

Munchkin Beardslee

SPECIES

Canine

BREED

Coton de Tulear

SEX

Spayed female

AGE

7 years

WEIGHT

8 lbs

INTERPRETED BY

Remo Lobetti, BVSc,
MMedVet (Med),
PhD, Dipl. ECVIM

IMAGING PERFORMED BY

Dr. Coe

HOSPITAL NAME

Riverside Animal Clinic

REFERRING VET

Dr. Cline

INVOICE

69962

DATE

1/9/26

Gallbladder

The gallbladder is full containing normal anechoic bile. Normal thickness and echogenic appearance of the wall. A small, hypoechoic polyp was noted and measured approximately 0.4 x 0.7 cm within the gallbladder. Normal size and appearance of the cystic and common bile duct.

Gastrointestinal

Normal appearance of the stomach, duodenum, small intestine, ileo-cecal junction, and colon with no loss of layering, 1:3 muscularis to mucosa ratio, normal wall thickness and peristaltic activity, and no distension of the lumen.

Pancreas

The visible sections of the pancreas are of normal size and echogenic appearance with a regular capsule. Normal echogenic appearance of the mesentery and fat surrounding the pancreas.

Free Abdomen

Normal mesenteric lymph nodes.

No ascites evident.

ULTRASONOGRAPHIC FINDINGS

- Gallbladder polyp.

INTERPRETATION OF THE FINDINGS & FURTHER RECOMMENDATIONS

In essence, a normal ultrasound examination of the abdomen as a gallbladder polyp can be considered an incidental finding.

Although the liver appears ultrasonographically normal, with the progressive elevation of liver enzyme activity, an underlying hepatopathy such as reactive hyperplasia, vacuolar and metabolic should still be considered.

Hepatitis and infiltrative neoplasia would be highly unlikely differential diagnosis.

Further assessment would be FNA cytology of the liver. However, a tru cut or wedge biopsy may be required for a final etiological diagnosis.

Ultrasound monitoring of the gallbladder polyp would be recommended.

Specific therapy would be dependent on an etiological diagnosis. Symptomatic management that can be considered would be the use of Ursodiol with regular monitoring of liver enzyme activity.



PATIENT

Munchkin Beardslee

SPECIES

Canine

BREED

Coton de Tulear

SEX

Spayed female

AGE

7 years

WEIGHT

8 lbs

INTERPRETED BY

Remo Lobetti, BVSc,
MMedVet (Med),
PhD, Dipl. ECVIM

IMAGING PERFORMED BY

Dr. Coe

HOSPITAL NAME

Riverside Animal Clinic

REFERRING VET

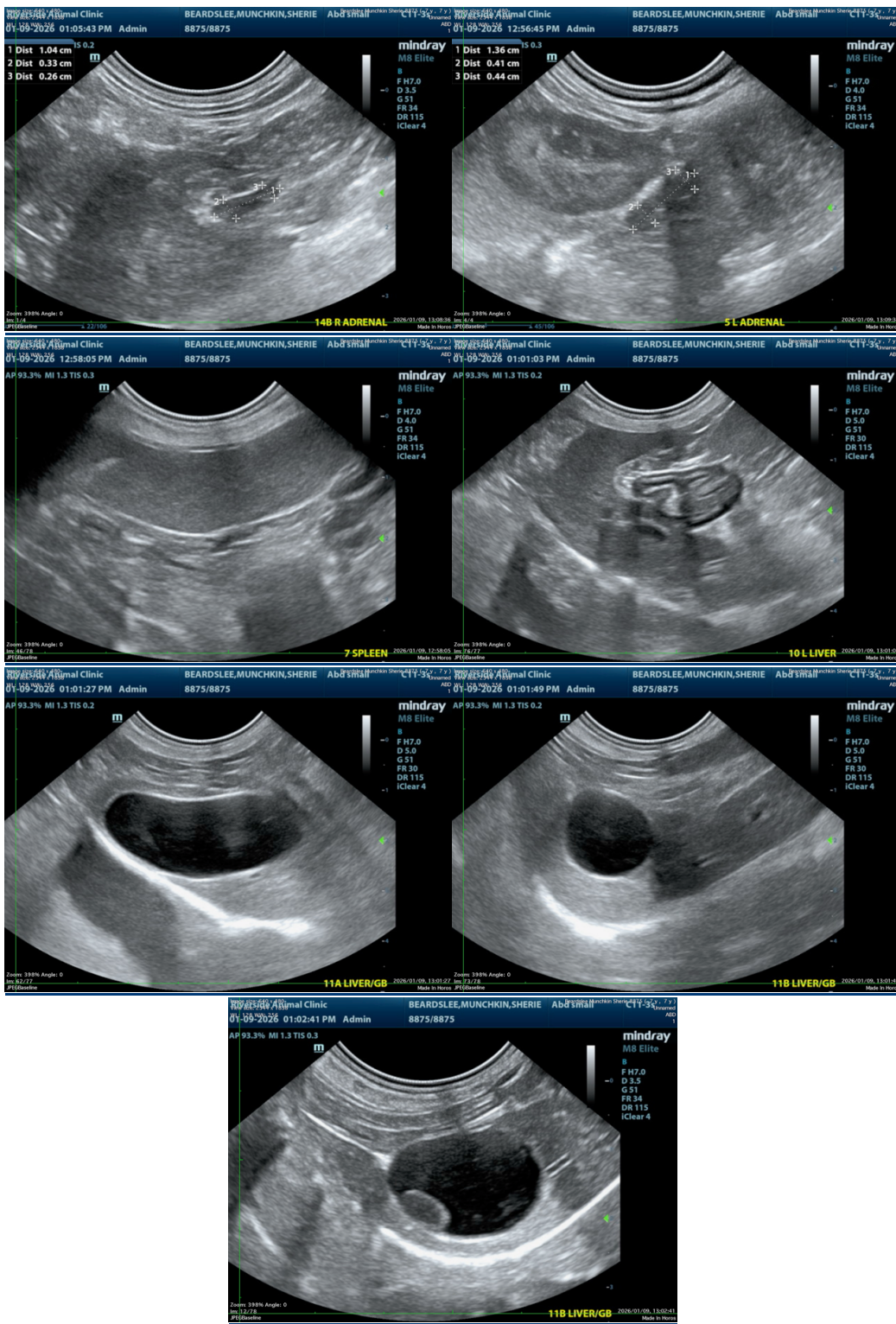
Dr. Cline

INVOICE

69962

DATE

1/9/26



The information and recommendations provided are based on the images presented by the



PATIENT

Munchkin Beardslee

SPECIES

Canine

BREED

Coton de Tulear

SEX

Spayed female

AGE

7 years

WEIGHT

8 lbs

INTERPRETED BY

Remo Lobetti, BVSc,
MMedVet (Med),
PhD, Dipl. ECVIM

IMAGING PERFORMED BY

Dr. Coe

HOSPITAL NAME

Riverside Animal Clinic

REFERRING VET

Dr. Cline

INVOICE

69962

DATE

1/9/26

referring veterinarian/sonographer. No evaluation can be communicated regarding pathology that was not visible in the image/video clips provided.

Thank you for this referral. If the clinical or image interpretation does not parallel your findings or if I can be of any further assistance please contact me.

Remo Lobetti, BVSc, MMedVet (Med), PhD, Dipl. ECVIM (Internal Medicine)

info@sonopath.com