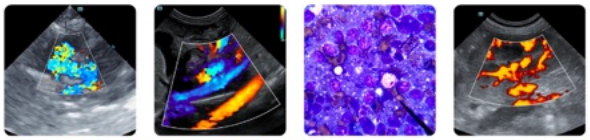

PATIENT
Ginger Gianetti

SPECIES
Feline

BREED
Domestic Shorthair

SEX
Spayed female

AGE
15 years

WEIGHT
11.4 lbs

INTERPRETED BY
Remo Lobetti, BVSc, MMedVet (Med), PhD, Dipl. ECVIM

IMAGING PERFORMED BY
Dr. Ammeraal

HOSPITAL NAME
Sova AH

REFERRING VET
Dr. Ammeraal

INVOICE
69944

DATE
1/9/26

PRESENTING CLINICAL SIGNS

History: Decreased appetite the past month. Acts like wants to eat and walks away. Also not holding down food as much when she does eat and vomits it up. Also, past couple days, stools normal then going to gelatinous. Vaccinated for FVRCP and Rabies 1 month ago
BCS 6/9, Lost 1.5 lbs in month, Grade 2-3 dental disease CBC Basophils 1 month ago 740/uL now down to 486/uL Chem normal

ULTRASONOGRAPHIC EXAMINATION OF THE ABDOMEN

Urinary System

The urinary bladder is small with a normal thickness and smooth appearance of the wall. Normal anechoic urine with no sediment or uroliths evident.

Normal appearance of the trigone area, proximal urethra, and iliac blood vessels.

Enlarged iliac lymph nodes measuring up to 0.6 x 1.6 cm in size with a hypoechogenic appearance, but maintained a normal shape. Ureters not visualized, which can be considered a normal finding.

Normal renal size (left measured 3.9 cm, right measured 3.9 cm), architecture, echogenic appearance, cortico-medullary differentiation, which maintains a 1:3 cortex to medulla ratio, pelvis, and capsule. No infarcts, mineralization or renoliths evident.

Adrenal Glands

Normal shape, echogenic appearance, size, position, and appearance of the visible peri-adrenal vasculature. Left adrenal gland measured 1.01 cm in length x 0.48 cm and 0.47 cm in width. The right adrenal gland measured 1.11 cm in length x 0.49 cm and 0.43 cm in width.

Spleen

Normal size and echogenic appearance. Smooth homogenous parenchyma and regular curvilinear capsule. Normal volume of the splenic vasculature without any overt congestion or thrombosis evident. No inflammatory, neoplastic, infarction, or infiltrative changes evident. The spleen measured 0.6 cm in width.

Liver

Normal size, echogenic appearance, portal markings, and regular curvilinear capsule. No nodules or masses evident. Normal appearance of the hepatic and portal vasculature.

Gallbladder

The gallbladder is small containing normal anechoic bile. Normal thickness and echogenic appearance of the wall. Normal size and appearance of the cystic and common bile duct.

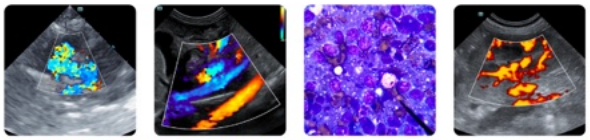

PATIENT
Ginger Gianetti

SPECIES
Feline

BREED
Domestic Shorthair

SEX
Spayed female

AGE
15 years

WEIGHT
11.4 lbs

INTERPRETED BY
Remo Lobetti, BVSc, MMedVet (Med), PhD, Dipl. ECVIM

IMAGING PERFORMED BY
Dr. Ammeraal

HOSPITAL NAME
Sova AH

REFERRING VET
Dr. Ammeraal

INVOICE
69944

DATE
1/9/26

Gastrointestinal

Normal appearance of the stomach, duodenum, ileo-cecal junction, and colon with no loss of layering, 1:3 muscularis to mucosa ratio, normal wall thickness and peristaltic activity, and no distension of the lumen. Normal thickness of the small intestine with no loss of layering with an increase in the muscularis to mucosa ratio, normal peristaltic activity and no distension of the lumen.

Pancreas

The visible sections of the pancreas are of normal size and echogenic appearance with a regular capsule. Normal echogenic appearance of the mesentery and fat surrounding the pancreas.

Free Abdomen

Prominent mesenteric lymph nodes measuring up to 0.7 x 0.9 cm in size with a rounded shape and hypoechogenic appearance.

Hyperechogenic appearance of the mesentery surrounding the lymph nodes.

No ascites evident.

ULTRASONOGRAPHIC FINDINGS

- Enteropathy.
- Iliac and mesenteric lymphadenomegaly.

INTERPRETATION OF THE FINDINGS & FURTHER RECOMMENDATIONS

Etiologies for the enteropathy would be parasitic enteritis, dietary hypersensitivity and inflammatory bowel disease with lymphoma an important differential diagnosis especially with the abdominal lymphadenomegaly.

Etiologies for the lymphadenomegaly would be reactive hyperplasia, lymphadenitis and infiltrative neoplasia.

Further assessment would be fecal analysis, cobalamin and folate assay. FNA cytology of the lymph nodes and endoscopy of upper GI tract with biopsies is recommended.

Specific therapy would be dependent on an etiological diagnosis. Symptomatic management that can be considered would be feeding a novel protein/hypoallergenic diet, course of Fenbendazole, cobalamin supplementation and a course of Prednisolone.

SonoPath

FOSTERING THE ART OF VETERINARY MEDICINE™

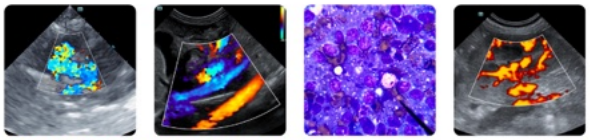

Clinical Sonography & Telecytology

Educational Teleconsultation Services™

SonoPath.com info@sonopath.com 1.800.838.4268

PATIENT

Ginger Gianetti

SPECIES

Feline

BREED

Domestic Shorthair

SEX

Spayed female

AGE

15 years

WEIGHT

11.4 lbs

INTERPRETED BY

Remo Lobetti, BVSc, MMedVet (Med), PhD, Dipl. ECVIM

IMAGING PERFORMED BY

Dr. Ammeraal

HOSPITAL NAME

Sova AH

REFERRING VET

Dr. Ammeraal

INVOICE

69944

DATE

1/9/26

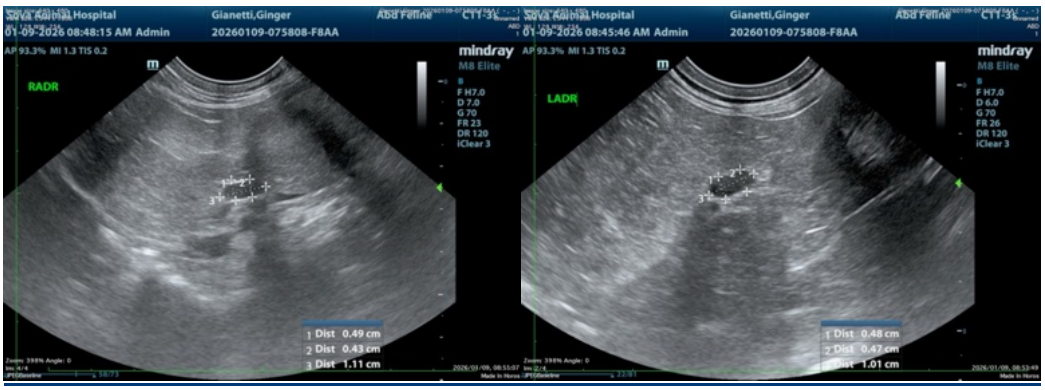

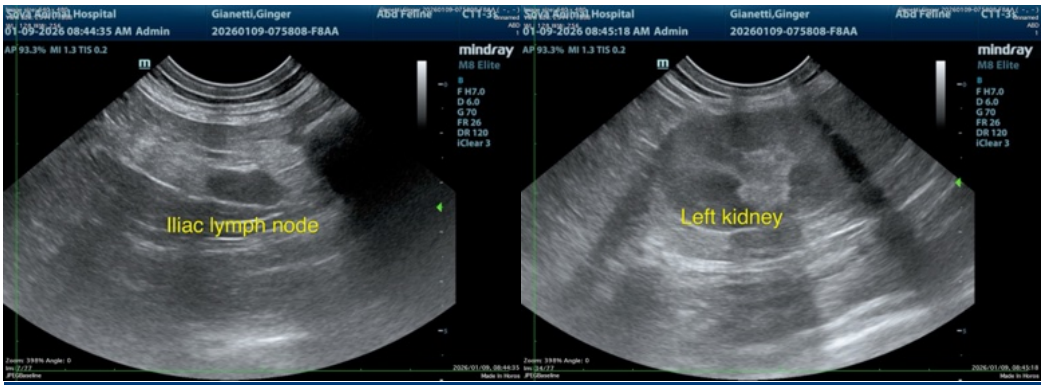

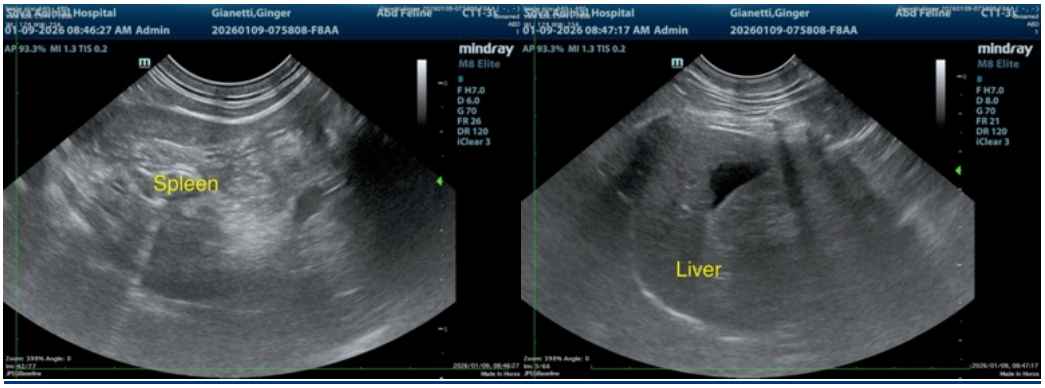

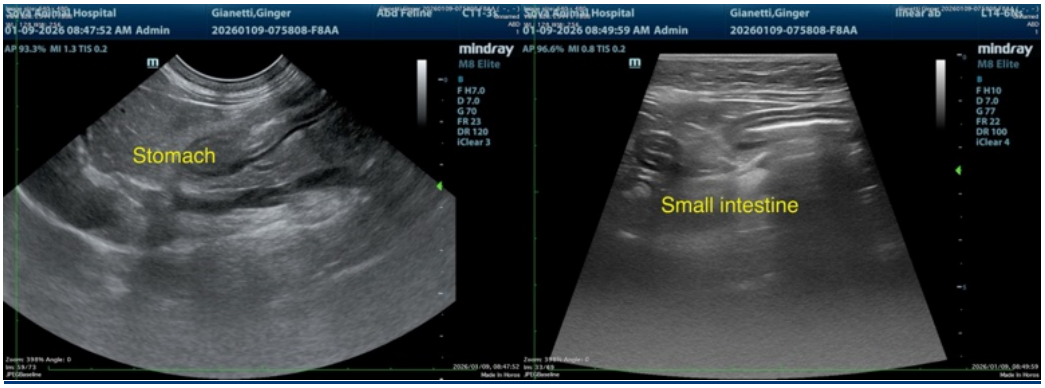

SonoPath
FOSTERING THE ART OF VETERINARY MEDICINE™

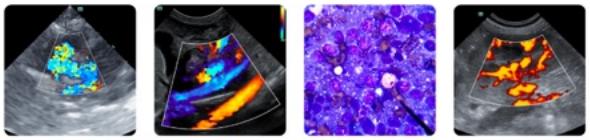

Clinical Sonography & Telecytology
Educational Teleconsultation Services™

SonoPath.com info@sonopath.com 1.800.838.4268

PATIENT

Ginger Gianetti

SPECIES

Feline

BREED

Domestic Shorthair

SEX

Spayed female

AGE

15 years

WEIGHT

11.4 lbs

INTERPRETED BY

Remo Lobetti, BVSc, MMedVet (Med), PhD, Dipl. ECVIM

IMAGING PERFORMED BY

Dr. Ammeraal

HOSPITAL NAME

Sova AH

REFERRING VET

Dr. Ammeraal

INVOICE

69944

DATE

1/9/26

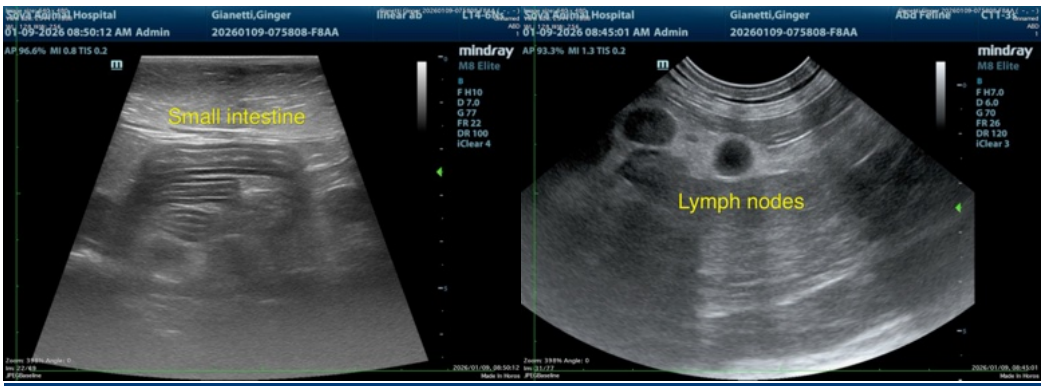

The information and recommendations provided are based on the images presented by the referring veterinarian/sonographer. No evaluation can be communicated regarding pathology that was not visible in the image/video clips provided.

Thank you for this referral. If the clinical or image interpretation does not parallel your findings or if I can be of any further assistance please contact me.

Remo Lobetti, BVSc, MMedVet (Med), PhD, Dipl. ECVIM (Internal Medicine)

info@sonopath.com