



PATIENT

Georgia Greaney

SPECIES

Canine

BREED

German Shepherd

SEX

Spayed female

AGE

9 years

WEIGHT

68.2 lbs

INTERPRETED BY

Remo Lobetti, BVSc,
MMedVet (Med),
PhD, Dipl. ECVIM

IMAGING PERFORMED BY

Grace Jayne CVT

HOSPITAL NAME

Ark Animal Homecare

REFERRING VET

Dr. Dingle

INVOICE

69936

DATE

1/8/26

PRESENTING CLINICAL SIGNS

History: GI issues including intermittent vomiting, but mostly diarrhea for about one year. Metronidazole helps while she is on the medication, but diarrhea resumes after finishing. Georgia is currently taking omeprazole and proviable. Some weight loss with intermittent hyporexia. Abnormal CPL Dec 2025. Gi panel pending. Abdominal radiograph consult pending.

ULTRASONOGRAPHIC EXAMINATION OF THE ABDOMEN

Urinary System

The urinary bladder is small with a normal thickness and smooth appearance of the wall. Normal anechoic urine with no sediment or uroliths evident.

Normal appearance of the trigone area, proximal urethra, and iliac blood vessels.

Normal appearance and size of the iliac lymph nodes. Ureters not visualized, which can be considered a normal finding.

Normal renal size (left measured 6.5 cm, right measured 6.2 cm), architecture, echogenic appearance, cortico-medullary differentiation, which maintains a 1:3 cortex to medulla ratio, pelvis, and capsule. No infarcts, mineralization or renoliths evident.

Adrenal Glands

Normal shape, echogenic appearance, size, position, and appearance of the visible peri-adrenal vasculature. Left adrenal gland measured 0.46 cm and 0.51 cm in width. The right adrenal gland was poorly visualized, but appears to be of normal shape, echogenic appearance and size.

Spleen

Normal size and echogenic appearance. Smooth homogenous parenchyma and regular curvilinear capsule. Normal volume of the splenic vasculature without any overt congestion or thrombosis evident. No inflammatory, neoplastic, infarction, or infiltrative changes evident. The spleen measured 2.2 cm in width.

Liver

Normal size, echogenic appearance, portal markings, and regular curvilinear capsule. No nodules or masses evident. Normal appearance of the hepatic and portal vasculature.

Gallbladder

The gallbladder is full containing normal anechoic bile. Normal thickness and echogenic appearance of the wall. Normal size and appearance of the cystic and common bile duct.



PATIENT

Georgia Greaney

SPECIES

Canine

BREED

German Shepherd

SEX

Spayed female

AGE

9 years

WEIGHT

68.2 lbs

INTERPRETED BY

Remo Lobetti, BVSc,
MMedVet (Med),
PhD, Dipl. ECVIM

IMAGING PERFORMED BY

Grace Jayne CVT

HOSPITAL NAME

Ark Animal Homecare

REFERRING VET

Dr. Dingle

INVOICE

69936

DATE

1/8/26

Gastrointestinal

Normal appearance of the stomach, duodenum, ileo-cecal junction, and colon with no loss of layering, 1:3 muscularis to mucosa ratio, normal wall thickness and peristaltic activity, and no distension of the lumen. Normal thickness of the small intestine measuring up to 0.35 cm with no loss of layering but with an increase in the muscularis to mucosa ratio, normal peristaltic activity and no distension of the lumen.

Pancreas

The visible sections of the pancreas are of normal size and echogenic appearance with a regular capsule. Normal echogenic appearance of the mesentery and fat surrounding the pancreas.

Free Abdomen

Normal mesenteric lymph nodes.

No ascites evident.

ULTRASONOGRAPHIC FINDINGS

- Enteropathy.

INTERPRETATION OF THE FINDINGS & FURTHER RECOMMENDATIONS

Etiologies for the enteropathy would be parasitic enteritis, dietary hypersensitivity and inflammatory bowel disease and possibly exocrine pancreatic insufficiency.

Further assessment needs to be based on the pending results, but could include fecal analysis and endoscopy of the upper GI tract with biopsies.

Specific therapy would be dependent on an etiological diagnosis.

Symptomatic management that could be considered would be feeding small frequent meals of a novel protein/hypoallergenic diet, course of Fenbendazole, cobalamin supplementation if indicated and if there is still not a satisfactory improvement then a course of Prednisolone would then be indicated.



PATIENT

Georgia Greaney

SPECIES

Canine

BREED

German Shepherd

SEX

Spayed female

AGE

9 years

WEIGHT

68.2 lbs

INTERPRETED BY

Remo Lobetti, BVSc,
MMedVet (Med),
PhD, Dipl. ECVIM

IMAGING PERFORMED BY

Grace Jayne CVT

HOSPITAL NAME

Ark Animal Homecare

REFERRING VET

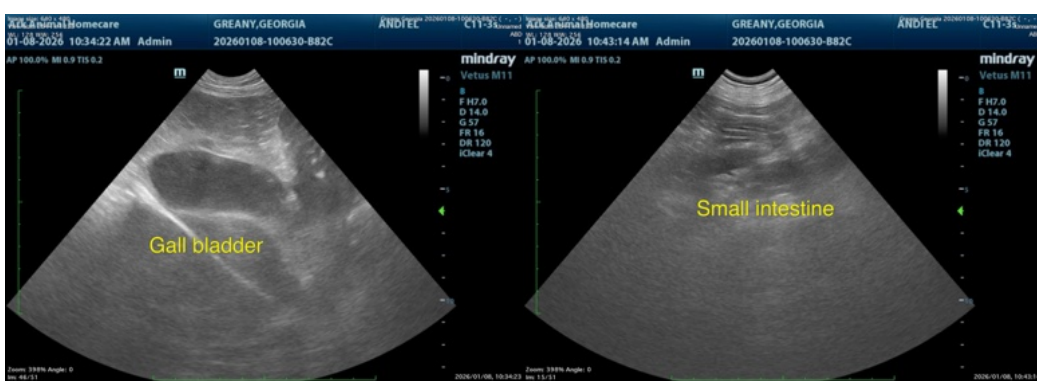
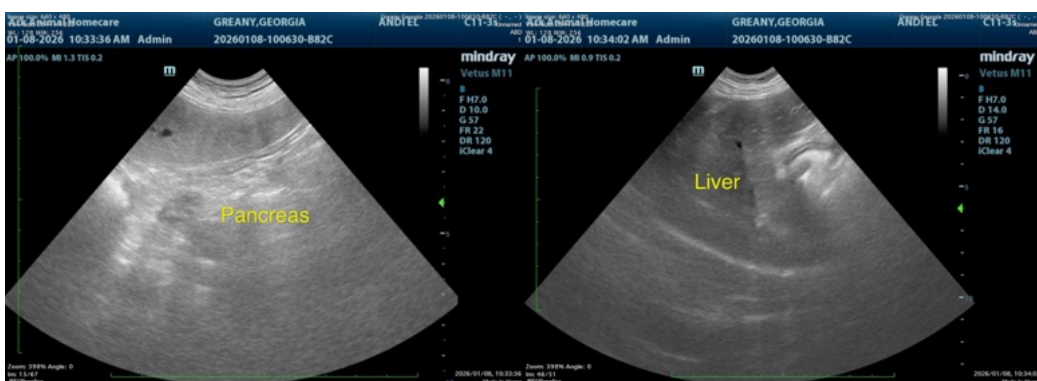
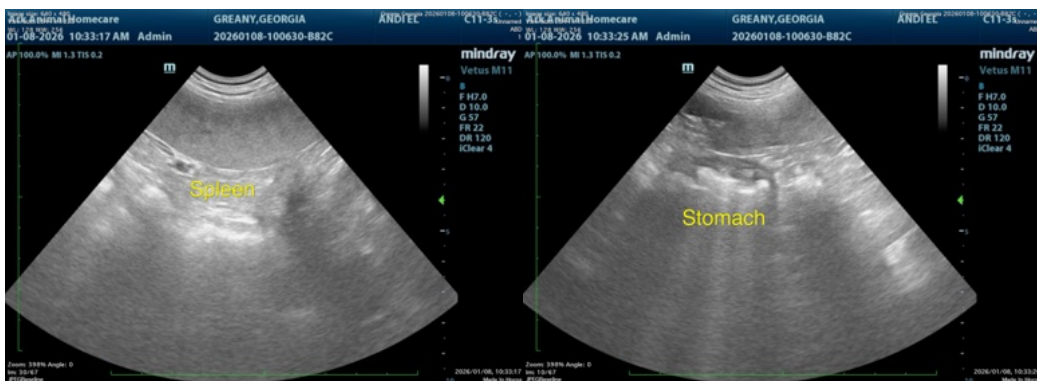
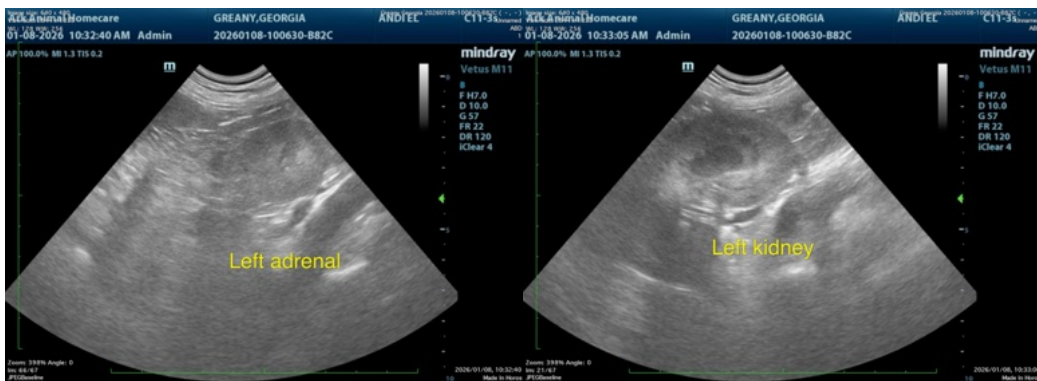
Dr. Dingle

INVOICE

69936

DATE

1/8/26





PATIENT

Georgia Greaney

SPECIES

Canine

BREED

German Shepherd

SEX

Spayed female

AGE

9 years

WEIGHT

68.2 lbs

INTERPRETED BY

Remo Lobetti, BVSc,
MMedVet (Med),
PhD, Dipl. ECVIM

IMAGING PERFORMED BY

Grace Jayne CVT

HOSPITAL NAME

Ark Animal Homecare

REFERRING VET

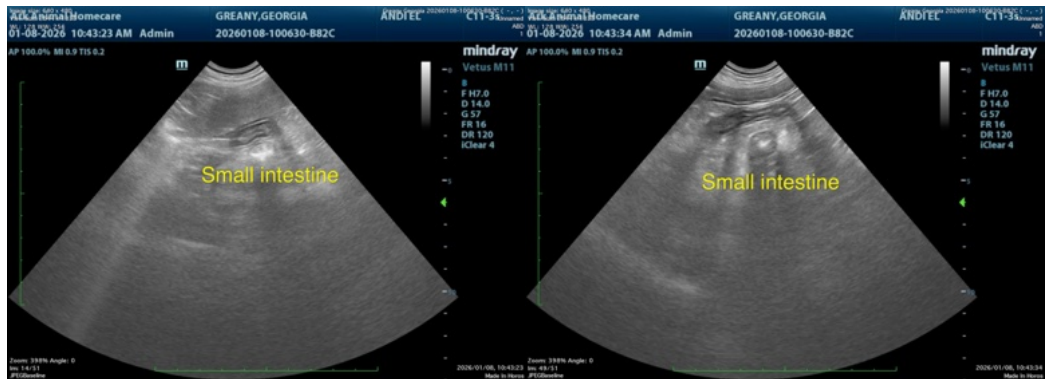Dr. Dingle

INVOICE

69936

DATE

1/8/26



The information and recommendations provided are based on the images presented by the referring veterinarian/sonographer. No evaluation can be communicated regarding pathology that was not visible in the image/video clips provided.

Thank you for this referral. If the clinical or image interpretation does not parallel your findings or if I can be of any further assistance please contact me.

Remo Lobetti, BVSc, MMedVet (Med), PhD, Dipl. ECVIM (Internal Medicine)

info@sonopath.com