



PATIENT

Hank Walis

SPECIES

Canine

BREED

Cattle Dog

SEX

Neutered male

AGE

9 years

WEIGHT

55 lbs

INTERPRETED BY

Remo Lobetti, BVSc,
MMedVet (Med),
PhD, Dipl. ECVIM

IMAGING PERFORMED BY

M Santiago

HOSPITAL NAME

Alison AH

REFERRING VET

Dr. Klein

INVOICE

69933

DATE

1/7/26

PRESENTING CLINICAL SIGNS

History: Pt is presented for a 3 month post surgery ultrasound for a jejunum mass removal. Pt is doing well as per O since procedure. No C/S/V/D. Normal energy. Normal appetite. Please use attached radiographs for reference.

ULTRASONOGRAPHIC EXAMINATION OF THE ABDOMEN

Urinary System

The urinary bladder is full with a normal thickness and smooth appearance of the wall. Normal anechoic urine with no sediment or uroliths evident.

Normal appearance of the trigone area, proximal urethra, and iliac blood vessels.

Normal appearance and size of the iliac lymph nodes. Ureters not visualized, which can be considered a normal finding.

Normal renal size (left measured 5.5 cm, right measured 5.2 cm), architecture, echogenic appearance, cortico-medullary differentiation, which maintains a 1:3 cortex to medulla ratio, pelvis, and capsule. No infarcts, mineralization or renoliths evident.

The prostate is small and hypoechogenic.

Adrenal Glands

The left adrenal gland was not clearly visualized, but appears to be of normal shape, echogenic appearance and size. The right adrenal gland was not visualized.

Spleen

Normal size and echogenic appearance. Smooth homogenous parenchyma and regular curvilinear capsule. Normal volume of the splenic vasculature without any overt congestion or thrombosis evident. No inflammatory, neoplastic, infarction, or infiltrative changes evident. The spleen measured 2.1 cm in width.

Liver

Normal size, echogenic appearance, portal markings, and regular curvilinear capsule. No nodules or masses evident. Normal appearance of the hepatic and portal vasculature.

Gallbladder

The gallbladder is small containing normal anechoic bile. Normal thickness and echogenic appearance of the wall. Normal size and appearance of the cystic and common bile duct.



PATIENT

Hank Walis

SPECIES

Canine

BREED

Cattle Dog

SEX

Neutered male

AGE

9 years

WEIGHT

55 lbs

INTERPRETED BY

Remo Lobetti, BVSc,
MMedVet (Med),
PhD, Dipl. ECVIM

IMAGING PERFORMED BY

M Santiago

HOSPITAL NAME

Alison AH

REFERRING VET

Dr. Klein

INVOICE

69933

DATE

1/7/26

Gastrointestinal

Normal appearance of the stomach, duodenum, small intestine, ileo-cecal junction, and colon with no loss of layering, 1:3 muscularis to mucosa ratio, normal wall thickness and peristaltic activity, and no distension of the lumen.

Pancreas

The visible sections of the pancreas are of normal size and echogenic appearance with a regular capsule. Normal echogenic appearance of the mesentery and fat surrounding the pancreas.

Free Abdomen

Normal mesenteric lymph nodes.

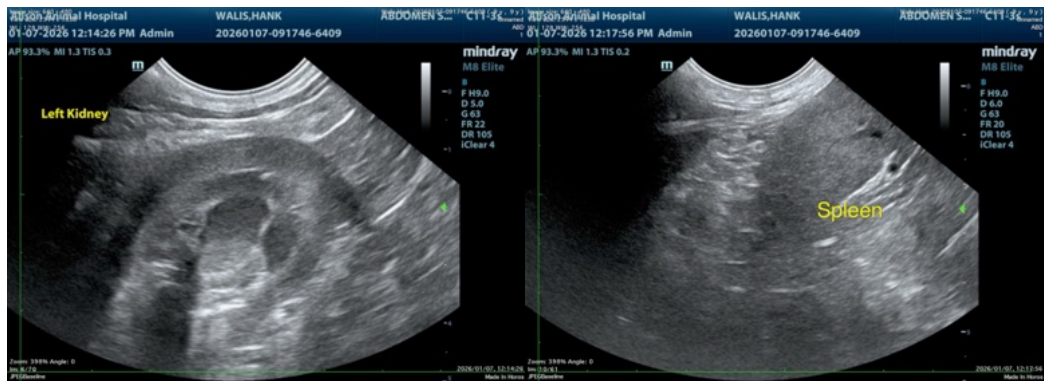
No ascites evident.

ULTRASONOGRAPHIC FINDINGS

- Normal ultrasound examination of the abdomen.

INTERPRETATION OF THE FINDINGS & FURTHER RECOMMENDATIONS

On this ultrasound there is no obvious evidence of neoplastic disease.





PATIENT

Hank Walis

SPECIES

Canine

BREED

Cattle Dog

SEX

Neutered male

AGE

9 years

WEIGHT

55 lbs

INTERPRETED BY

Remo Lobetti, BVSc,
MMedVet (Med),
PhD, Dipl. ECVIM

IMAGING PERFORMED BY

M Santiago

HOSPITAL NAME

Alison AH

REFERRING VET

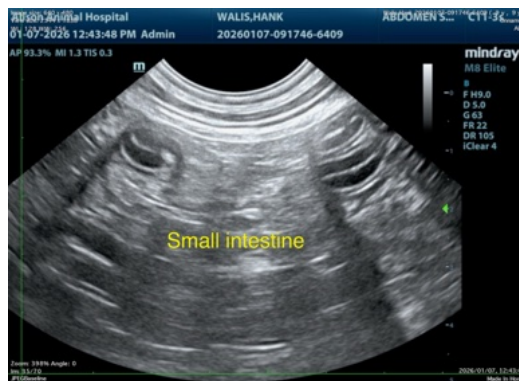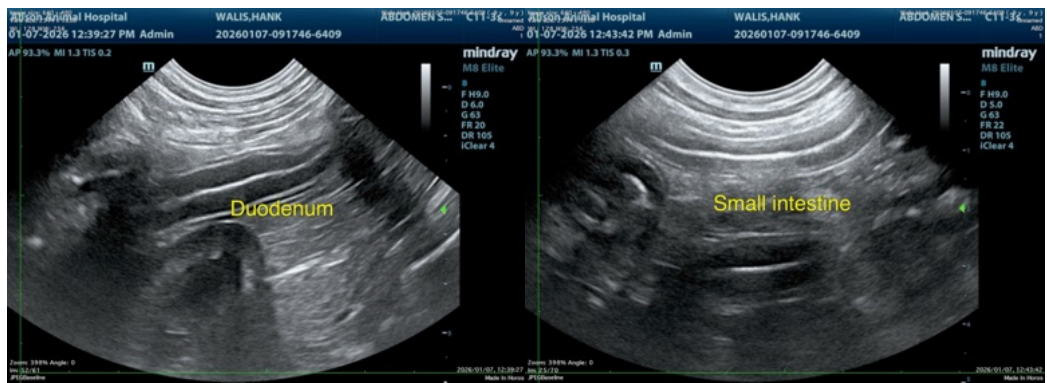
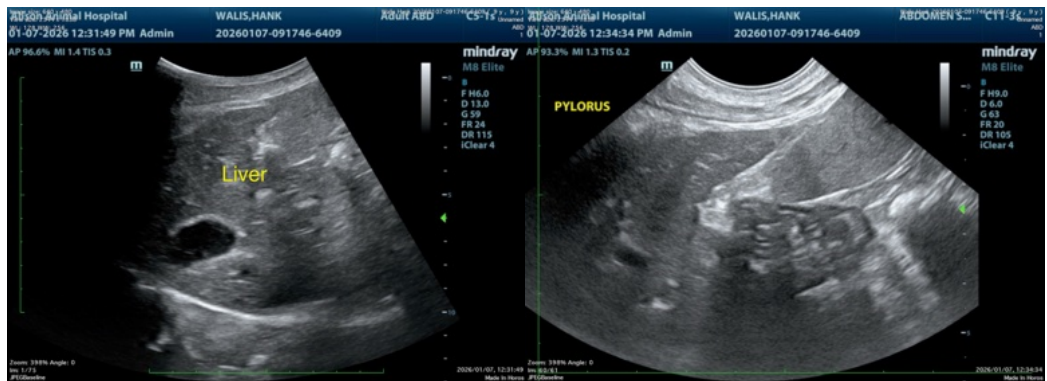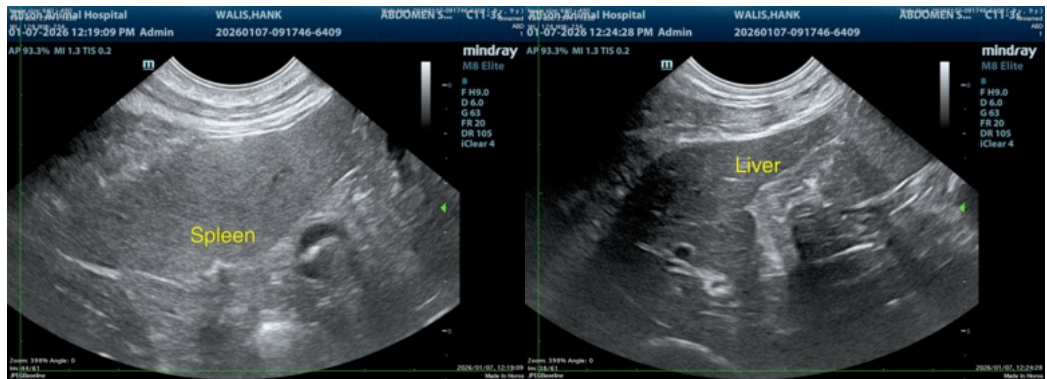Dr. Klein

INVOICE

69933

DATE

1/7/26





PATIENT

Hank Walis

SPECIES

Canine

BREED

Cattle Dog

SEX

Neutered male

AGE

9 years

WEIGHT

55 lbs

INTERPRETED BY

Remo Lobetti, BVSc,
MMedVet (Med),
PhD, Dipl. ECVIM

IMAGING PERFORMED BY

M Santiago

HOSPITAL NAME

Alison AH

REFERRING VET

Dr. Klein

INVOICE

69933

DATE

1/7/26

The information and recommendations provided are based on the images presented by the referring veterinarian/sonographer. No evaluation can be communicated regarding pathology that was not visible in the image/video clips provided.

Thank you for this referral. If the clinical or image interpretation does not parallel your findings or if I can be of any further assistance please contact me.

Remo Lobetti, BVSc, MMedVet (Med), PhD, Dipl. ECVIM (Internal Medicine)

info@sonopath.com