



PATIENT

Puppy Girl Santos

SPECIES

Canine

BREED

Chihuahua mix

SEX

Spayed female

AGE

13 years

WEIGHT

7.2 kg

INTERPRETED BY

Remo Lobetti, BVSc,
MMedVet (Med),
PhD, Dipl. ECVIM

IMAGING PERFORMED BY

Tiffany Moore DVM

HOSPITAL NAME

Lone Mountain AH

REFERRING VET

Dr. Moore

INVOICE

69894

DATE

1/6/26

PRESENTING CLINICAL SIGNS

History: presented for vomiting - been going on for a few days. O noted alot of flatulence and burping from P. history of splenomegaly

Abnormal PE/Chem/CBC/UA Results: has a grade 4 heart murmur - not on medications for that. ALP 212 WBC 17.2 NEU 13.49 HCT 40.1 - trending lower over the past few blood samples pt 16.5 appt 110 - extended splenic lesions noted upon AFAST

ULTRASONOGRAPHIC EXAMINATION OF THE ABDOMEN

Urinary System

The urinary bladder is full with a normal thickness and smooth appearance of the wall. Normal anechoic urine with no sediment or uroliths evident.

Normal appearance of the trigone area, proximal urethra, and iliac blood vessels.

Normal appearance and size of the iliac lymph nodes. Ureters not visualized, which can be considered a normal finding.

Normal renal size (left measured 4.7 cm, right measured 4.6 cm), architecture, echogenic appearance, cortico-medullary differentiation, which maintains a 1:3 cortex to medulla ratio, pelvis, and capsule. No infarcts, mineralization or renoliths evident.

Adrenal Glands

Normal shape, echogenic appearance, size, position, and appearance of the visible peri-adrenal vasculature. Left adrenal gland measured 0.52 cm in width. The right adrenal gland measured 2.6 cm in length x 0.97 cm in width.

Spleen

The spleen was diffusely enlarged and measured 2.3 cm in width maintaining a normal echogenic appearance, smooth homogenous parenchyma and a regular curvilinear capsule. Multiple, small, diffuse, hypoechoic parenchymal nodules are noted. Normal volume of the splenic vasculature without any overt congestion or thrombosis evident.

Liver

Normal size, echogenic appearance, portal markings, and regular curvilinear capsule. No nodules or masses evident. Normal appearance of the hepatic and portal vasculature.



PATIENT

Puppy Girl Santos

SPECIES

Canine

BREED

Chihuahua mix

SEX

Spayed female

AGE

13 years

WEIGHT

7.2 kg

INTERPRETED BY

Remo Lobetti, BVSc,
MMedVet (Med),
PhD, Dipl. ECVIM

IMAGING PERFORMED BY

Tiffany Moore DVM

HOSPITAL NAME

Lone Mountain AH

REFERRING VET

Dr. Moore

INVOICE

69894

DATE

1/6/26

Gallbladder

The gallbladder is full containing normal anechoic bile. Normal thickness and echogenic appearance of the wall. Normal size and appearance of the cystic and common bile duct.

Gastrointestinal

Normal appearance of the stomach, duodenum, small intestine, ileo-cecal junction, and colon with no loss of layering, 1:3 muscularis to mucosa ratio, normal wall thickness and peristaltic activity, and no distension of the lumen.

Pancreas

The visible sections of the pancreas are of normal size and echogenic appearance with a regular capsule. Normal echogenic appearance of the mesentery and fat surrounding the pancreas.

Free Abdomen

Normal mesenteric lymph nodes.

No ascites evident.

ULTRASONOGRAPHIC FINDINGS

- Splenomegaly.
- Splenic nodules.

INTERPRETATION OF THE FINDINGS & FURTHER RECOMMENDATIONS

Etiologies for the splenomegaly would be reactive hyperplasia, severe extramedullary hemopoiesis, lymphadenitis and infiltrative neoplasia.

On this ultrasound there is no obvious etiology for the acute vomiting with the most likely diagnosis being acute, non-specific gastritis such as dietary indiscretion, toxins and viral.

Further assessment would be FNA cytology of the spleen.

Specific therapy would be dependent on an etiological diagnosis.



PATIENT

Puppy Girl Santos

SPECIES

Canine

BREED

Chihuahua mix

SEX

Spayed female

AGE

13 years

WEIGHT

7.2 kg

INTERPRETED BY

Remo Lobetti, BVSc,
MMedVet (Med),
PhD, Dipl. ECVIM

IMAGING PERFORMED BY

Tiffany Moore DVM

HOSPITAL NAME

Lone Mountain AH

REFERRING VET

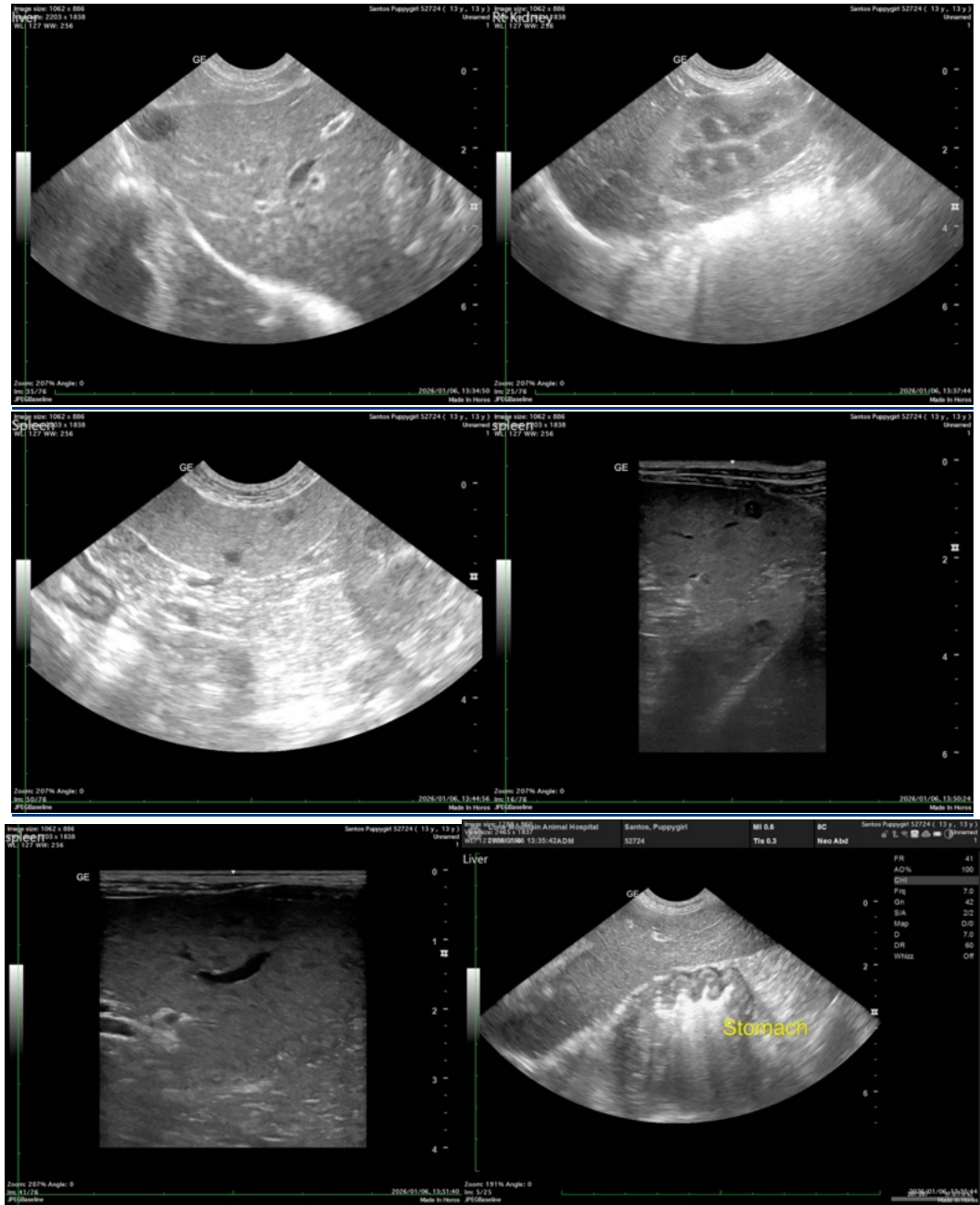
Dr. Moore

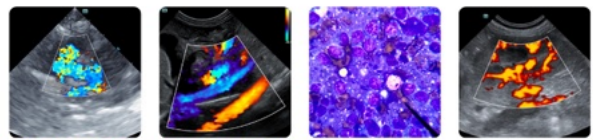
INVOICE

69894

DATE

1/6/26





PATIENT

Puppy Girl Santos

SPECIES

Canine

BREED

Chihuahua mix

SEX

Spayed female

AGE

13 years

WEIGHT

7.2 kg

INTERPRETED BY

Remo Lobetti, BVSc, MMedVet (Med), PhD, Dipl. ECVIM

IMAGING PERFORMED BY

Tiffany Moore DVM

HOSPITAL NAME

Lone Mountian AH

REFERRING VET

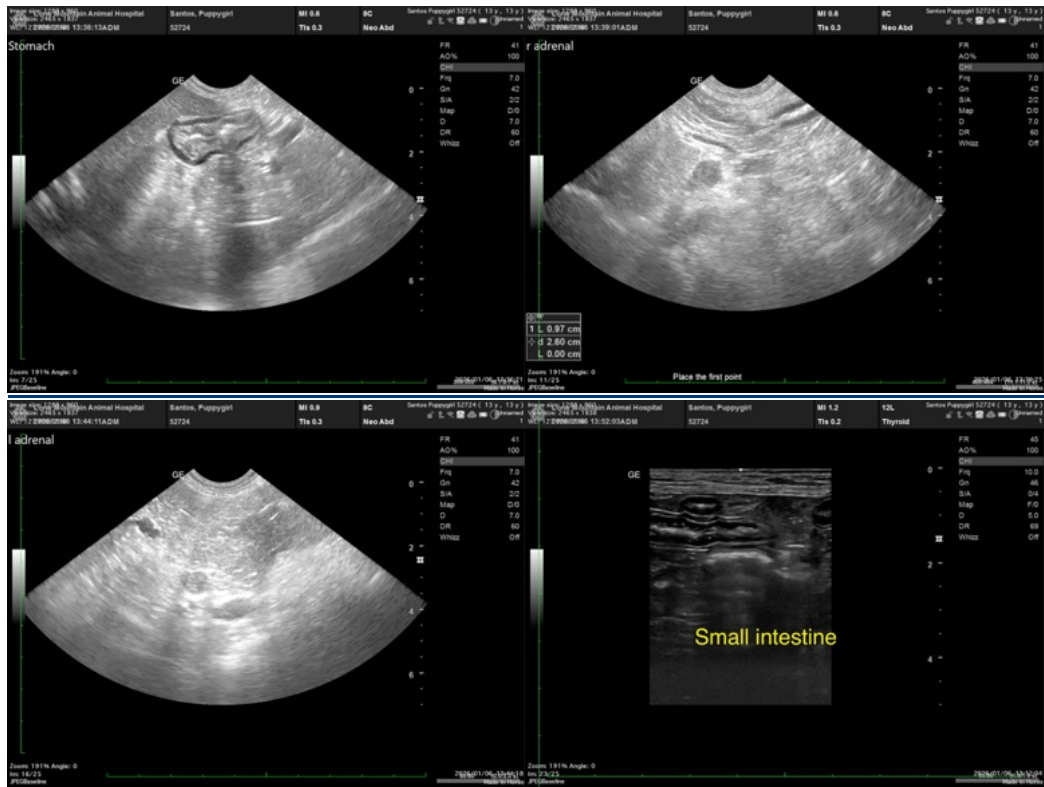
Dr. Moore

INVOICE

69894

DATE

1/6/26



The information and recommendations provided are based on the images presented by the referring veterinarian/sonographer. No evaluation can be communicated regarding pathology that was not visible in the image/video clips provided.

Thank you for this referral. If the clinical or image interpretation does not parallel your findings or if I can be of any further assistance please contact me.

Remo Lobetti, BVSc, MMedVet (Med), PhD, Dipl. ECVIM (Internal Medicine)

info@sonopath.com