



PATIENT

Cookie Makris

SPECIES

Canine

BREED

Havanese

SEX

Spayed female

AGE

11 years

WEIGHT

12.4 lbs

INTERPRETED BY

Remo Lobetti, BVSc,
MMedVet (Med),
PhD, Dipl. ECVIM

IMAGING PERFORMED BY

Dr. Ohad Barnea

HOSPITAL NAME

Tenaflly VC

REFERRING VET

Dr. Barnea

INVOICE

69881

DATE

1/6/26

PRESENTING CLINICAL SIGNS

History: FOLLOW UP US ON URSODIOL AND L/D DIET

ULTRASONOGRAPHIC EXAMINATION OF THE ABDOMEN

Liver

Normal size with a diffuse increased echogenic and coarse appearance, prominent portal markings, and regular curvilinear capsule. No nodules or masses evident. Normal appearance of the hepatic and portal vasculature.

Gallbladder

The gallbladder is full containing a large amount of adhered and non-adhered hyperechogenic sediment with the adhered sediment warranted in an early stellate pattern.

ULTRASONOGRAPHIC FINDINGS

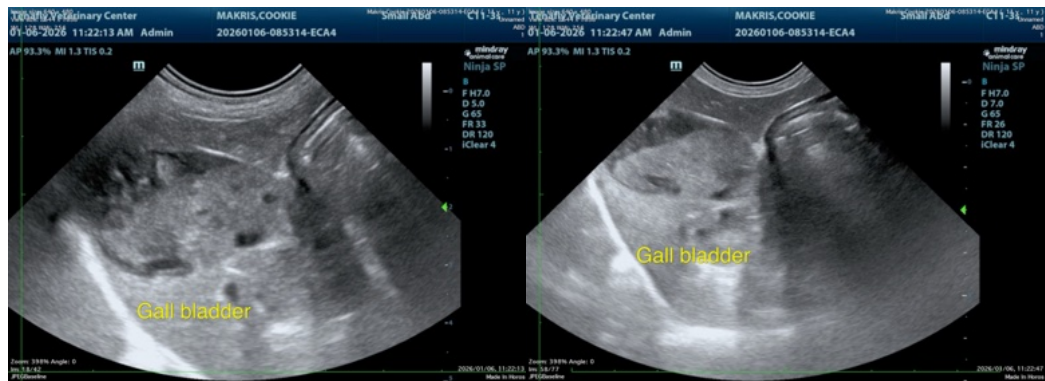
- Hepatopathy.
- Mucocele.

INTERPRETATION OF THE FINDINGS & FURTHER RECOMMENDATIONS

Etiologies for the hepatopathy would be reactive hyperplasia, early nodular hyperplasia, vacuolar and metabolic with infiltrative neoplasia and hepatitis an unlikely differential diagnosis.

Further assessment would be FNA cytology of the liver. However, a tru cut or wedge biopsy may be required for a final etiological diagnosis.

Specific therapy would be dependent on an etiological diagnosis. Symptomatic management would be to continue with the current therapy. Cholecystectomy should be considered.





PATIENT

Cookie Makris

SPECIES

Canine

BREED

Havanese

SEX

Spayed female

AGE

11 years

WEIGHT

12.4 lbs

INTERPRETED BY

Remo Lobetti, BVSc,
MMedVet (Med),
PhD, Dipl. ECVIM

IMAGING PERFORMED BY

Dr. Ohad Barnea

HOSPITAL NAME

Tenaflly VC

REFERRING VET

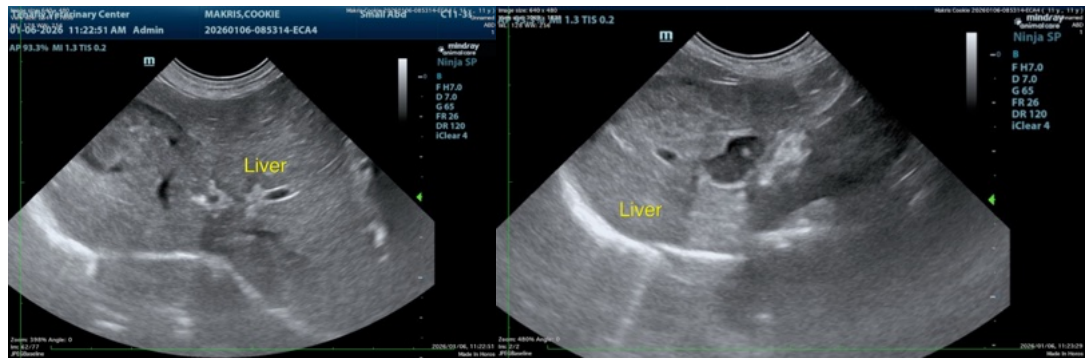
Dr. Barnea

INVOICE

69881

DATE

1/6/26



The information and recommendations provided are based on the images presented by the referring veterinarian/sonographer. No evaluation can be communicated regarding pathology that was not visible in the image/video clips provided.

Thank you for this referral. If the clinical or image interpretation does not parallel your findings or if I can be of any further assistance please contact me.

Remo Lobetti, BVSc, MMedVet (Med), PhD, Dipl. ECVIM (Internal Medicine)

info@sonopath.com