



PATIENT

Lucy LaFleur

SPECIES

Feline

BREED

Domestic Shorthair

SEX

Spayed female

AGE

12 years

WEIGHT

5.5 lbs

INTERPRETED BY

Remo Lobetti, BVSc,
MMedVet (Med),
PhD, Dipl. ECVIM

IMAGING PERFORMED BY

Dr. Peter Langer

HOSPITAL NAME

North Hampton AH

REFERRING VET

Dr. Solomon

INVOICE

69807

DATE

1/5/26

PRESENTING CLINICAL SIGNS

History: Epistaxis, weight loss, leukocytosis characterized by a neutrophilia and monocytosis.
Abnormal PE/Chem/CBC/UA Results: CBC: NEU 34, 196 MONO 1,648 CHEM: unremarkable

ULTRASONOGRAPHIC EXAMINATION OF THE ABDOMEN

Urinary System

The urinary bladder is full with a normal thickness and smooth appearance of the wall. A scant amount of floating, hyperechogenic sediment.

Normal appearance of the trigone area, proximal urethra, and iliac blood vessels.

Normal appearance and size of the iliac lymph nodes. Ureters not visualized, which can be considered a normal finding.

Normal renal size (left measured 4.0 cm, right measured 4.5 cm), architecture, echogenic appearance, cortico-medullary differentiation, which maintains a 1:3 cortex to medulla ratio, pelvis, and capsule. No infarcts, mineralization or renoliths evident. Normal color flow pattern is noted in both kidneys.

Adrenal Glands

Normal shape, echogenic appearance, size, position, and appearance of the visible peri-adrenal vasculature. Left adrenal gland measured 0.34 cm and 0.38 cm in width. The right adrenal gland measured 0.33 cm and 0.32 cm in width.

Spleen

Normal size and echogenic appearance. Smooth homogenous parenchyma and regular curvilinear capsule. Normal volume of the splenic vasculature without any overt congestion or thrombosis evident. No inflammatory, neoplastic, infarction, or infiltrative changes evident. The spleen measured 0.5 cm in width.

Liver

Normal size, echogenic appearance, portal markings, and regular curvilinear capsule. No nodules or masses evident. Normal appearance of the hepatic and portal vasculature.

Gallbladder

The gallbladder is full containing normal anechoic bile. Normal thickness and echogenic appearance of the wall. Normal size and appearance of the cystic and common bile duct.



PATIENT

Lucy LaFleur

SPECIES

Feline

BREED

Domestic Shorthair

SEX

Spayed female

AGE

12 years

WEIGHT

5.5 lbs

INTERPRETED BY

Remo Lobetti, BVSc,
MMedVet (Med),
PhD, Dipl. ECVIM

IMAGING PERFORMED BY

Dr. Peter Langer

HOSPITAL NAME

North Hampton AH

REFERRING VET

Dr. Solomon

INVOICE

69807

DATE

1/5/26

Gastrointestinal

Normal appearance of the stomach, duodenum, small intestine, ileo-cecal junction, and colon with no loss of layering, 1:3 muscularis to mucosa ratio, normal wall thickness and peristaltic activity, and no distension of the lumen.

Pancreas

The visible sections of the pancreas are of normal size and echogenic appearance with a regular capsule. Normal echogenic appearance of the mesentery and fat surrounding the pancreas.

Free Abdomen

Enlarged mesenteric lymph nodes measuring up to 0.8 x 1.7 cm in size maintaining normal shape and echogenic appearance.

No ascites evident.

ULTRASONOGRAPHIC FINDINGS

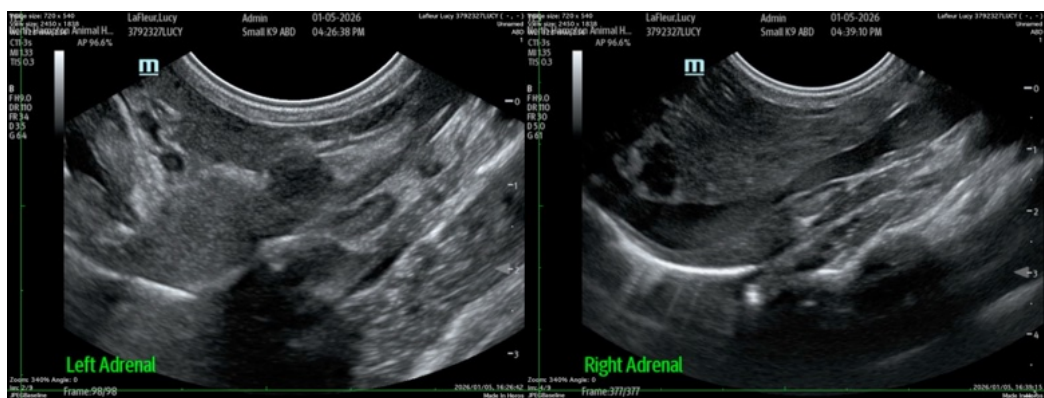
- Mesenteric lymphadenomegaly.

INTERPRETATION OF THE FINDINGS & FURTHER RECOMMENDATIONS

Etiologies for the mesenteric lymphadenomegaly would be reactive hyperplasia, lymphadenitis and infiltrative neoplasia and reactive neoplasia.

Further assessment would be three view thoracic radiographs and FNA cytology of the mesenteric lymph nodes.

Specific therapy would be dependent on an etiological diagnosis.





PATIENT

Lucy LaFleur

SPECIES

Feline

BREED

Domestic Shorthair

SEX

Spayed female

AGE

12 years

WEIGHT

5.5 lbs

INTERPRETED BY

Remo Lobetti, BVSc,
MMedVet (Med),
PhD, Dipl. ECVIM

IMAGING PERFORMED BY

Dr. Peter Langer

HOSPITAL NAME

North Hampton AH

REFERRING VET

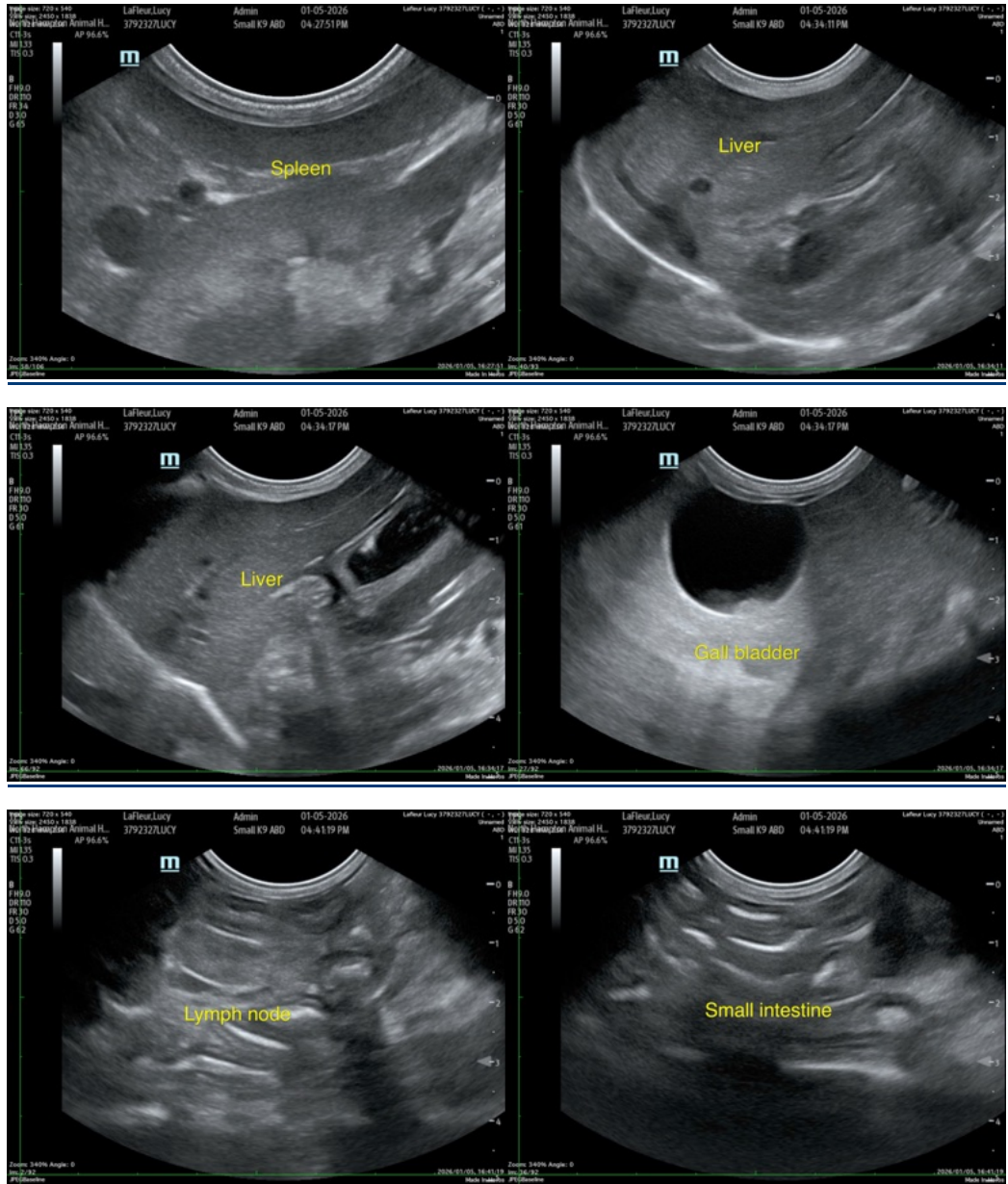
Dr. Solomon

INVOICE

69807

DATE

1/5/26





PATIENT

Lucy LaFleur

SPECIES

Feline

BREED

Domestic Shorthair

SEX

Spayed female

AGE

12 years

WEIGHT

5.5 lbs

INTERPRETED BY

Remo Lobetti, BVSc,
MMedVet (Med),
PhD, Dipl. ECVIM

IMAGING PERFORMED BY

Dr. Peter Langer

HOSPITAL NAME

North Hampton AH

REFERRING VET

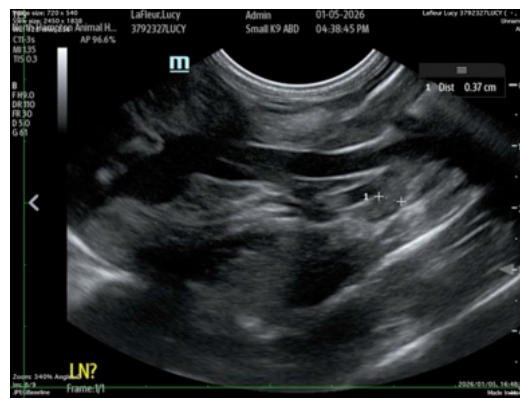
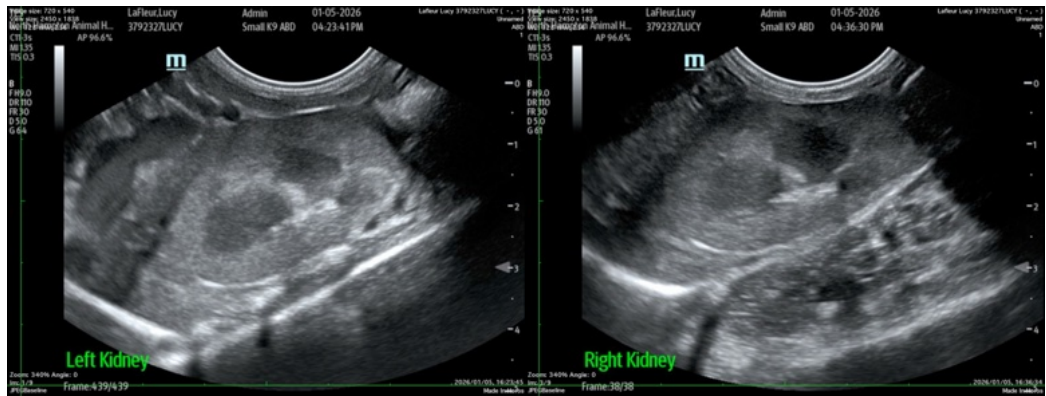
Dr. Solomon

INVOICE

69807

DATE

1/5/26



The information and recommendations provided are based on the images presented by the referring veterinarian/sonographer. No evaluation can be communicated regarding pathology that was not visible in the image/video clips provided.

Thank you for this referral. If the clinical or image interpretation does not parallel your findings or if I can be of any further assistance please contact me.

Remo Lobetti, BVSc, MMedVet (Med), PhD, Dipl. ECVIM (Internal Medicine)

info@sonopath.com