



PATIENT

Merry Bedell

SPECIES

Canine

BREED

English Bulldog

SEX

Female

AGE

9 years

WEIGHT

40.5 lbs

INTERPRETED BY

Remo Lobetti, BVSc,
MMedVet (Med),
PhD, Dipl. ECVIM

IMAGING PERFORMED BY

Jessica Garrison

HOSPITAL NAME

Montville Animal
Hospital

REFERRING VET

Dr. Kara Schubert

INVOICE

11210

DATE

1/30/2026

PRESENTING CLINICAL SIGNS

- Pre-op screening for mast cell tumor removal.

ULTRASONOGRAPHIC EXAMINATION OF THE ABDOMEN

Urinary System

Small urinary bladder with a normal thickness and smooth appearance of the wall. Normal anechoic urine with no sediment or uroliths evident.

Normal appearance of the trigone area, proximal urethra, and iliac blood vessels.

Normal appearance and size of the iliac lymph nodes. Ureters not visualized, which can be considered a normal finding.

Normal renal size, architecture, echogenic appearance, cortico-medullary differentiation, which maintains a 1:3 cortex to medulla ratio, pelvis, and capsule. No infarcts, mineralization or renoliths evident. Left kidney measures 4.8 cm, and the right kidney 5.1 cm.

Adrenal Glands

Normal shape, echogenic appearance, size, position, and appearance of the visible peri-adrenal vasculature. Left adrenal measures 0.62 cm in width, and the right adrenal measures 0.43 cm in width.

Spleen

Normal size and echogenic appearance. Smooth homogenous parenchyma and regular curvilinear capsule. Normal volume of the splenic vasculature without any overt congestion or thrombosis evident. No inflammatory, neoplastic, infarction, or infiltrative changes evident. The spleen measures 1.7 cm in width.

Liver

Normal size, echogenic appearance, portal markings, and regular curvilinear capsule. No nodules or masses evident. Normal appearance of the hepatic and portal vasculature.

Gallbladder

Small containing normal anechoic bile. Normal thickness and echogenic appearance of the wall. Normal size and appearance of the cystic and common bile duct.

Gastrointestinal

Normal appearance of the stomach, duodenum, small intestine, ileo-cecal junction, and colon with no loss of layering, 1:3 muscularis to mucosa ratio, normal wall thickness and peristaltic activity, and no distension of the lumen.

Pancreas

Normal size and echogenic appearance. Regular capsule. Normal echogenic appearance of the mesentery and fat surrounding the pancreas.

Free Abdomen



PATIENT

Merry Bedell

SPECIES

Canine

BREED

English Bulldog

SEX

Female

AGE

9 years

WEIGHT

40.5 lbs

INTERPRETED BY

Remo Lobetti, BVSc,
MMedVet (Med),
PhD, Dipl. ECVIM

IMAGING PERFORMED BY

Jessica Garrison

HOSPITAL NAME

Montville Animal
Hospital

REFERRING VET

Dr. Kara Schubert

INVOICE

11210

DATE

1/30/2026

Normal mesenteric lymph nodes.

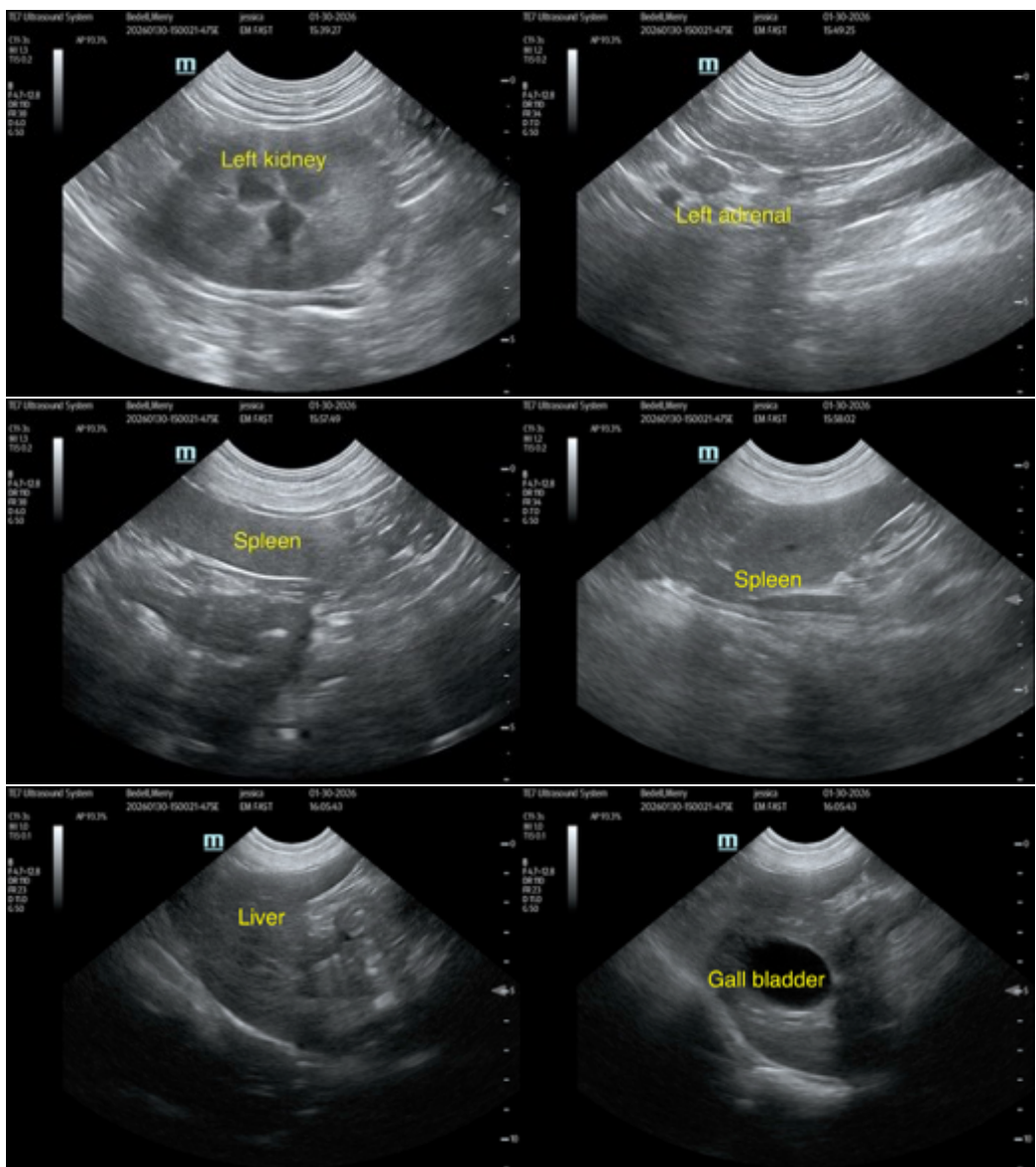
No ascites evident.

ULTRASONOGRAPHIC FINDINGS

- Normal ultrasound examination of the abdomen.

INTERPRETATION OF THE FINDINGS & FURTHER RECOMMENDATIONS

On this ultrasound, there's no obvious evidence of metastatic mast cell neoplasia. FNA cytology of the liver and spleen could be considered to complete the metastatic screen.





PATIENT

Merry Bedell

SPECIES

Canine

BREED

English Bulldog

SEX

Female

AGE

9 years

WEIGHT

40.5 lbs

INTERPRETED BY

Remo Lobetti, BVSc,
MMedVet (Med),
PhD, Dipl. ECVIM

IMAGING PERFORMED BY

Jessica Garrison

HOSPITAL NAME

Montville Animal
Hospital

REFERRING VET

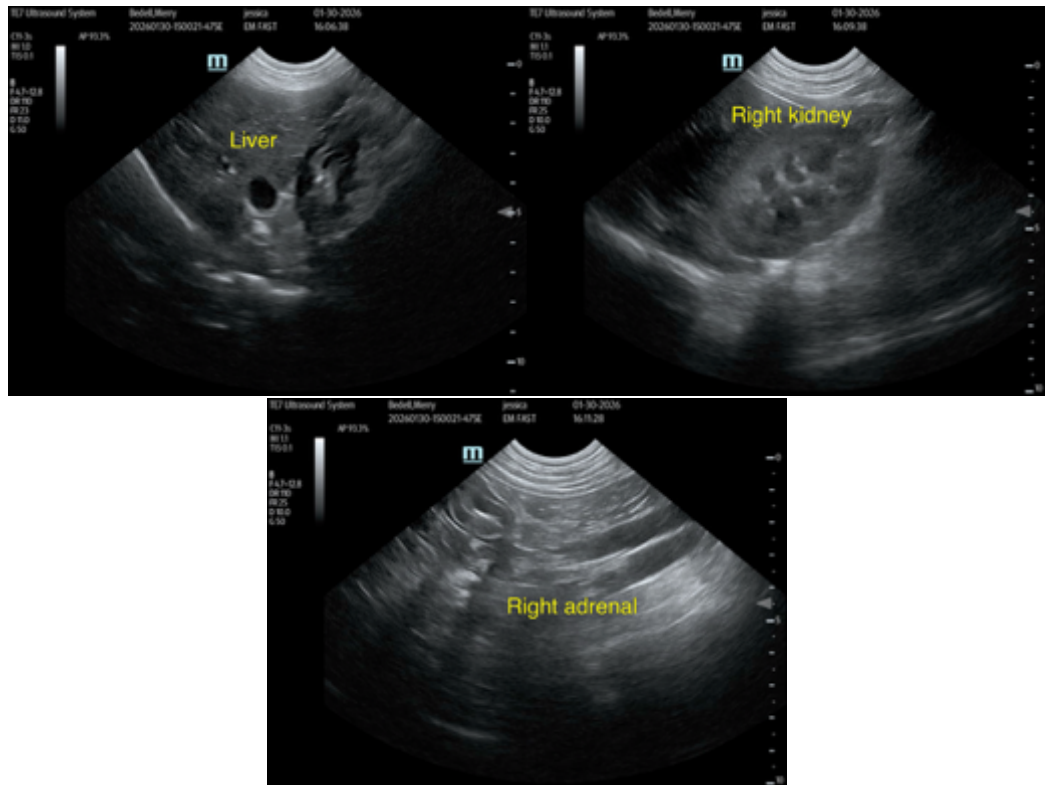
Dr. Kara Schubert

INVOICE

11210

DATE

1/30/2026



The information and recommendations provided are based on the images presented by the referring veterinarian. No evaluation can be communicated regarding pathology that was not visible in the image/video clips provided.

Thank you for this referral. If the clinical or image interpretation does not parallel your findings or if I can be of any further assistance, please contact me.

Remo Lobetti, BVSc, MMedVet (Med), PhD, Dipl. ECVIM (Internal Medicine)

info@sonopath.com