



PATIENT

Lindsey Lenihan

SPECIES

Feline

BREED

Domestic Shorthair

SEX

Spayed female

AGE

10 years

WEIGHT

3.37 lbs

INTERPRETED BY

Remo Lobetti, BVSc,
MMedVet (Med),
PhD, Dipl. ECVIM

IMAGING PERFORMED BY

Dr. Pascucci

HOSPITAL NAME

American AH

REFERRING VET

Dr. Arculli

INVOICE

71071

DATE

1/29/26

PRESENTING CLINICAL SIGNS

- weight loss, diarrhea- will come out as soon as she eats, vomiting
- ravenous about food but then doesn't finish it
- Amylase >36,000 Lipase 1740 HCT 30 TT4= normal

ULTRASONOGRAPHIC EXAMINATION OF THE ABDOMEN

Urinary System

The urinary bladder is full with a normal thickness and smooth appearance of the wall. Normal anechoic urine with no sediment or uroliths evident.

Normal appearance of the trigone area, proximal urethra, and iliac blood vessels.

Normal appearance and size of the iliac lymph nodes. Ureters not visualized, which can be considered a normal finding.

Normal renal size (left measured 2.8 cm, right measured 3.0 cm), architecture, echogenic appearance, cortico-medullary differentiation, which maintains a 1:3 cortex to medulla ratio, pelvis, and capsule. No infarcts, mineralization or renoliths evident. Normal color flow pattern is evident in both kidneys.

Adrenal Glands

The adrenal glands are not visualized.

Spleen

The spleen is not visualized.

Liver

The liver is enlarged with rounded edges, diffuse increased echogenic appearance, normal portal markings, and regular curvilinear capsule. Multiple, small cysts and hypoechogenic parenchymal nodules measuring up to 0.5 cm in size. No masses evident. Normal appearance of the hepatic and portal vasculature.

Gallbladder

The gallbladder is small containing normal anechoic bile. Normal thickness and echogenic appearance of the wall. Normal size and appearance of the cystic and common bile duct.



PATIENT

Lindsey Lenihan

SPECIES

Feline

BREED

Domestic Shorthair

SEX

Spayed female

AGE

10 years

WEIGHT

3.37 lbs

INTERPRETED BY

Remo Lobetti, BVSc,
MMedVet (Med),
PhD, Dipl. ECVIM

IMAGING PERFORMED BY

Dr. Pascucci

HOSPITAL NAME

American AH

REFERRING VET

Dr. Arculli

INVOICE

71071

DATE

1/29/26

Gastrointestinal

Normal appearance of the stomach, duodenum, small intestine, ileo-cecal junction, and colon with no loss of layering, 1:3 muscularis to mucosa ratio, normal wall thickness and peristaltic activity, and no distension of the lumen.

Pancreas

Normal size with a diffuse, hyperechogenic appearance and an irregular capsule. Hyperechogenic appearance of the mesentery and fat surrounding the pancreas.

Free Abdomen

Normal mesenteric lymph nodes.

A small amount of ascites present.

ULTRASONOGRAPHIC FINDINGS

- Nodular and cystic hepatopathy.
- Chronic pancreatitis versus pancreatic fibrosis.

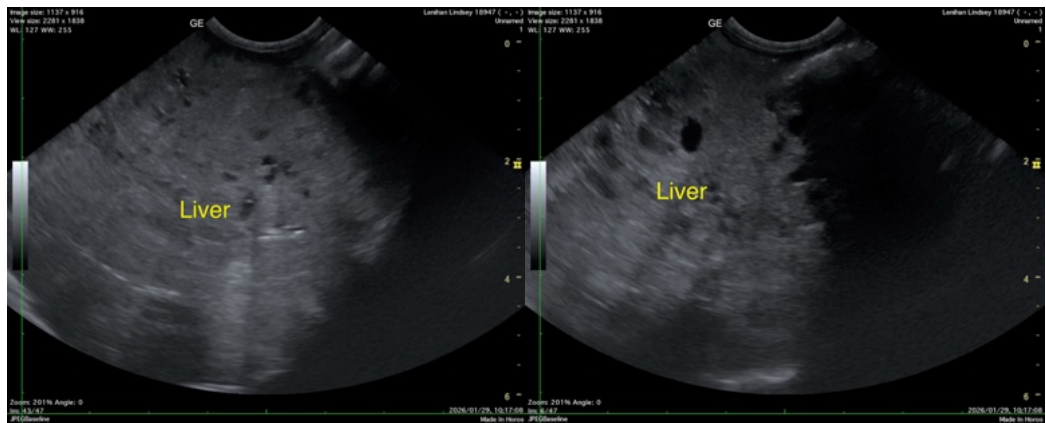INTERPRETATION OF THE FINDINGS & FURTHER RECOMMENDATIONS

Etiologies for the hepatopathy would be chronic hepatitis, granulomatous disease and possibly neoplasia.

Further assessment would be FPL/PSL and TLI assay and FNA cytology of the liver.

A tru cut or wedge biopsy of the liver may be required for a final etiological diagnosis.

Specific therapy would be dependent on an etiological diagnosis.





PATIENT

Lindsey Lenihan

SPECIES

Feline

BREED

Domestic Shorthair

SEX

Spayed female

AGE

10 years

WEIGHT

3.37 lbs

INTERPRETED BY

Remo Lobetti, BVSc,
MMedVet (Med),
PhD, Dipl. ECVIM

IMAGING PERFORMED BY

Dr. Pascucci

HOSPITAL NAME

American AH

REFERRING VET

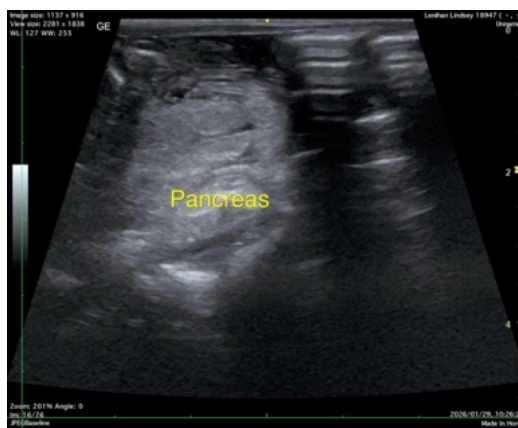
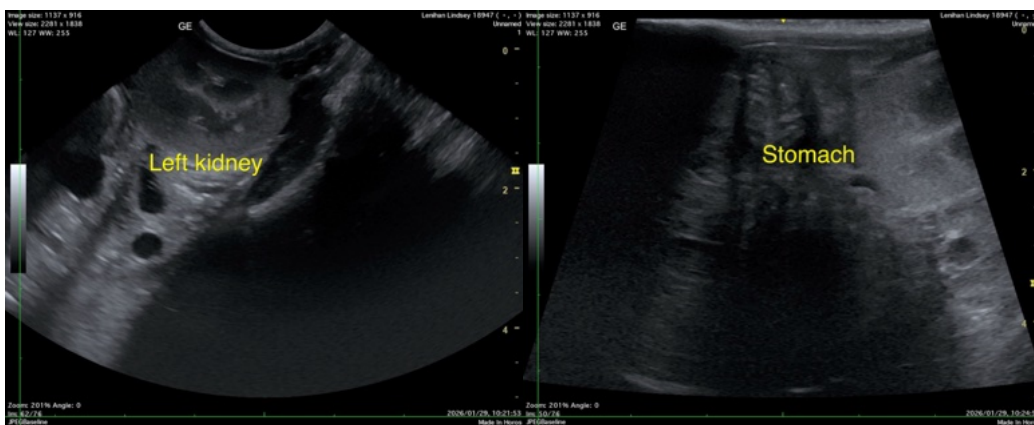
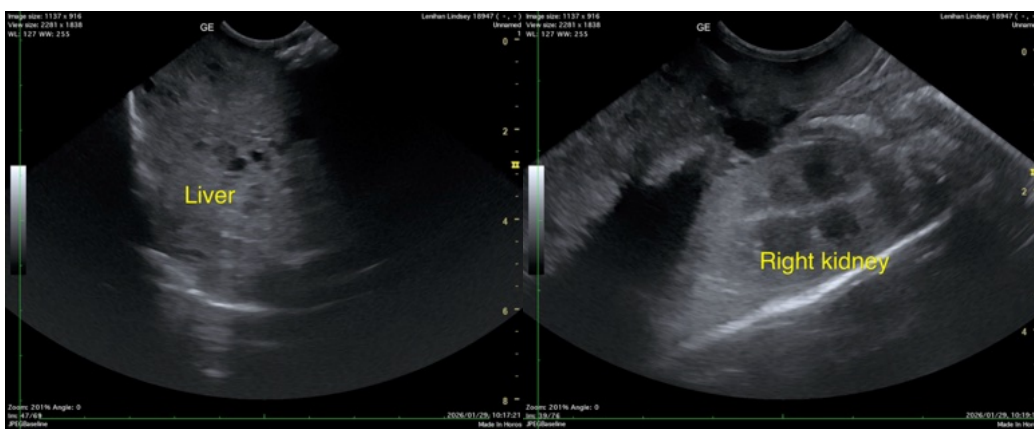
Dr. Arculli

INVOICE

71071

DATE

1/29/26



The information and recommendations provided are based on the images presented by the referring veterinarian/sonographer. No evaluation can be communicated regarding pathology that was not visible in the image/video clips provided.

Thank you for this referral. If the clinical or image interpretation does not parallel your findings or if I can be of any further assistance please contact me.

Remo Lobetti, BVSc, MMedVet (Med), PhD, Dipl. ECVIM (Internal Medicine)



PATIENT

info@sonopath.com

Lindsey Lenihan

SPECIES

Feline

BREED

Domestic Shorthair

SEX

Spayed female

AGE

10 years

WEIGHT

3.37 lbs

INTERPRETED BY

Remo Lobetti, BVSc,
MMedVet (Med),
PhD, Dipl. ECVIM

**IMAGING
PERFORMED BY**

Dr. Pascucci

HOSPITAL NAME

American AH

REFERRING VET

Dr. Arculli

INVOICE

71071

DATE

1/29/26