



PATIENT

Lily Rogers

SPECIES

Canine

BREED

Boston Terrier

SEX

Spayed female

AGE

13 years

WEIGHT

21.6 lbs

INTERPRETED BY

Remo Lobetti, BVSc,
MMedVet (Med),
PhD, Dipl. ECVIM

IMAGING PERFORMED BY

Dr. Julie Kang

HOSPITAL NAME

Sabino VC

REFERRING VET

Dr. Kang

INVOICE

71073

DATE

1/29/26

PRESENTING CLINICAL SIGNS

- Chronic progressive inappetence, lethargy, weight loss, diarrhea, vomiting that started mid-December. Treated for suspected pancreatitis based on labs/clinical signs with Panoquel x3d + symptomatic treatment on two occasions since mid-December with positive response during treatment, but not long-lasting improvement once treatment completed.
- 12/20/2026: CBC - PLT (513). Chem21 - Albumin (2.6), Globulins (3.7), PSL (144), IRIS stage 1. TT4 (<0.5). UA - 1.024, unremarkable otherwise. Accuplex - negx4. Fecal PCR - negx21. 12/31/2026: TT4 (0.9). 1/29/2026: PE - uncomfortable abdomen/guarding. Once sedated, large cranial to mid-abdominal mass palpated - suspected splenic origin.

ULTRASONOGRAPHIC EXAMINATION OF THE ABDOMEN

Urinary System

The urinary bladder is small with a normal thickness and smooth appearance of the wall. Normal anechoic urine with no sediment or uroliths evident.

Normal appearance of the trigone area, proximal urethra, and iliac blood vessels.

Normal appearance and size of the iliac lymph nodes. Ureters not visualized, which can be considered a normal finding.

Normal renal size (left measured 4.8 cm, right measured 4.9 cm), architecture, echogenic appearance, cortico-medullary differentiation, which maintains a 1:3 cortex to medulla ratio, pelvis, and capsule. No infarcts, mineralization or renoliths evident. Normal color flow pattern is evident in both kidneys.

Adrenal Glands

Normal shape, echogenic appearance, size, position, and appearance of the visible peri-adrenal vasculature. Left adrenal gland measured 1.85 cm in length x 0.56 cm and 0.77 cm in width. The right adrenal gland measured 2.3 cm in length x 0.61 cm and 0.55 cm in width.

Spleen

Two large splenic masses, one measuring 7.0 x 8.0 cm in size with a mottled echogenic and cystic appearance. The other mass measured 4.0 x 4.0 cm in size with a mottled echogenic appearance. The rest of the spleen is of normal size (1.7 cm) maintaining a normal, echogenic appearance, smooth homogenous parenchyma and a regular curvilinear capsule. Normal volume of the splenic vasculature without any overt congestion or thrombosis evident.

Liver

Normal size, echogenic appearance, portal markings, and regular curvilinear capsule. Few, hyperechogenic, parenchymal nodules measuring up to 1.7 x 2.2 cm in size. No masses evident. Normal appearance of the hepatic and portal vasculature.



PATIENT

Lily Rogers

SPECIES

Canine

BREED

Boston Terrier

SEX

Spayed female

AGE

13 years

WEIGHT

21.6 lbs

INTERPRETED BY

Remo Lobetti, BVSc,
MMedVet (Med),
PhD, Dipl. ECVIM

IMAGING PERFORMED BY

Dr. Julie Kang

HOSPITAL NAME

Sabino VC

REFERRING VET

Dr. Kang

INVOICE

71073

DATE

1/29/26

Gallbladder

The gallbladder is small containing normal anechoic bile. Normal thickness and echogenic appearance of the wall. Normal size and appearance of the cystic and common bile duct.

Gastrointestinal

Normal appearance of the stomach, duodenum, small intestine, ileo-cecal junction, and colon with no loss of layering, 1:3 muscularis to mucosa ratio, normal wall thickness and peristaltic activity, and no distension of the lumen.

Pancreas

The visible sections of the pancreas are of normal size and echogenic appearance with a regular capsule. Normal echogenic appearance of the mesentery and fat surrounding the pancreas.

Free Abdomen

Normal mesenteric lymph nodes.

No ascites evident.

ULTRASONOGRAPHIC FINDINGS

- Splenic masses.
- Hepatic nodules.

INTERPRETATION OF THE FINDINGS & FURTHER RECOMMENDATIONS

The most likely etiology for the splenic masses would be neoplasia with granulomatous disease and hematomas less likely differential diagnosis.

The most likely etiology for the hepatic nodules would be incidental nodular hyperplasia with neoplastic infiltration and granulomatous disease a less likely differential diagnosis.

Further assessment would be three view thoracic radiographs, echocardiography to evaluate the right atrium and right auricle and possibly FNA cytology of the splenic masses and hepatic nodules.

Splenectomy should be considered as it can be both diagnostic and therapeutic with further specific therapy dependent on an etiological diagnosis.



PATIENT

Lily Rogers

SPECIES

Canine

BREED

Boston Terrier

SEX

Spayed female

AGE

13 years

WEIGHT

21.6 lbs

INTERPRETED BY

Remo Lobetti, BVSc,
MMedVet (Med),
PhD, Dipl. ECVIM

IMAGING PERFORMED BY

Dr. Julie Kang

HOSPITAL NAME

Sabino VC

REFERRING VET

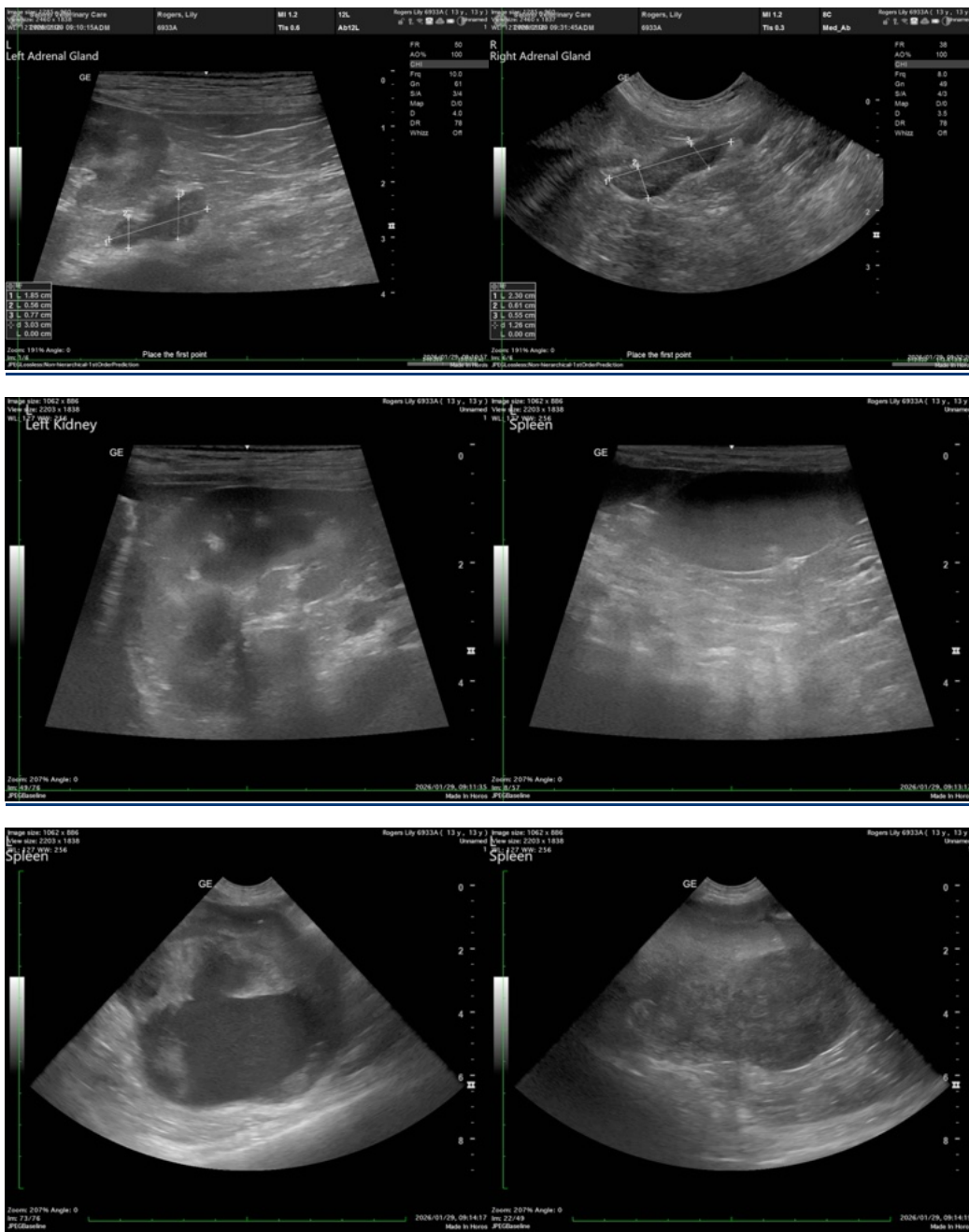
Dr. Kang

INVOICE

71073

DATE

1/29/26





PATIENT

Lily Rogers

SPECIES

Canine

BREED

Boston Terrier

SEX

Spayed female

AGE

13 years

WEIGHT

21.6 lbs

INTERPRETED BY

Remo Lobetti, BVSc,
MMedVet (Med),
PhD, Dipl. ECVIM

IMAGING PERFORMED BY

Dr. Julie Kang

HOSPITAL NAME

Sabino VC

REFERRING VET

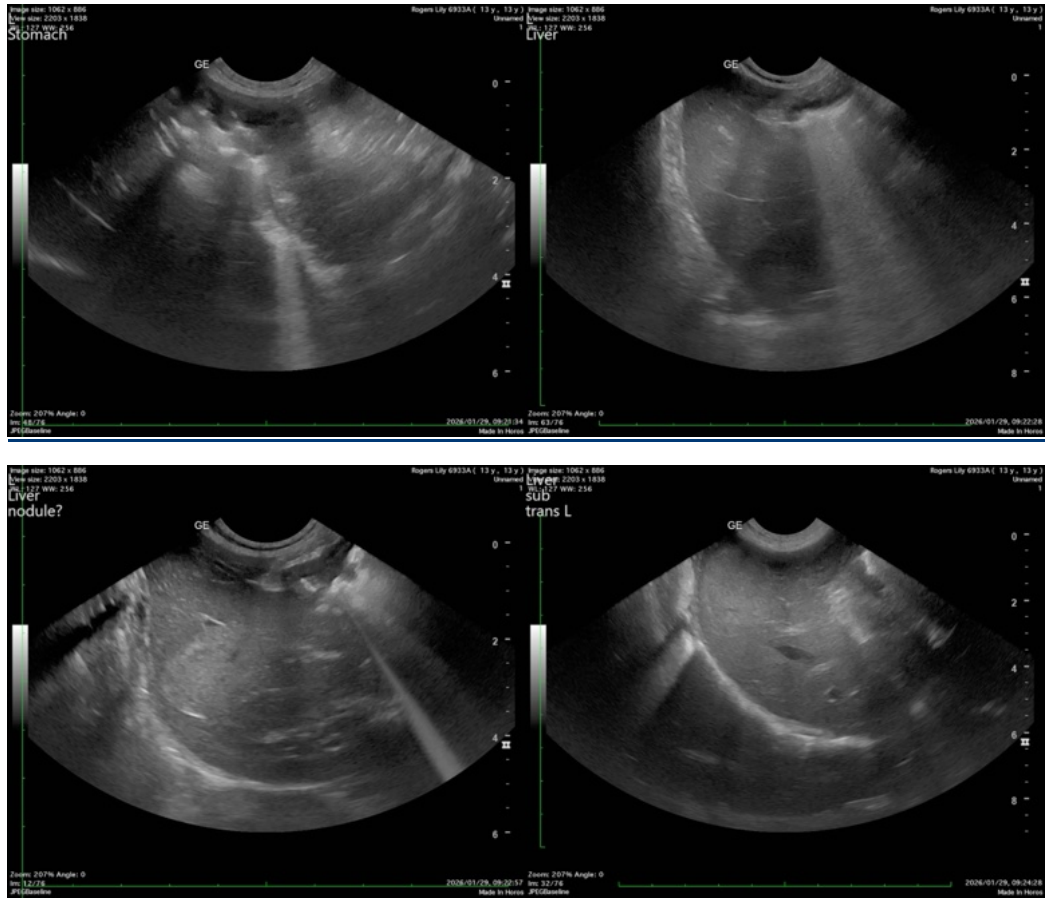
Dr. Kang

INVOICE

71073

DATE

1/29/26



The information and recommendations provided are based on the images presented by the referring veterinarian/sonographer. No evaluation can be communicated regarding pathology that was not visible in the image/video clips provided.

Thank you for this referral. If the clinical or image interpretation does not parallel your findings or if I can be of any further assistance please contact me.

Remo Lobetti, BVSc, MMedVet (Med), PhD, Dipl. ECVIM (Internal Medicine)

info@sonopath.com