



## PATIENT

Thor Kindrachauk

## SPECIES

Canine

## BREED

Border Collie Mix

## SEX

Neutered male

## AGE

12 years

## WEIGHT

61 lbs

## INTERPRETED BY

Remo Lobetti, BVSc,  
MMedVet (Med),  
PhD, Dipl. ECVIM

## IMAGING PERFORMED BY

Dr. Mueller

## HOSPITAL NAME

Cold Lake VC

## REFERRING VET

Dr. Mueller

## INVOICE

71032

## DATE

1/28/26

## PRESENTING CLINICAL SIGNS

- Sudden onset panting. Possibly painful. ALT elevated. VHS increased @ 10.9.
- Elevated ALT

## ULTRASONOGRAPHIC EXAMINATION OF THE ABDOMEN

### *Urinary System*

The urinary bladder is full with a normal thickness and smooth appearance of the wall. Normal anechoic urine with no sediment or uroliths evident.

Normal appearance of the trigone area, proximal urethra, and iliac blood vessels.

Normal appearance and size of the iliac lymph nodes. Ureters not visualized, which can be considered a normal finding.

Normal renal size (left measured 5.5 cm, right measured 5.3 cm), architecture, echogenic appearance, cortico-medullary differentiation, which maintains a 1:3 cortex to medulla ratio, pelvis, and capsule. No infarcts, mineralization or renoliths evident.

The prostate is small and hypoechogenic.

### *Adrenal Glands*

The left adrenal gland is normal in shape, echogenic appearance, size, position, and appearance of the visible peri-adrenal vasculature. Left adrenal gland measured 0.65 cm in width. The right adrenal gland was not clearly visualized, but appears to be of normal shape, echogenic appearance and size.

### *Spleen*

Normal size and echogenic appearance. Smooth homogenous parenchyma and regular curvilinear capsule. Normal volume of the splenic vasculature without any overt congestion or thrombosis evident. No inflammatory, neoplastic, infarction, or infiltrative changes evident. The spleen measured 2.3 cm in width.

### *Liver*

Normal size, echogenic appearance, portal markings, and regular curvilinear capsule. No nodules or masses evident. Normal appearance of the hepatic and portal vasculature.

### *Gallbladder*

The gallbladder is full containing a small amount of adhered, hyperechogenic sediment. Normal thickness and echogenic appearance of the wall. Normal size and appearance of the cystic and common bile duct.



**PATIENT**

Thor Kindrachauk

**SPECIES**

Canine

**BREED**

Border Collie Mix

**SEX**

Neutered male

**AGE**

12 years

**WEIGHT**

61 lbs

**INTERPRETED BY**

Remo Lobetti, BVSc,  
MMedVet (Med),  
PhD, Dipl. ECVIM

**IMAGING PERFORMED BY**

Dr. Mueller

**HOSPITAL NAME**

Cold Lake VC

**REFERRING VET**

Dr. Mueller

**INVOICE**

71032

**DATE**

1/28/26

**Gastrointestinal**

Normal appearance of the stomach, duodenum, small intestine, ileo-cecal junction, and colon with no loss of layering, 1:3 muscularis to mucosa ratio, normal wall thickness and peristaltic activity, and no distension of the lumen. A moderate amount of ingesta is present within the stomach compatible with a recent meal.

**Pancreas**

The visible sections of the pancreas are of normal size and echogenic appearance with a regular capsule. Normal echogenic appearance of the mesentery and fat surrounding the pancreas.

**Free Abdomen**

Normal mesenteric lymph nodes.  
No ascites evident.

**ULTRASONOGRAPHIC FINDINGS**

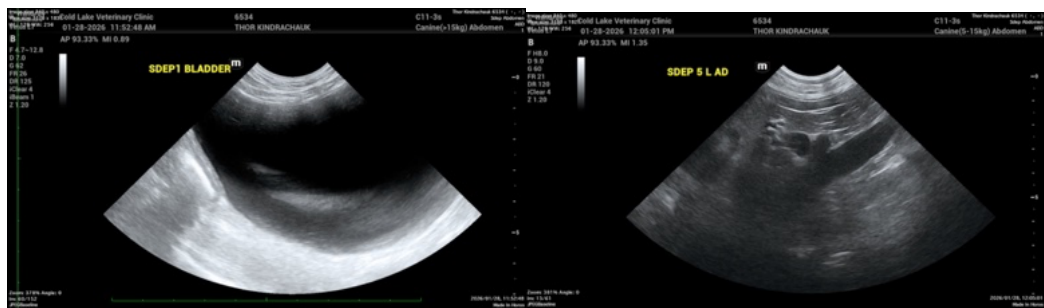
- Gallbladder sediment.

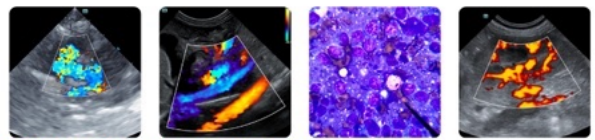
**INTERPRETATION OF THE FINDINGS & FURTHER RECOMMENDATIONS**

In essence a normal ultrasound examination of the abdomen as the gallbladder sediment can be considered an incidental finding.

Further assessment would be survey thoracic radiographs and possibly echocardiography.

Specific therapy would be dependent on an etiological diagnosis.





**PATIENT**

Thor Kindrachauk

**SPECIES**

Canine

**BREED**

Border Collie Mix

**SEX**

Neutered male

**AGE**

12 years

**WEIGHT**

61 lbs

**INTERPRETED BY**

Remo Lobetti, BVSc,  
MMedVet (Med),  
PhD, Dipl. ECVIM

**IMAGING PERFORMED BY**

Dr. Mueller

**HOSPITAL NAME**

Cold Lake VC

**REFERRING VET**

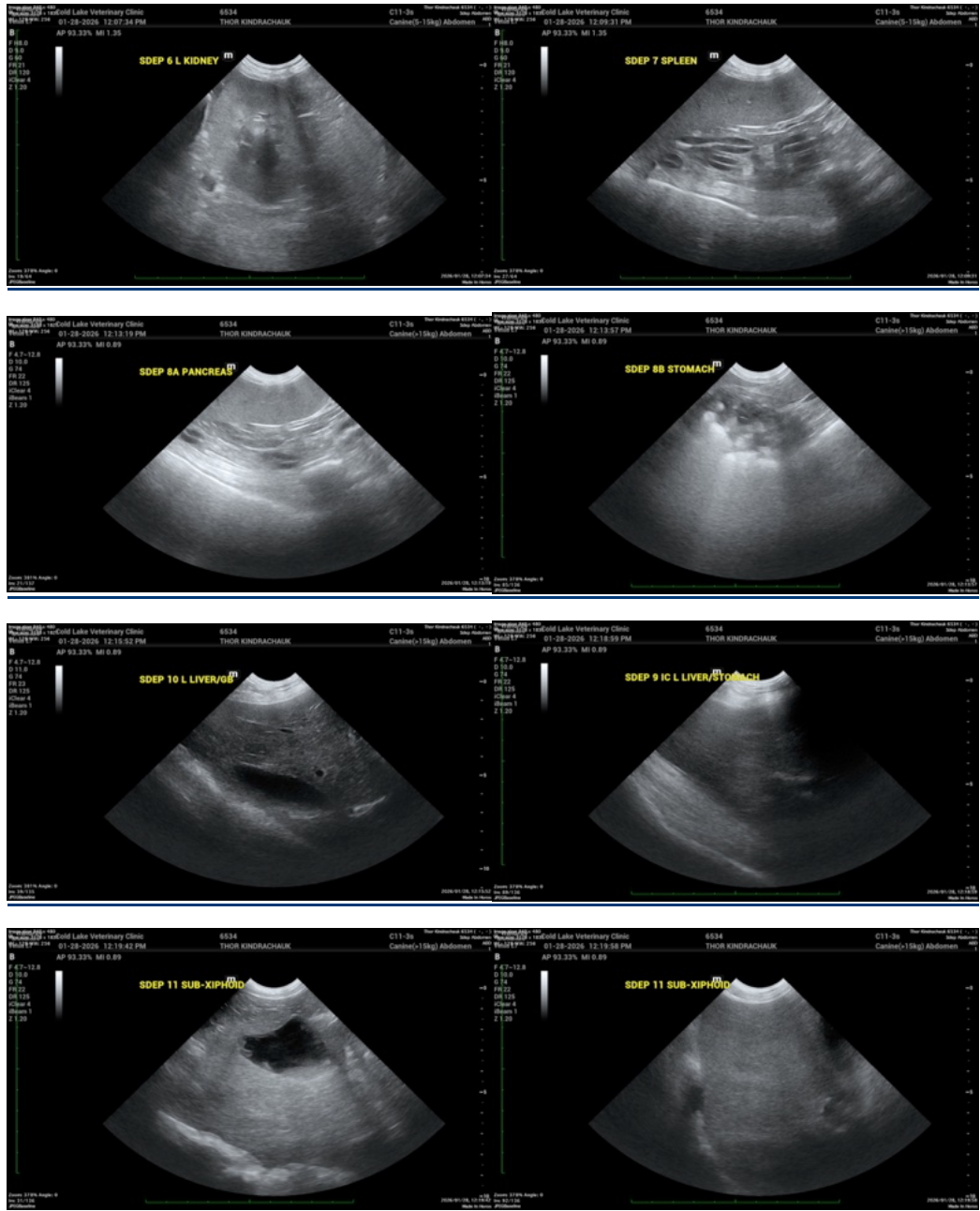
Dr. Mueller

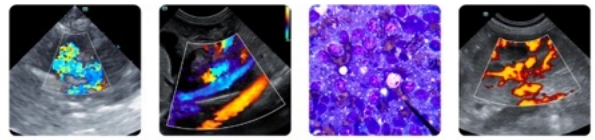
**INVOICE**

71032

**DATE**

1/28/26





## PATIENT

Thor Kindrachauk

## SPECIES

Canine

## BREED

Border Collie Mix

## SEX

Neutered male

## AGE

12 years

## WEIGHT

61 lbs

## INTERPRETED BY

Remo Lobetti, BVSc,  
MMedVet (Med),  
PhD, Dipl. ECVIM

## IMAGING PERFORMED BY

Dr. Mueller

## HOSPITAL NAME

Cold Lake VC

## REFERRING VET

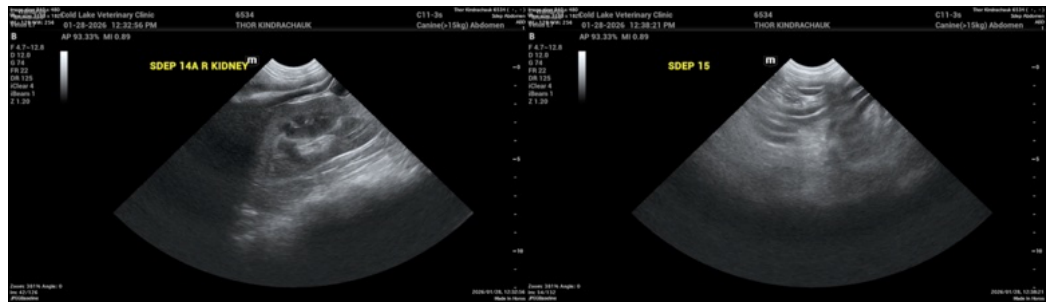
Dr. Mueller

## INVOICE

71032

## DATE

1/28/26



The information and recommendations provided are based on the images presented by the referring veterinarian/sonographer. No evaluation can be communicated regarding pathology that was not visible in the image/video clips provided.

Thank you for this referral. If the clinical or image interpretation does not parallel your findings or if I can be of any further assistance please contact me.

Remo Lobetti, BVSc, MMedVet (Med), PhD, Dipl. ECVIM (Internal Medicine)

[info@sonopath.com](mailto:info@sonopath.com)