



PATIENT

Lila Brezovic

SPECIES

Feline

BREED

Domestic Shorthair

SEX

Spayed Female

AGE

2 years

WEIGHT

14.4 lbs

INTERPRETED BY

Remo Lobetti, BVSc,
MMedVet (Med),
PhD, Dipl. ECVIM

IMAGING PERFORMED BY

Susan Lincoski, VMD

HOSPITAL NAME

University Drive VH

REFERRING VET

Dr. Lincoski

INVOICE

71004

DATE

1/28/26

PRESENTING CLINICAL SIGNS

- Frequent vomiting, ongoing since summer 2024. Radiographs at that time were unremarkable. Usually food, about 1 hour post eating. Appetite and activity fine. Owner has tried changing food, slow feeder, hairball laxatives. Bloodwork pending and pulled blood for GI panel if needed.
- WNL exam, Bloodwork pending

ULTRASONOGRAPHIC EXAMINATION OF THE ABDOMEN

Urinary System

The urinary bladder is full with a normal thickness and smooth appearance of the wall. Normal anechoic urine with no sediment or uroliths evident.

Normal appearance of the trigone area, proximal urethra, and iliac blood vessels.

Normal appearance and size of the iliac lymph nodes. Ureters not visualized, which can be considered a normal finding.

Normal renal size (left measured 2.7 cm, right measured 3.8 cm), architecture, echogenic appearance, cortico-medullary differentiation, which maintains a 1:3 cortex to medulla ratio, pelvis, and capsule. No infarcts, mineralization or renoliths evident. Normal color flow pattern is evident in both kidneys.

Adrenal Glands

Normal shape, echogenic appearance, size, position, and appearance of the visible peri-adrenal vasculature. Left adrenal gland measured 0.92 cm in length x 0.44 cm in width. The right adrenal gland measured 1.17 cm in length x 0.4 cm in width.

Spleen

Normal size and echogenic appearance. Smooth homogenous parenchyma and regular curvilinear capsule. Normal volume of the splenic vasculature without any overt congestion or thrombosis evident. No inflammatory, neoplastic, infarction, or infiltrative changes evident. The spleen measured 0.8 cm in width.

Liver

Normal size, echogenic appearance, portal markings, and regular curvilinear capsule. No nodules or masses evident. Normal appearance of the hepatic and portal vasculature.



PATIENT

Lila Brezovic

SPECIES

Feline

BREED

Domestic Shorthair

SEX

Spayed Female

AGE

2 years

WEIGHT

14.4 lbs

INTERPRETED BY

Remo Lobetti, BVSc,
MMedVet (Med),
PhD, Dipl. ECVIM

IMAGING PERFORMED BY

Susan Lincoski, VMD

HOSPITAL NAME

University Drive VH

REFERRING VET

Dr. Lincoski

INVOICE

71004

DATE

1/28/26

Gallbladder

The gallbladder is full containing normal anechoic bile. Normal thickness and echogenic appearance of the wall. Normal size and appearance of the cystic and common bile duct.

Gastrointestinal

Normal appearance of the stomach, duodenum, ileo-cecal junction, and colon with no loss of layering, 1:3 muscularis to mucosa ratio, normal wall thickness and peristaltic activity, and no distension of the lumen. Normal thickness of the small intestine (up to 0.25 cm) with no loss of layering, but with an increase in the muscularis to mucosa ratio, normal peristaltic activity and no distension of the lumen.

Pancreas

The visible sections of the pancreas are of normal size and echogenic appearance with a regular capsule. Normal echogenic appearance of the mesentery and fat surrounding the pancreas.

Free Abdomen

Normal mesenteric lymph nodes.

No ascites evident.

ULTRASONOGRAPHIC FINDINGS

- Enteropathy.

INTERPRETATION OF THE FINDINGS & FURTHER RECOMMENDATIONS

The likely etiologies for the enteropathy would be parasitic enteritis, dietary hypersensitivity and inflammatory bowel disease with emerging lymphoma a less likely differential diagnosis.

Further assessment would be fecal analysis, cobalamin and folate assay and endoscopy of the upper GI tract with biopsies.

Specific therapy would be dependent on an etiological diagnosis.

Symptomatic management would be feeding small frequent meals of a hypoallergenic/novel protein diet, cobalamin supplementation, course of Fenbendazole and if there is still not a satisfactory improvement then a course of Prednisolone would then be indicated.



PATIENT

Lila Brezovic

SPECIES

Feline

BREED

Domestic Shorthair

SEX

Spayed Female

AGE

2 years

WEIGHT

14.4 lbs

INTERPRETED BY

Remo Lobetti, BVSc,
MMedVet (Med),
PhD, Dipl. ECVIM

IMAGING PERFORMED BY

Susan Lincoski, VMD

HOSPITAL NAME

University Drive VH

REFERRING VET

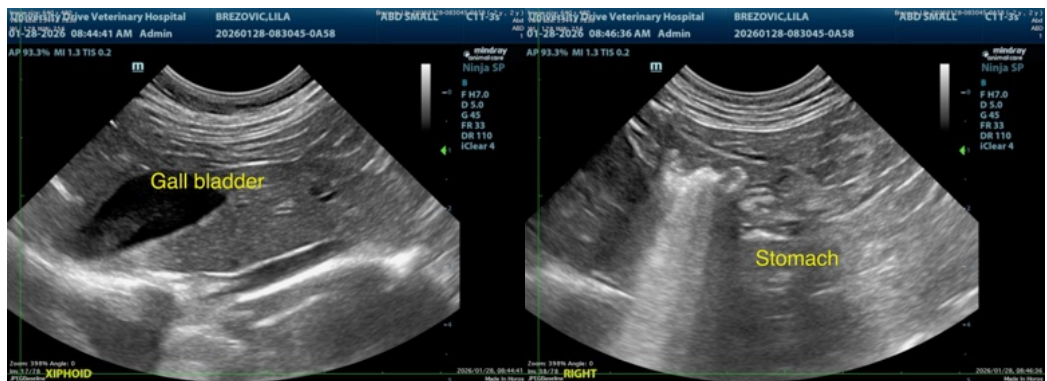
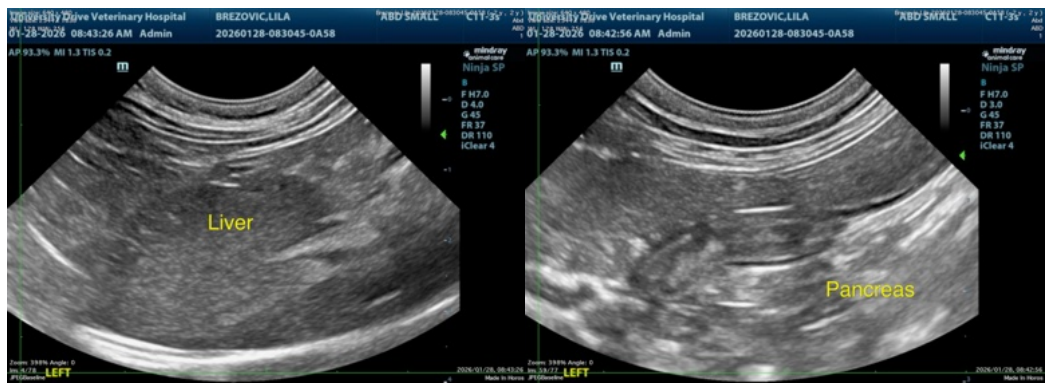
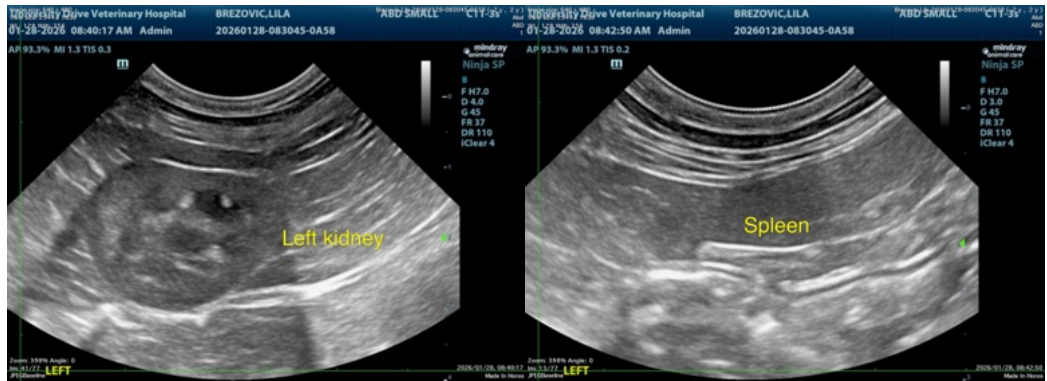
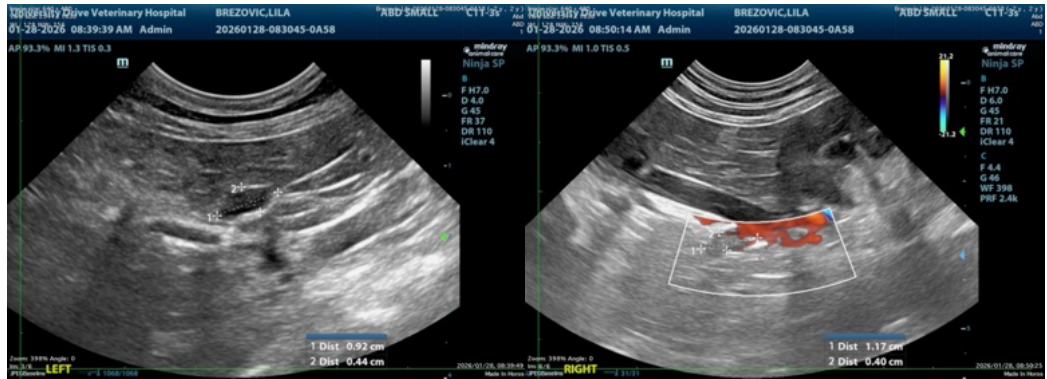
Dr. Lincoski

INVOICE

71004

DATE

1/28/26





PATIENT

Lila Brezovic

SPECIES

Feline

BREED

Domestic Shorthair

SEX

Spayed Female

AGE

2 years

WEIGHT

14.4 lbs

INTERPRETED BY

Remo Lobetti, BVSc,
MMedVet (Med),
PhD, Dipl. ECVIM

IMAGING PERFORMED BY

Susan Lincoski, VMD

HOSPITAL NAME

University Drive VH

REFERRING VET

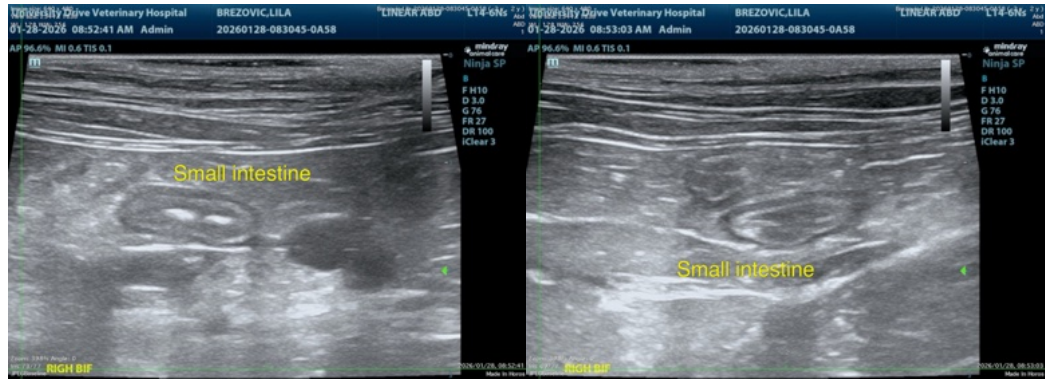
Dr. Lincoski

INVOICE

71004

DATE

1/28/26



The information and recommendations provided are based on the images presented by the referring veterinarian/sonographer. No evaluation can be communicated regarding pathology that was not visible in the image/video clips provided.

Thank you for this referral. If the clinical or image interpretation does not parallel your findings or if I can be of any further assistance please contact me.

Remo Lobetti, BVSc, MMedVet (Med), PhD, Dipl. ECVIM (Internal Medicine)

info@sonopath.com