



PATIENT

Jiji Quinn

SPECIES

Feline

BREED

Domestic Shorthair

SEX

Neutered male

AGE

10 months

WEIGHT

7.08 lbs

INTERPRETED BY

Remo Lobetti, BVSc,
MMedVet (Med),
PhD, Dipl. ECVIM

IMAGING PERFORMED BY

Renee Ziegler Post

HOSPITAL NAME

For Cats Only VC

REFERRING VET

Dr. Ziegler Post

INVOICE

70998

DATE

1/27/26

PRESENTING CLINICAL SIGNS

- Not eating about 5 days.
- Lethargy.

ULTRASONOGRAPHIC EXAMINATION OF THE ABDOMEN

Urinary System

The urinary bladder is full with a normal thickness and smooth appearance of the wall. A scant amount of floating, hyperechogenic sediment is noted.

Normal appearance of the trigone area, proximal urethra, and iliac blood vessels.

Normal appearance and size of the iliac lymph nodes. Ureters not visualized, which can be considered a normal finding.

Normal renal size (left measured 3.3 cm, right measured 3.3 cm), architecture, echogenic appearance, cortico-medullary differentiation, which maintains a 1:3 cortex to medulla ratio, pelvis, and capsule. No infarcts, mineralization or renoliths evident. Normal color flow pattern is noted in the kidneys.

Adrenal Glands

Normal shape, echogenic appearance, size, position, and appearance of the visible peri-adrenal vasculature. Left adrenal gland measured 0.58 cm in length. The right adrenal gland measured 0.51 cm in length.

Spleen

Normal size and echogenic appearance. Smooth homogenous parenchyma and regular curvilinear capsule. Normal volume of the splenic vasculature without any overt congestion or thrombosis evident. No inflammatory, neoplastic, infarction, or infiltrative changes evident. The spleen measured 0.8 cm in width.

Liver

Normal size, echogenic appearance, portal markings, and regular curvilinear capsule. No nodules or masses evident. Normal appearance of the hepatic and portal vasculature.

Gallbladder

The gallbladder is full containing normal anechoic bile. Normal thickness and echogenic appearance of the wall. Normal size and appearance of the cystic and common bile duct.



PATIENT

Jiji Quinn

SPECIES

Feline

BREED

Domestic Shorthair

SEX

Neutered male

AGE

10 months

WEIGHT

7.08 lbs

INTERPRETED BY

Remo Lobetti, BVSc,
MMedVet (Med),
PhD, Dipl. ECVIM

IMAGING PERFORMED BY

Renee Ziegler Post

HOSPITAL NAME

For Cats Only VC

REFERRING VET

Dr. Ziegler Post

INVOICE

70998

DATE

1/27/26

Gastrointestinal

Normal appearance of the stomach, duodenum, small intestine, ileo-cecal junction, and colon with no loss of layering, 1:3 muscularis to mucosa ratio, normal wall thickness and peristaltic activity, and no distension of the lumen. The small intestine measured up to 0.25 cm.

Pancreas

The visible sections of the pancreas are of normal size and echogenic appearance with a regular capsule. Normal echogenic appearance of the mesentery and fat surrounding the pancreas.

Free Abdomen

Normal mesenteric lymph nodes.

No ascites evident.

Focal, enlarged, lymph node is noted in the caudal abdomen with an irregular shape and a hypoechoic appearance measuring 1.2 x 3.3 cm in size.

ULTRASONOGRAPHIC FINDINGS

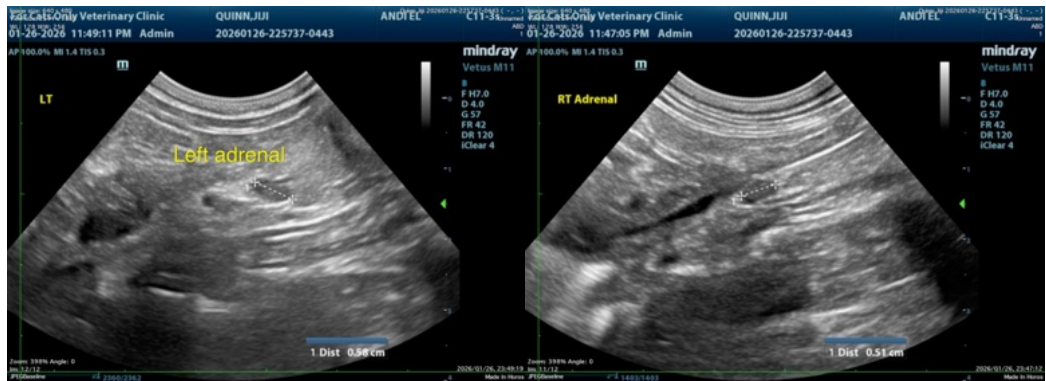- Focal lymphadenomegaly.

INTERPRETATION OF THE FINDINGS & FURTHER RECOMMENDATIONS

With the appearance of the lymph node, etiologies for the lymphadenomegaly would be infiltrative neoplasia and lymphadenitis. Reactive hyperplasia would be a less likely differential diagnosis.

Further assessment would be FNA cytology of the lymph node.

Specific therapy would be dependent on an etiological diagnosis.





PATIENT

Jiji Quinn

SPECIES

Feline

BREED

Domestic Shorthair

SEX

Neutered male

AGE

10 months

WEIGHT

7.08 lbs

INTERPRETED BY

Remo Lobetti, BVSc,
MMedVet (Med),
PhD, Dipl. ECVIM

IMAGING PERFORMED BY

Renee Ziegler Post

HOSPITAL NAME

For Cats Only VC

REFERRING VET

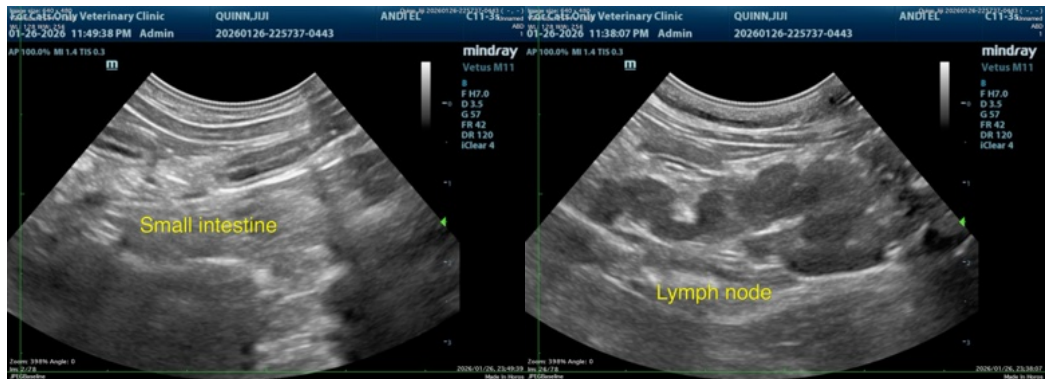
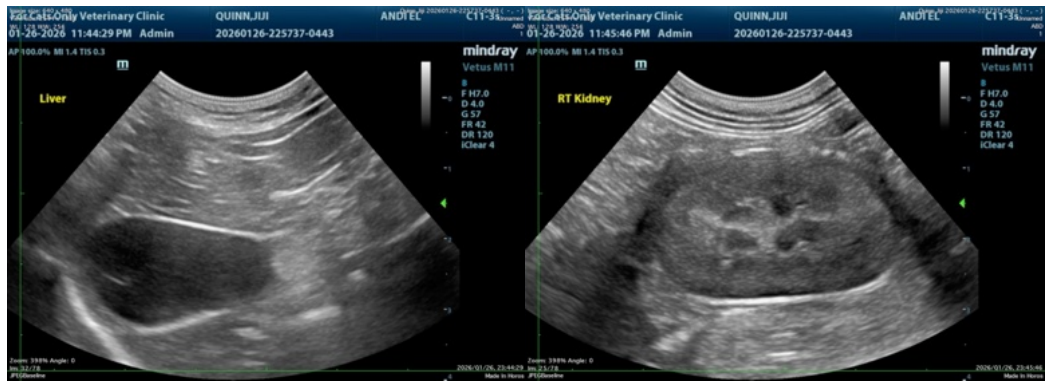
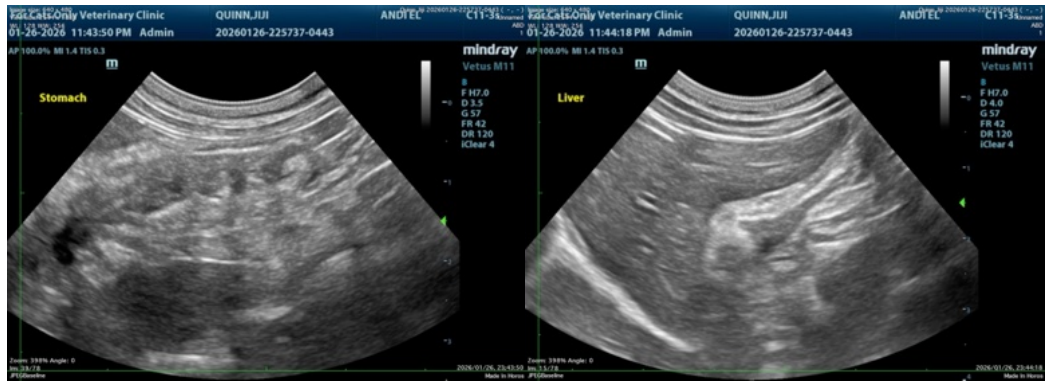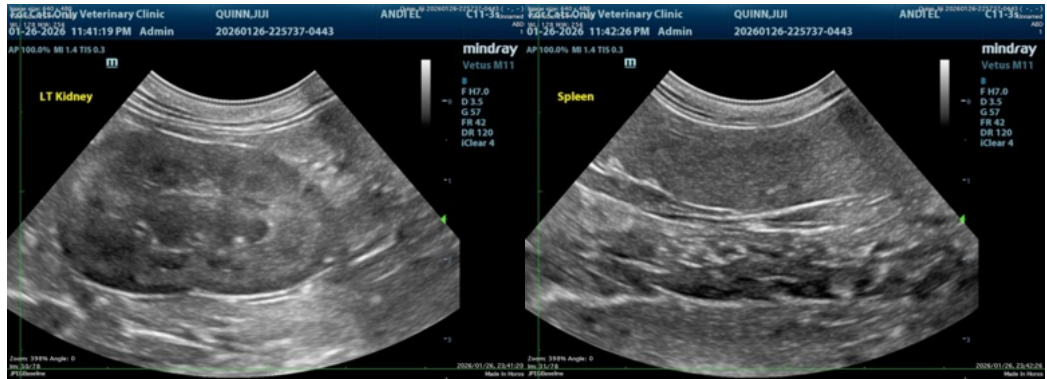
Dr. Ziegler Post

INVOICE

70998

DATE

1/27/26





PATIENT

Jiji Quinn

SPECIES

Feline

BREED

Domestic Shorthair

SEX

Neutered male

AGE

10 months

WEIGHT

7.08 lbs

INTERPRETED BY

Remo Lobetti, BVSc,
MMedVet (Med),
PhD, Dipl. ECVIM

IMAGING PERFORMED BY

Renee Ziegler Post

HOSPITAL NAME

For Cats Only VC

REFERRING VET

Dr. Ziegler Post

INVOICE

70998

DATE

1/27/26

The information and recommendations provided are based on the images presented by the referring veterinarian/sonographer. No evaluation can be communicated regarding pathology that was not visible in the image/video clips provided.

Thank you for this referral. If the clinical or image interpretation does not parallel your findings or if I can be of any further assistance please contact me.

Remo Lobetti, BVSc, MMedVet (Med), PhD, Dipl. ECVIM (Internal Medicine)

info@sonopath.com