



PATIENT

Bitsy Burdick

SPECIES

Canine

BREED

Chihuahua

SEX

Spayed female

AGE

10 months

WEIGHT

16.34 lbs

INTERPRETED BY

Remo Lobetti, BVSc,
MMedVet (Med),
PhD, Dipl. ECVIM

IMAGING PERFORMED BY

Dr. Kendall Helbert

HOSPITAL NAME

South College VC

REFERRING VET

Dr. Helbert

INVOICE

70984

DATE

1/27/26

PRESENTING CLINICAL SIGNS

- Chronic elevation of ALT since 07/31/2025 - have tested 7 times with elevation 6 times
- First noted on pre-anesthetic bloodwork prior to OHE
- No clinical signs present
- P treated with Denamarin for 3 months with minimal results
- Littermate has normal blood values
- Bile acid - pending results
- Elevated ALT 07/31/25: 102 (8-75 U/L) 08/08/25: 110 (8-75 U/L) 10/10/25: 142 (10-125 U/L) 01/08/26: 219 (10-125 U/L) 01/22/26: 142 (10-125 U/L) 01/27/26: 131 (10-125 U/L) 09/08/25: 113 (10-125 U/L) - the only incidence of "normal" value

ULTRASONOGRAPHIC EXAMINATION OF THE ABDOMEN

Urinary System

The urinary bladder is full with a normal thickness and smooth appearance of the wall. Normal anechoic urine with no sediment or uroliths evident.

Normal appearance of the trigone area, proximal urethra, and iliac blood vessels.

Normal appearance and size of the iliac lymph nodes. Ureters not visualized, which can be considered a normal finding.

Normal renal size (left measured 4.0 cm, right measured 4.3 cm), architecture, echogenic appearance, cortico-medullary differentiation, which maintains a 1:3 cortex to medulla ratio, pelvis, and capsule. No infarcts, mineralization or renoliths evident. Normal color flow pattern is evident in both kidneys.

Adrenal Glands

Normal shape, echogenic appearance, size, position, and appearance of the visible peri-adrenal vasculature. Left adrenal gland measured 1.6 cm in length x 0.5 cm and 0.33 cm in width. The right adrenal gland measured 1.54 cm in length x 0.32 cm in width.

Spleen

Normal size and echogenic appearance. Smooth homogenous parenchyma and regular curvilinear capsule. Normal volume of the splenic vasculature without any overt congestion or thrombosis evident. No inflammatory, neoplastic, infarction, or infiltrative changes evident. The spleen measured 1.5 cm in width.

Liver

Normal size, echogenic appearance, portal markings, and regular curvilinear capsule. No nodules or masses evident. Normal appearance of the hepatic and portal vasculature.



PATIENT

Bitsy Burdick

SPECIES

Canine

BREED

Chihuahua

SEX

Spayed female

AGE

10 months

WEIGHT

16.34 lbs

INTERPRETED BY

Remo Lobetti, BVSc,
MMedVet (Med),
PhD, Dipl. ECVIM

IMAGING PERFORMED BY

Dr. Kendall Helbert

HOSPITAL NAME

South College VC

REFERRING VET

Dr. Helbert

INVOICE

70984

DATE

1/27/26

Gallbladder

The gallbladder is full containing normal anechoic bile. Normal thickness and echogenic appearance of the wall. Normal size and appearance of the cystic and common bile duct.

Gastrointestinal

Normal appearance of the stomach, duodenum, small intestine, ileo-cecal junction, and colon with no loss of layering, 1:3 muscularis to mucosa ratio, normal wall thickness and peristaltic activity, and no distension of the lumen.

Pancreas

The visible sections of the pancreas are of normal size and echogenic appearance with a regular capsule. Normal echogenic appearance of the mesentery and fat surrounding the pancreas.

Free Abdomen

Normal mesenteric lymph nodes.

No ascites evident.

ULTRASONOGRAPHIC FINDINGS

- Normal ultrasound examination of the abdomen.

INTERPRETATION OF THE FINDINGS & FURTHER RECOMMENDATIONS

On this ultrasound there is no obvious etiology for the elevated ALT activity.

Although the liver appears ultrasonographically normal with the elevated ALT activity, an underlying hepatopathy such as reactive hyperplasia, vacuolar and metabolic should still be considered.

A small portosystemic shunt or primary portal vein hyperplasia would be a less likely differential diagnosis.

Further assessment would be based on the pending bile acids and if severely elevated then further assessment would be CT angiography and possibly a liver biopsy.

FNA cytology of the liver could also be considered.

Specific therapy would be dependent on an etiological diagnosis. Symptomatic management that can be tried would be the use of Ursodiol with regular monitoring of liver enzyme activity.



PATIENT

Bitsy Burdick

SPECIES

Canine

BREED

Chihuahua

SEX

Spayed female

AGE

10 months

WEIGHT

16.34 lbs

INTERPRETED BY

Remo Lobetti, BVSc,
MMedVet (Med),
PhD, Dipl. ECVIM

IMAGING PERFORMED BY

Dr. Kendall Helbert

HOSPITAL NAME

South College VC

REFERRING VET

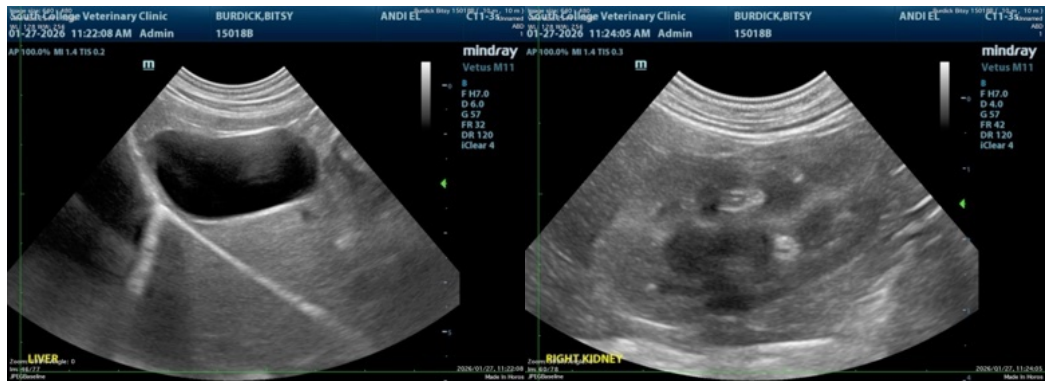
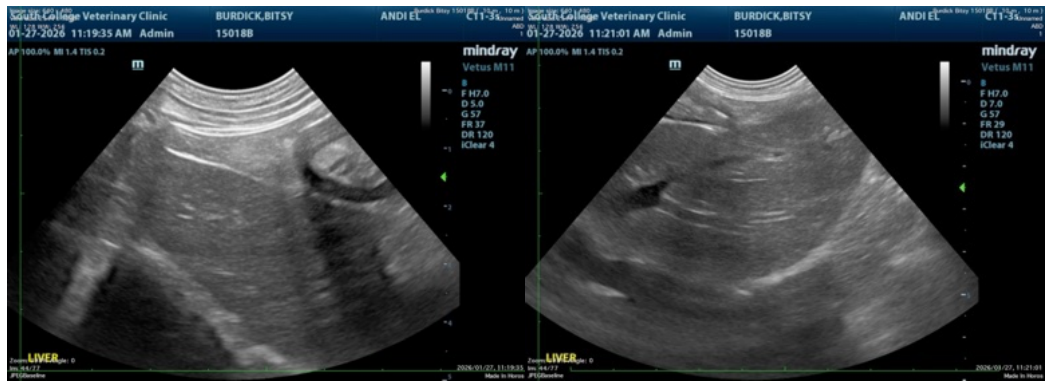
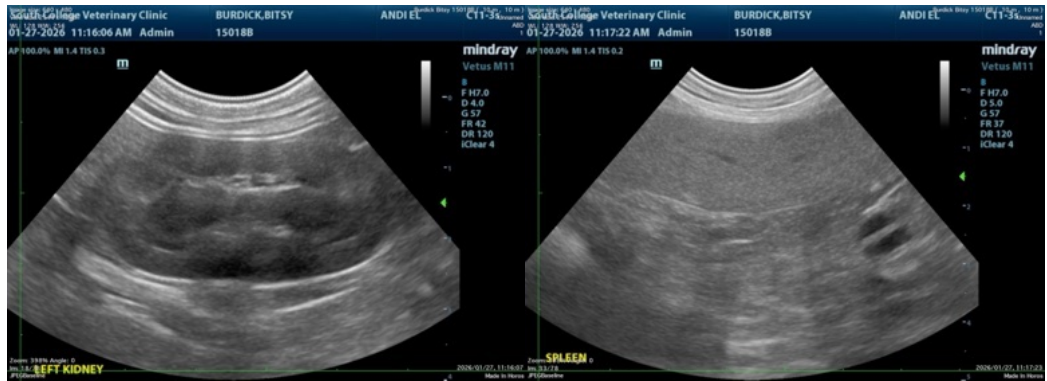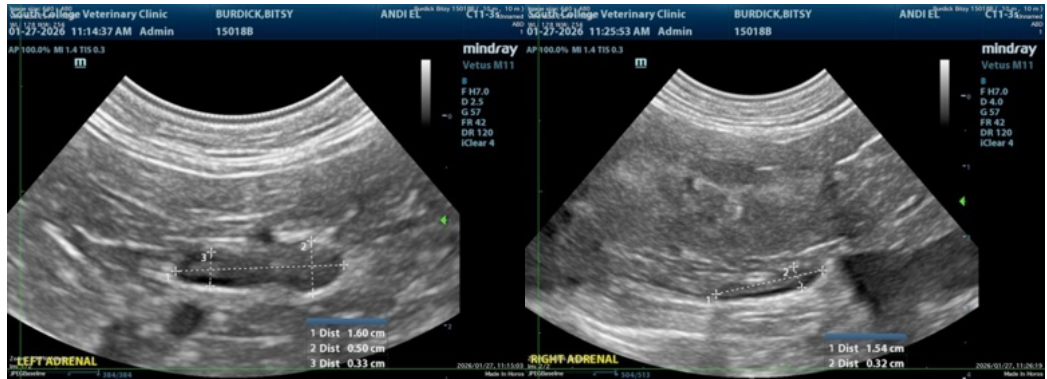
Dr. Helbert

INVOICE

70984

DATE

1/27/26





PATIENT

Bitsy Burdick

SPECIES

Canine

BREED

Chihuahua

SEX

Spayed female

AGE

10 months

WEIGHT

16.34 lbs

INTERPRETED BY

Remo Lobetti, BVSc,
MMedVet (Med),
PhD, Dipl. ECVIM

IMAGING PERFORMED BY

Dr. Kendall Helbert

HOSPITAL NAME

South College VC

REFERRING VET

Dr. Helbert

INVOICE

70984

DATE

1/27/26

The information and recommendations provided are based on the images presented by the referring veterinarian/sonographer. No evaluation can be communicated regarding pathology that was not visible in the image/video clips provided.

Thank you for this referral. If the clinical or image interpretation does not parallel your findings or if I can be of any further assistance please contact me.

Remo Lobetti, BVSc, MMedVet (Med), PhD, Dipl. ECVIM (Internal Medicine)

info@sonopath.com