

**PATIENT**

Cassieopeia Zanfini

**SPECIES**

Feline

**BREED**

DSH

**SEX**

Spayed Female

**AGE**

13 Years

**WEIGHT**

7.5 lbs

**INTERPRETED BY**

Remo Lobetti, BVSc,  
MMedVet (Med),  
PhD, Dipl. ECVIM

**IMAGING PERFORMED BY**

Kerri Becker

**HOSPITAL NAME**

Plainfield Animal  
Hospital

**REFERRING VET**

Dr. Musum

**INVOICE**

72418

**DATE**

1/23/26

**PRESENTING CLINICAL SIGNS**

Hematuria- urine looks clearer today, straining to urinate intermittently- pet given convenia 1/15/26

Abnormal PE/Chem/CBC/UA Results: ALT-123 creat-1.7 SDMA-16.1 neut-12580 lymph-1184 USG-1.015 RBC>50 blood-3+ wbc->50

**ULTRASONOGRAPHIC EXAMINATION OF THE ABDOMEN**

**Urinary System**

Full urinary bladder with a normal thickness and smooth appearance of the wall. Normal anechoic urine with no sediment or uroliths evident.

Normal appearance of the trigone area, proximal urethra, and iliac blood vessels.

Normal appearance and size of the iliac lymph nodes. Ureters not visualized, which can be considered a normal finding.

Normal renal size, architecture, echogenic appearance, cortico-medullary differentiation, which maintains a 1:3 cortex to medulla ratio, pelvis, and capsule. No infarcts, mineralization or renoliths evident. Left kidney measures 3.1 cm. Right kidney measures 3.0 cm. Normal color flow pattern evident in both kidneys.

**Adrenal Glands**

Normal shape, echogenic appearance, size, position, and appearance of the visible peri-adrenal vasculature. Left measures 0.35 cm in width. Right measures 0.31 cm in width.

**Spleen**

Normal size (0.70 cm in width) and echogenic appearance. Smooth homogenous parenchyma and regular curvilinear capsule. Normal volume of the splenic vasculature without any overt congestion or thrombosis evident. No inflammatory, neoplastic, infarction, or infiltrative changes evident.

**Liver**

Normal size, echogenic appearance, portal markings, and regular curvilinear capsule. No nodules or masses evident. Normal appearance of the hepatic and portal vasculature.

**Gallbladder**

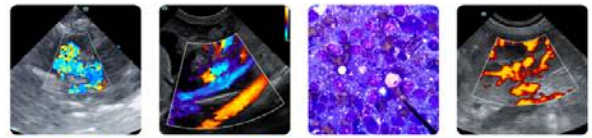
Small containing normal anechoic bile. Normal thickness and echogenic appearance of the wall. Normal size and appearance of the cystic and common bile duct.

**Gastrointestinal**

Normal appearance of the stomach, duodenum, small intestine, ileo-cecal junction, and colon with no loss of layering, 1:3 muscularis to mucosa ratio, normal wall thickness and peristaltic activity, and no distension of the lumen.

**Pancreas**

Visible section presents normal size and echogenic appearance. Regular capsule. Normal echogenic appearance of the mesentery and fat surrounding the pancreas.



**PATIENT**

Cassieopeia Zanfini

**SPECIES**

Feline

**BREED**

DSH

**SEX**

Spayed Female

**AGE**

13 Years

**WEIGHT**

7.5 lbs

**INTERPRETED BY**

Remo Lobetti, BVSc,  
 MMedVet (Med),  
 PhD, Dipl. ECVIM

**IMAGING PERFORMED BY**

Kerri Becker

**HOSPITAL NAME**

Plainfield Animal  
 Hospital

**REFERRING VET**

Dr. Musum

**INVOICE**

72418

**DATE**

1/23/26

**Free Abdomen**

Normal mesenteric lymph nodes.

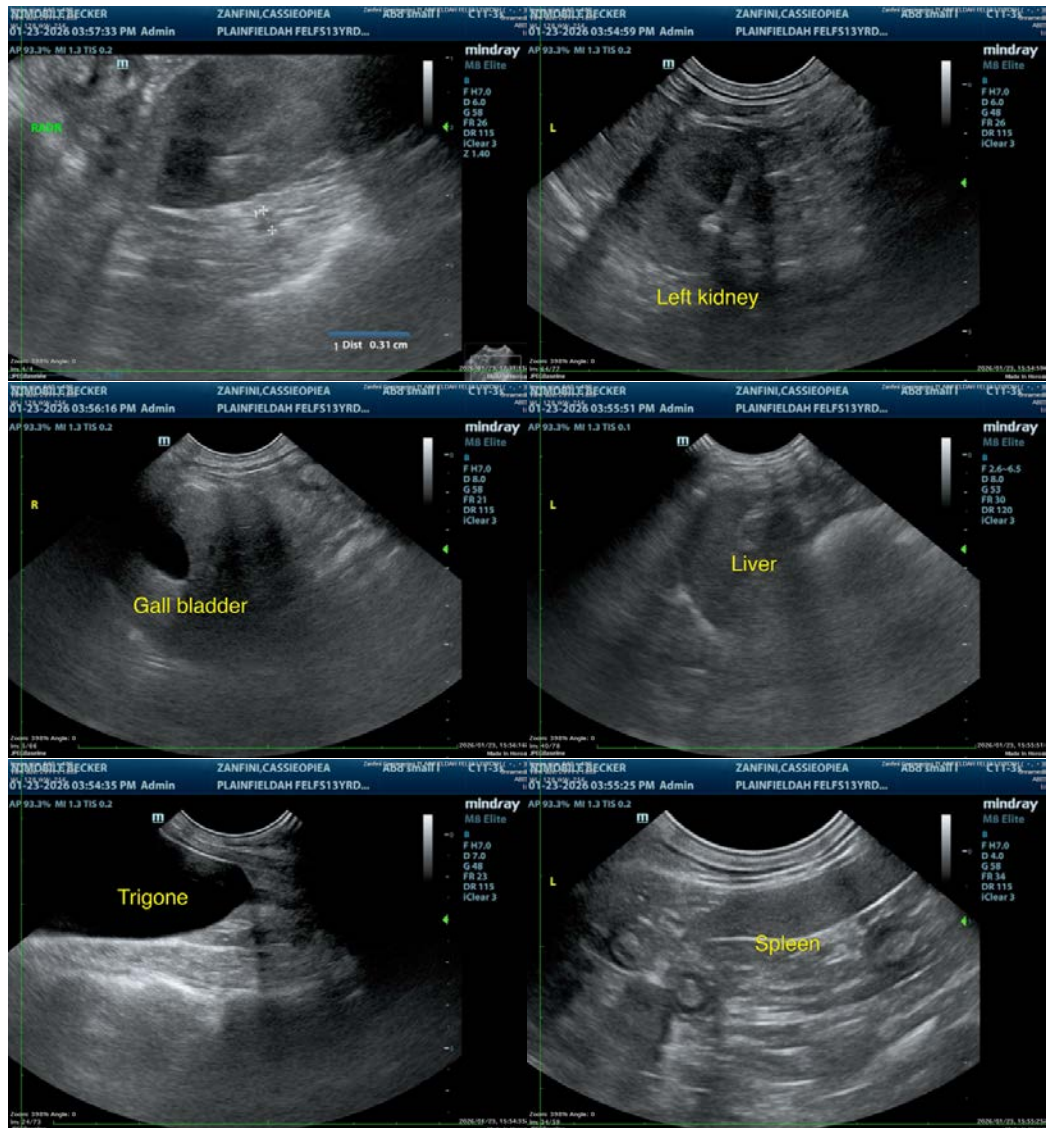
No ascites evident.

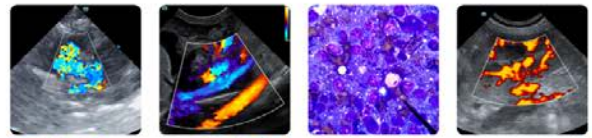
**ULTRASONOGRAPHIC FINDINGS**

- Normal ultrasound examination of the abdomen.

**INTERPRETATION OF THE FINDINGS & FURTHER RECOMMENDATIONS**

On this ultrasound, there is no obvious etiology for the hematuria. An important etiology for the hematuria would be feline interstitial cystitis or idiopathic cystitis.





**PATIENT**

Cassieopia Zanfini

**SPECIES**

Feline

**BREED**

DSH

**SEX**

Spayed Female

**AGE**

13 Years

**WEIGHT**

7.5 lbs

**INTERPRETED BY**

Remo Lobetti, BVSc,  
 MMedVet (Med),  
 PhD, Dipl. ECVIM

**IMAGING PERFORMED BY**

Kerri Becker

**HOSPITAL NAME**

Plainfield Animal  
 Hospital

**REFERRING VET**

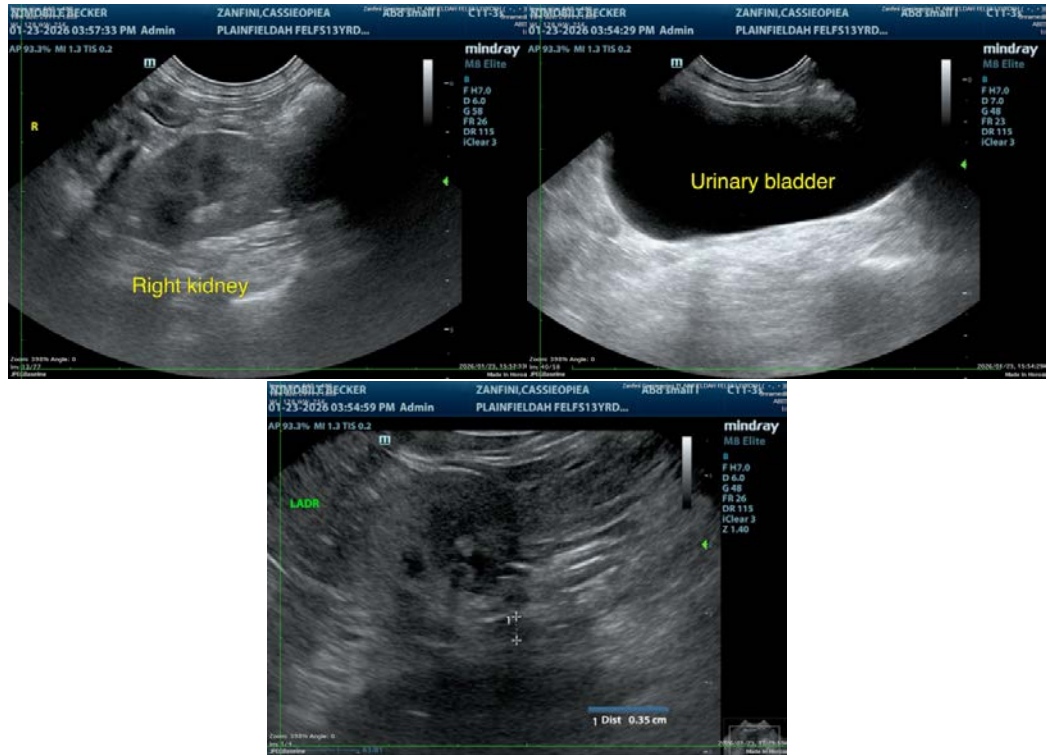
Dr. Musum

**INVOICE**

72418

**DATE**

1/23/26



The information and recommendations provided are based on the images presented by the referring veterinarian. No evaluation can be communicated regarding pathology that was not visible in the image/video clips provided.

Thank you for this referral. If the clinical or image interpretation does not parallel your findings or if I can be of any further assistance, please contact me.

Remo Lobetti, BVSc, MMedVet (Med), PhD, Dipl. ECVIM (Internal Medicine)

[info@sonopath.com](mailto:info@sonopath.com)