



## PATIENT

Rosie Ianni

## SPECIES

Canine

## BREED

Golden Retriever

## SEX

Spayed female

## AGE

12 years

## WEIGHT

70 lbs

## INTERPRETED BY

Remo Lobetti, BVSc,  
MMedVet (Med),  
PhD, Dipl. ECVIM

## IMAGING PERFORMED BY

Brandi Kurzowski

## HOSPITAL NAME

Corfu VC

## REFERRING VET

Dr. Gardner

## INVOICE

70318

## DATE

1/20/26

## PRESENTING CLINICAL SIGNS

P presented 12/16/25 for annual exam/BW. Based on albumin levels a urine sample was ran, tentatively diagnosed with glomerulonephritis- tx with doxycycline in case of lyme exposure. Plan to recheck urine/upc after course of abx. P came back 1/13/26 for ADR and possible UTI, repeat UA confirms UTI. P started on enalapril and cefpodoxime at this time. Concern for neoplasia and/or renal disease, o elects to pursue abdominal ultrasound. Plan to check UPC 4 weeks after starting enalapril.

Abnormal PE/Chem/CBC/UA Results: 12/17/25 Chem - ALB 2.4 g/dL, GLOB 4.3 g/dL T4- 2 ug/dL (WNL) 12/20/25 UA- Protein 500mg/dL, USG 1.050, non hyaline casts >1/lpf, WBC 7/hpf, RBC 2/hpf 1/13/26 UA- USG 1.050, protein 500mg/dL, WBC 19/hpf, RBC 2/hpf, no casts detected

## ULTRASONOGRAPHIC EXAMINATION OF THE ABDOMEN

### Urinary System

The urinary bladder is full with a normal thickness and smooth appearance of the wall. Normal anechoic urine with no sediment or uroliths evident.

Normal appearance of the trigone area, proximal urethra, and iliac blood vessels.

Normal appearance and size of the iliac lymph nodes. Ureters not visualized, which can be considered a normal finding.

Normal renal size (left measured 6.2 cm, right measured 5.9 cm), architecture, echogenic appearance, cortico-medullary differentiation, which maintains a 1:3 cortex to medulla ratio, pelvis, and capsule. No infarcts, mineralization or renoliths evident. Normal color flow pattern is evident in both kidneys.

### Adrenal Glands

Normal shape, echogenic appearance, size, position, and appearance of the visible peri-adrenal vasculature. Left adrenal gland measured 0.5 cm in width. The right adrenal gland measured 0.48 cm in width.

### Spleen

Normal size and echogenic appearance. Smooth homogenous parenchyma and regular curvilinear capsule. Normal volume of the splenic vasculature without any overt congestion or thrombosis evident. No inflammatory, neoplastic, infarction, or infiltrative changes evident. The spleen measured 2.0 cm in width.

### Liver

Normal size, echogenic appearance, portal markings, and regular curvilinear capsule. No nodules or masses evident. Normal appearance of the hepatic and portal vasculature.



## PATIENT

Rosie Ianni

## SPECIES

Canine

## BREED

Golden Retriever

## SEX

Spayed female

## AGE

12 years

## WEIGHT

70 lbs

## INTERPRETED BY

Remo Lobetti, BVSc,  
MMedVet (Med),  
PhD, Dipl. ECVIM

## IMAGING PERFORMED BY

Brandi Kurzowski

## HOSPITAL NAME

Corfu VC

## REFERRING VET

Dr. Gardner

## INVOICE

70318

## DATE

1/20/26

## Gallbladder

The gallbladder is full containing normal anechoic bile. Normal thickness and echogenic appearance of the wall. Normal size and appearance of the cystic and common bile duct.

## Gastrointestinal

Normal appearance of the stomach, duodenum, small intestine, ileo-cecal junction, and colon with no loss of layering, 1:3 muscularis to mucosa ratio, normal wall thickness and peristaltic activity, and no distension of the lumen.

## Pancreas

The visible sections of the pancreas are of normal size and echogenic appearance with a regular capsule. Normal echogenic appearance of the mesentery and fat surrounding the pancreas.

## Free Abdomen

Normal mesenteric lymph nodes.

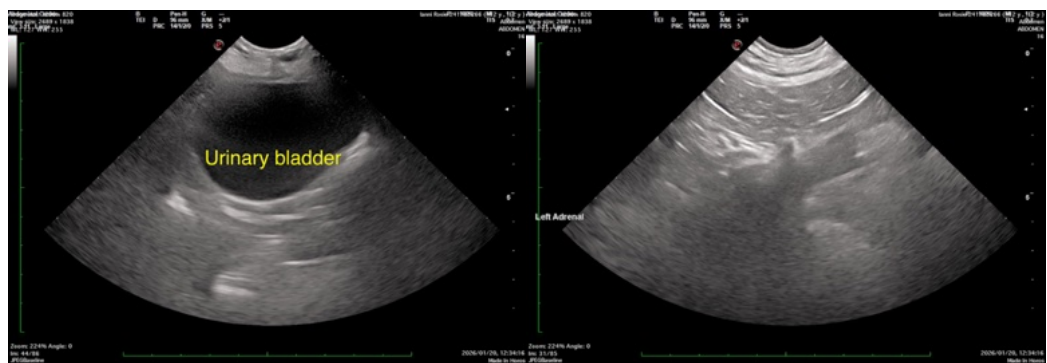No ascites evident.

## ULTRASONOGRAPHIC FINDINGS

- Normal ultrasound examination of the abdomen.

## INTERPRETATION OF THE FINDINGS & FURTHER RECOMMENDATIONS

No specific therapy is recommended at this time.





## PATIENT

Rosie Ianni

## SPECIES

Canine

## BREED

Golden Retriever

## SEX

Spayed female

## AGE

12 years

## WEIGHT

70 lbs

## INTERPRETED BY

Remo Lobetti, BVSc,  
MMedVet (Med),  
PhD, Dipl. ECVIM

## IMAGING PERFORMED BY

Brandi Kurzowski

## HOSPITAL NAME

Corfu VC

## REFERRING VET

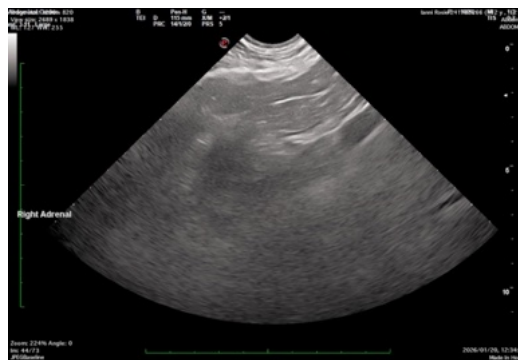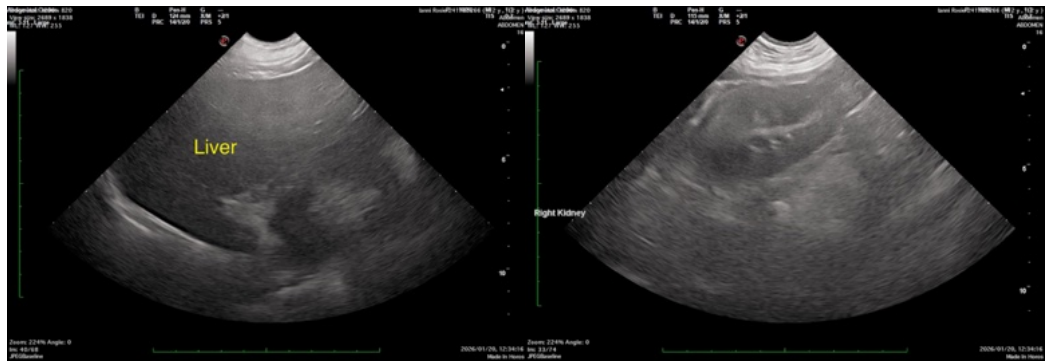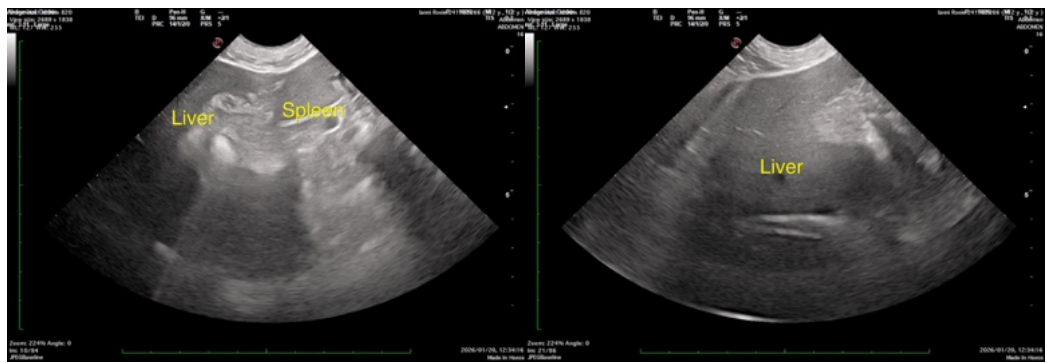
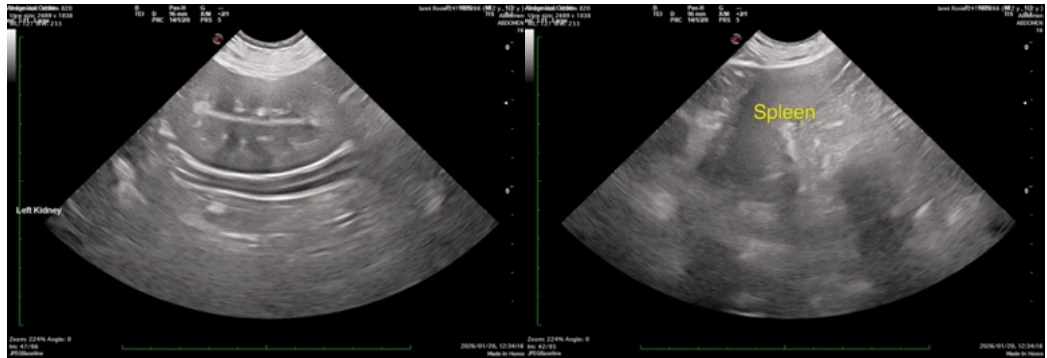
Dr. Gardner

## INVOICE

70318

## DATE

1/20/26



The information and recommendations provided are based on the images presented by the referring veterinarian/sonographer. No evaluation can be communicated regarding pathology



## PATIENT

Rosie Ianni

## SPECIES

Canine

## BREED

Golden Retriever

## SEX

Spayed female

## AGE

12 years

## WEIGHT

70 lbs

## INTERPRETED BY

Remo Lobetti, BVSc,  
MMedVet (Med),  
PhD, Dipl. ECVIM

## IMAGING PERFORMED BY

Brandi Kurzowski

## HOSPITAL NAME

Corfu VC

## REFERRING VET

Dr. Gardner

## INVOICE

70318

## DATE

1/20/26

that was not visible in the image/video clips provided.

Thank you for this referral. If the clinical or image interpretation does not parallel your findings or if I can be of any further assistance please contact me.

Remo Lobetti, BVSc, MMedVet (Med), PhD, Dipl. ECVIM (Internal Medicine)

[info@sonopath.com](mailto:info@sonopath.com)