



## PATIENT

Eli Cuff

## SPECIES

Canine

## BREED

Boxer Mix

## SEX

Neutered male

## AGE

11 years

## WEIGHT

65.2 lbs

## PRESENTING CLINICAL SIGNS

Copper storage. On telmisartan, penicillamine D, Denamarin, on prescription LD food. Slight anemia, RBC - 465, UPC - 1.1, ALT - 153, ALP - 496

## ULTRASONOGRAPHIC EXAMINATION OF THE ABDOMEN

### *Urinary System*

The urinary bladder is small with a normal thickness and smooth appearance of the wall. Normal anechoic urine with no sediment or uroliths evident.

Normal appearance of the trigone area, proximal urethra, and iliac blood vessels.

Normal appearance and size of the iliac lymph nodes. Ureters not visualized, which can be considered a normal finding.

Normal renal size (left measured 6.5 cm, right measured 6.2 cm), architecture, echogenic appearance, cortico-medullary differentiation, which maintains a 1:3 cortex to medulla ratio, pelvis, and capsule. No infarcts, mineralization or renoliths evident. Normal color flow pattern is evident in both kidneys.

The prostate is small and hypoechogenic.

## INTERPRETED BY

Remo Lobetti, BVSc,  
MMedVet (Med),  
PhD, Dipl. ECVIM

### *Adrenal Glands*

The adrenal glands are not clearly visualized, but appear to be of normal shape, echogenic appearance and size.

## IMAGING PERFORMED BY

Heather

### *Spleen*

The spleen is not visualized.

## HOSPITAL NAME

Animal Care Center of  
Flanders

### *Liver*

Normal size, echogenic appearance, portal markings, and regular curvilinear capsule. No nodules or masses evident. Normal appearance of the hepatic and portal vasculature.

## REFERRING VET

Dr. Villari

### *Gallbladder*

The gallbladder is full containing normal anechoic bile. Normal thickness and echogenic appearance of the wall. Normal size and appearance of the cystic and common bile duct.

## INVOICE

70317

## DATE

1/20/26



**PATIENT**

Eli Cuff

**SPECIES**

Canine

**BREED**

Boxer Mix

**SEX**

Neutered male

**AGE**

11 years

**WEIGHT**

65.2 lbs

**INTERPRETED BY**

Remo Lobetti, BVSc,  
MMedVet (Med),  
PhD, Dipl. ECVIM

**IMAGING PERFORMED BY**

Heather

**HOSPITAL NAME**

Animal Care Center of  
Flanders

**REFERRING VET**

Dr. Villari

**INVOICE**

70317

**DATE**

1/20/26

**Gastrointestinal**

Normal appearance of the stomach, duodenum, small intestine, ileo-cecal junction, and colon with no loss of layering, 1:3 muscularis to mucosa ratio, normal wall thickness and peristaltic activity, and no distension of the lumen.

**Pancreas**

The visible sections of the pancreas are of normal size and echogenic appearance with a regular capsule. Normal echogenic appearance of the mesentery and fat surrounding the pancreas.

**Free Abdomen**

Normal mesenteric lymph nodes.

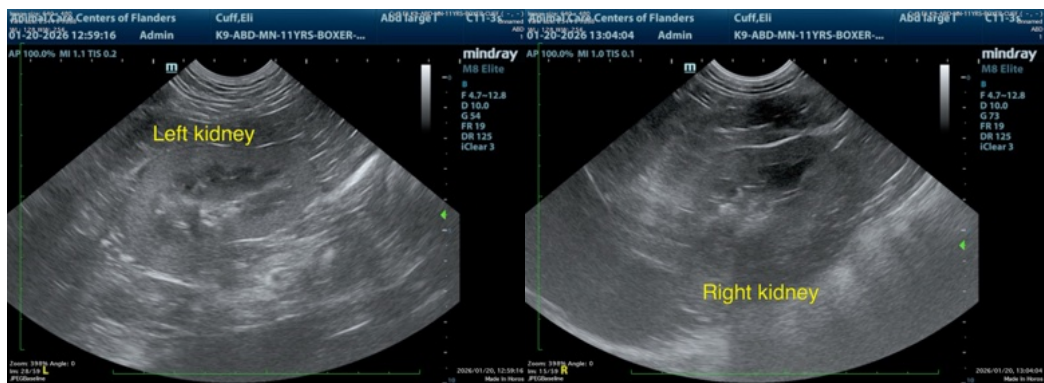
No ascites evident.

**ULTRASONOGRAPHIC FINDINGS**

- Normal ultrasound examination of the abdomen.

**INTERPRETATION OF THE FINDINGS & FURTHER RECOMMENDATIONS**

No specific therapy is recommended at this time.





**PATIENT**

Eli Cuff

**SPECIES**

Canine

**BREED**

Boxer Mix

**SEX**

Neutered male

**AGE**

11 years

**WEIGHT**

65.2 lbs

**INTERPRETED BY**

Remo Lobetti, BVSc,  
MMedVet (Med),  
PhD, Dipl. ECVIM

**IMAGING PERFORMED BY**

Heather

**HOSPITAL NAME**

Animal Care Center of  
Flanders

**REFERRING VET**

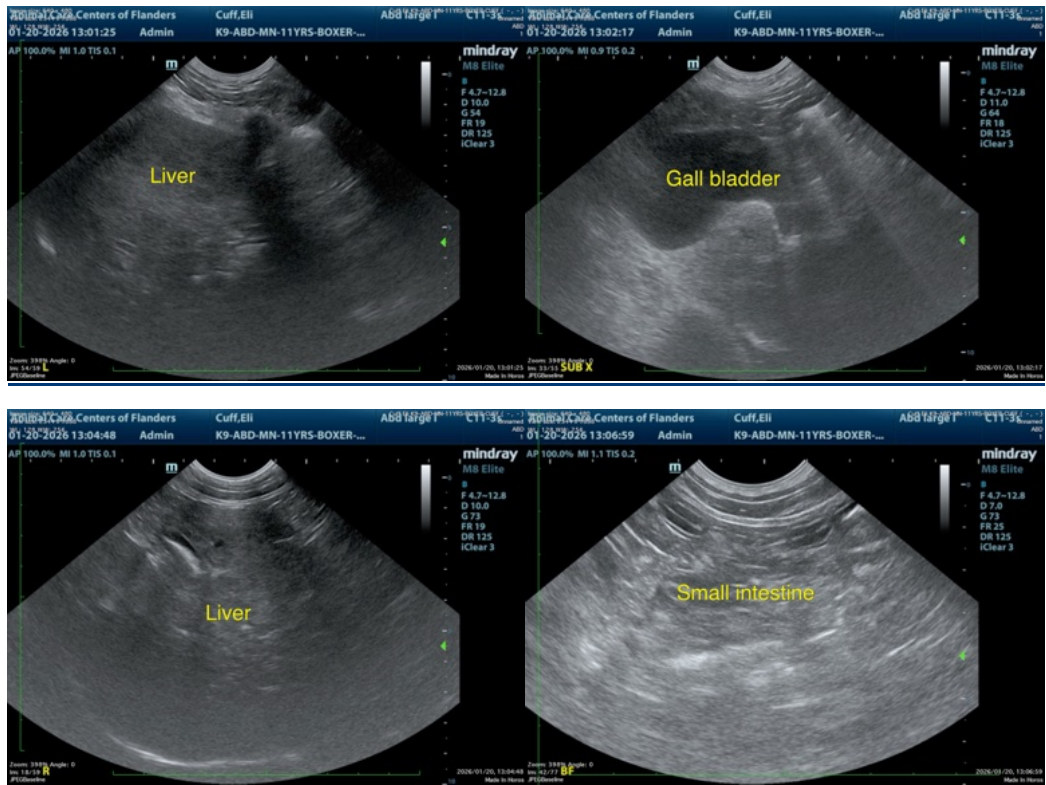
Dr. Villari

**INVOICE**

70317

**DATE**

1/20/26



The information and recommendations provided are based on the images presented by the referring veterinarian/sonographer. No evaluation can be communicated regarding pathology that was not visible in the image/video clips provided.

Thank you for this referral. If the clinical or image interpretation does not parallel your findings or if I can be of any further assistance please contact me.

Remo Lobetti, BVSc, MMedVet (Med), PhD, Dipl. ECVIM (Internal Medicine)

[info@sonopath.com](mailto:info@sonopath.com)