



PATIENT

Cody reymann

SPECIES

Feline

BREED

DSH

SEX

MN

AGE

19 years

WEIGHT

9 lbs

INTERPRETED BY

Remo Lobetti, BVSc,
MMedVet (Med),
PhD, Dipl. ECVIM

IMAGING PERFORMED BY

Dr. Jessica Boudreaux-
Milligan

HOSPITAL NAME

Dockside Veterinary
Imaging

REFERRING VET

Dr. Kristen Swanson

INVOICE

11022

DATE

1/2/2026

PRESENTING CLINICAL SIGNS

Recent onset peritoneal effusion (approx 3wks ago), chronic. Was recently seen at ER and approx 700ml serosanguinous fluid removed from abdomen. On exam today, patient has severely distended abdomen, distended abdominal skin vessels, and focal ecchymosis at recent abdominal injection sites.

Abnormal PE/Chem/CBC/UA Results: No aspirates performed today. See recent hx attached (12-24-25: abnormal CBC, chem, TT4, Feline Coronavirus Antibody by IFA 1:100)

ULTRASONOGRAPHIC EXAMINATION OF THE ABDOMEN

Urinary System

Full urinary bladder with a normal thickness and smooth appearance of the wall. Normal anechoic urine with no sediment or uroliths evident.

Normal appearance of the trigone area, proximal urethra, and iliac blood vessels.

Normal appearance and size of the iliac lymph nodes. Ureters not visualized, which can be considered a normal finding.

Both kidneys are of increased echogenic appearance, some loss of cortico-medullary differentiation, which maintains a 1:3 cortex to medulla ratio. Normal pelvis, and capsule. No infarcts, mineralization or renoliths evident. Left kidney is enlarged, measuring 4.6 cm. Right kidney is normal in size, measuring 3.4 cm.

Adrenal Glands

Right adrenal gland is normal shape, echogenic appearance, size, position, and appearance of the visible peri-adrenal vasculature. Right adrenal measures 0.58 cm in width.

Left adrenal gland is not visualized.

Spleen

Enlarged in size with a diffuse increased echogenic appearance but maintaining a regular curvilinear capsule. Few hypoechoic parenchymal nodules measuring up to 0.9 cm x 1.0 cm in size. The spleen measures 2.0 cm in width.

Liver

Normal size with a diffuse increased echogenic and coarse appearance, loss of portal markings, and regular curvilinear capsule. No nodules or masses evident. Normal appearance of the hepatic and portal vasculature.

Gallbladder

Small containing normal anechoic bile. Normal thickness and echogenic appearance of the wall. Normal size and appearance of the cystic and common bile duct.

Gastrointestinal



PATIENT

Cody reymann

Normal appearance of the stomach, duodenum, small intestine, ileo-cecal junction, and colon with no loss of layering, 1:3 muscularis to mucosa ratio, normal wall thickness and peristaltic activity, and no distension of the lumen.

SPECIES

Feline

Pancreas

Normal size and echogenic appearance. Regular capsule. Normal echogenic appearance of the mesentery and fat surrounding the pancreas.

BREED

DSH

Free Abdomen

Enlarged mesenteric lymph nodes measuring up to 0.7 cm x 1.3 cm in size. Maintaining a normal shape and echogenic appearance.

SEX

MN

Large amount of cellular ascites present.

AGE

19 years

ULTRASONOGRAPHIC FINDINGS

- Splenomegaly.
- Hepatopathy.
- Mesenteric lymphadenomegaly.
- Ascites.
- Age related adrenal changes versus a chronic kidney disease.

WEIGHT

9 lbs

INTERPRETED BY

Remo Lobetti, BVSc,
MMedVet (Med),
PhD, Dipl. ECVIM

INTERPRETATION OF THE FINDINGS & FURTHER RECOMMENDATIONS

The most likely diagnosis for this patient would be neoplasia with sterile or bacterial peritonitis less likely differential diagnoses.

Further assessment would be analysis of the ascitic fluid and FNA cytology of the spleen, mesenteric lymph nodes, and liver.

IMAGING PERFORMED BY

Dr. Jessica Boudreaux-
Milligan

Specific therapy would be dependent on an etiological diagnosis.

HOSPITAL NAME

Dockside Veterinary
Imaging

At this point, palliative therapy is most likely indicated.

REFERRING VET

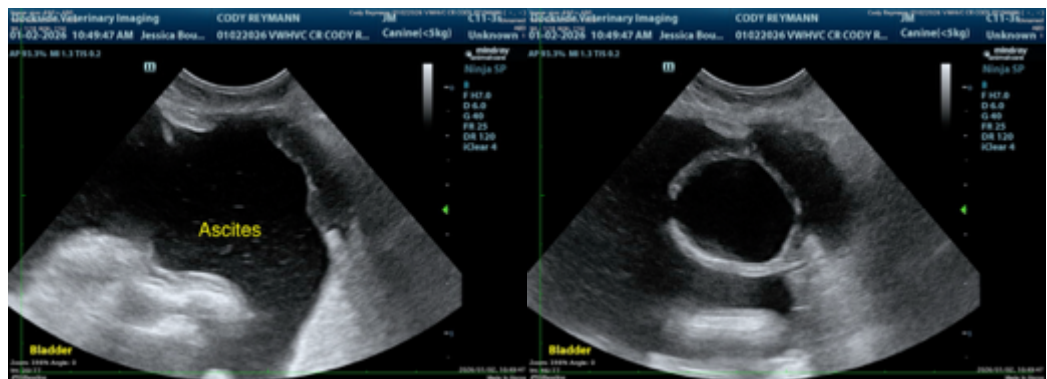
Dr. Kristen Swanson

INVOICE

11022

DATE

1/2/2026





PATIENT

Cody reymann

SPECIES

Feline

BREED

DSH

SEX

MN

AGE

19 years

WEIGHT

9 lbs

INTERPRETED BY

Remo Lobetti, BVSc,
MMedVet (Med),
PhD, Dipl. ECVIM

IMAGING PERFORMED BY

Dr. Jessica Boudreaux-
Milligan

HOSPITAL NAME

Dockside Veterinary
Imaging

REFERRING VET

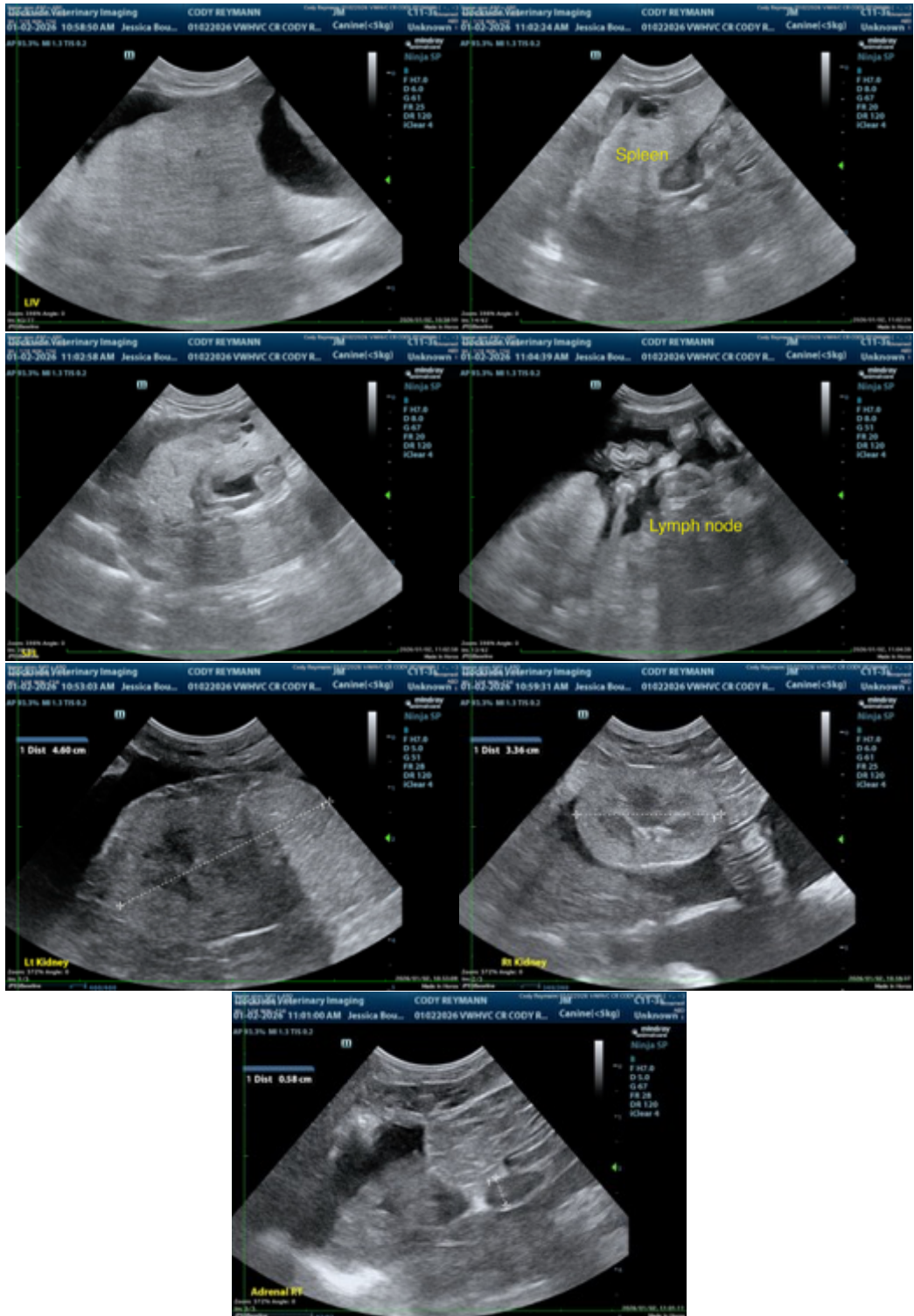
Dr. Kristen Swanson

INVOICE

11022

DATE

1/2/2026





PATIENT

Cody reymann

SPECIES

Feline

BREED

DSH

SEX

MN

AGE

19 years

WEIGHT

9 lbs

INTERPRETED BY

Remo Lobetti, BVSc,
MMedVet (Med),
PhD, Dipl. ECVIM

IMAGING PERFORMED BY

Dr. Jessica Boudreaux-
Milligan

HOSPITAL NAME

Dockside Veterinary
Imaging

REFERRING VET

Dr. Kristen Swanson

INVOICE

11022

DATE

1/2/2026

The information and recommendations provided are based on the images presented by the referring veterinarian. No evaluation can be communicated regarding pathology that was not visible in the image/video clips provided.

Thank you for this referral. If the clinical or image interpretation does not parallel your findings or if I can be of any further assistance, please contact me.

Remo Lobetti, BVSc, MMedVet (Med), PhD, Dipl. ECVIM (Internal Medicine)

info@sonopath.com