



## PATIENT

Zoey Bully

## SPECIES

Canine

## BREED

Pitbull

## SEX

Spayed female

## AGE

16 years

## WEIGHT

46.2 lbs

## INTERPRETED BY

Remo Lobetti, BVSc,  
MMedVet (Med),  
PhD, Dipl. ECVIM

## IMAGING PERFORMED BY

Dr. Morgan

## HOSPITAL NAME

Seven Fields VH

## REFERRING VET

Dr. Morgan

## INVOICE

70246

## DATE

1/19/26

## PRESENTING CLINICAL SIGNS

- This owner has only had her for a few months; doing well at home outside of mobility concerns. She was adopted on prednisone for anemia but that's all we know. She presented for a tooth root abscess and rec'd imaging prior to anesthesia due to unknown cause of anemia

## ULTRASONOGRAPHIC EXAMINATION OF THE ABDOMEN

### Urinary System

The urinary bladder is small with a normal thickness and smooth appearance of the wall. Normal anechoic urine with no sediment or uroliths evident.

Normal appearance of the trigone area, proximal urethra, and iliac blood vessels.

Normal appearance and size of the iliac lymph nodes. Ureters not visualized, which can be considered a normal finding.

Normal renal size (left measured 5.5 cm, right measured 6.6 cm), architecture, echogenic appearance, cortico-medullary differentiation, which maintains a 1:3 cortex to medulla ratio, pelvis, and capsule. No infarcts, mineralization or renoliths evident.

### Adrenal Glands

Normal shape, echogenic appearance, size, position, and appearance of the visible peri-adrenal vasculature. Left adrenal gland measured 0.55 cm and 0.44 cm in width. The right adrenal gland measured 0.56 cm in width.

### Spleen

Normal size and echogenic appearance. Smooth homogenous parenchyma and regular curvilinear capsule. Normal volume of the splenic vasculature without any overt congestion or thrombosis evident. No inflammatory, neoplastic, infarction, or infiltrative changes evident. The spleen measured 2.0 cm in width.

### Liver

Normal size, echogenic appearance, portal markings, and regular curvilinear capsule. No nodules or masses evident. Normal appearance of the hepatic and portal vasculature.

### Gallbladder

The gallbladder is small containing normal anechoic bile. Normal thickness and echogenic appearance of the wall. Normal size and appearance of the cystic and common bile duct.



**PATIENT**

Zoey Bully

**SPECIES**

Canine

**BREED**

Pitbull

**SEX**

Spayed female

**AGE**

16 years

**WEIGHT**

46.2 lbs

**INTERPRETED BY**

Remo Lobetti, BVSc,  
MMedVet (Med),  
PhD, Dipl. ECVIM

**IMAGING PERFORMED BY**

Dr. Morgan

**HOSPITAL NAME**

Seven Fields VH

**REFERRING VET**

Dr. Morgan

**INVOICE**

70246

**DATE**

1/19/26

**Gastrointestinal**

Normal appearance of the stomach, duodenum, small intestine, ileo-cecal junction, and colon with no loss of layering, 1:3 muscularis to mucosa ratio, normal wall thickness and peristaltic activity, and no distension of the lumen. A large amount of fluid is present in the stomach. Fecal material is present in the colon.

**Pancreas**

The visible sections of the pancreas are of normal size and echogenic appearance with a regular capsule. Normal echogenic appearance of the mesentery and fat surrounding the pancreas.

**Free Abdomen**

Normal mesenteric lymph nodes.  
No ascites evident.

**ULTRASONOGRAPHIC FINDINGS**

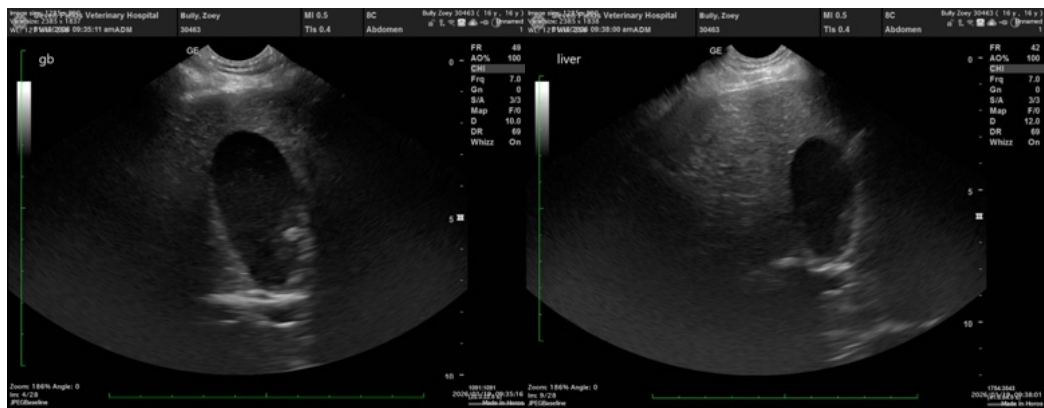- Normal ultrasound examination of the abdomen as the fluid filled stomach can be considered an incidental finding.

**INTERPRETATION OF THE FINDINGS & FURTHER RECOMMENDATIONS**

On this ultrasound there is no obvious etiology for the anemia.

Further assessment of the anemia needs to be based on the classification of the anemia (regenerative versus non-regenerative, normochromic versus hypochromic, microcystic versus macrocystic).

Specific therapy would be dependent on an etiological diagnosis.





**PATIENT**

Zoey Bully

**SPECIES**

Canine

**BREED**

Pitbull

**SEX**

Spayed female

**AGE**

16 years

**WEIGHT**

46.2 lbs

**INTERPRETED BY**

Remo Lobetti, BVSc,  
MMedVet (Med),  
PhD, Dipl. ECVIM

**IMAGING PERFORMED BY**

Dr. Morgan

**HOSPITAL NAME**

Seven Fields VH

**REFERRING VET**

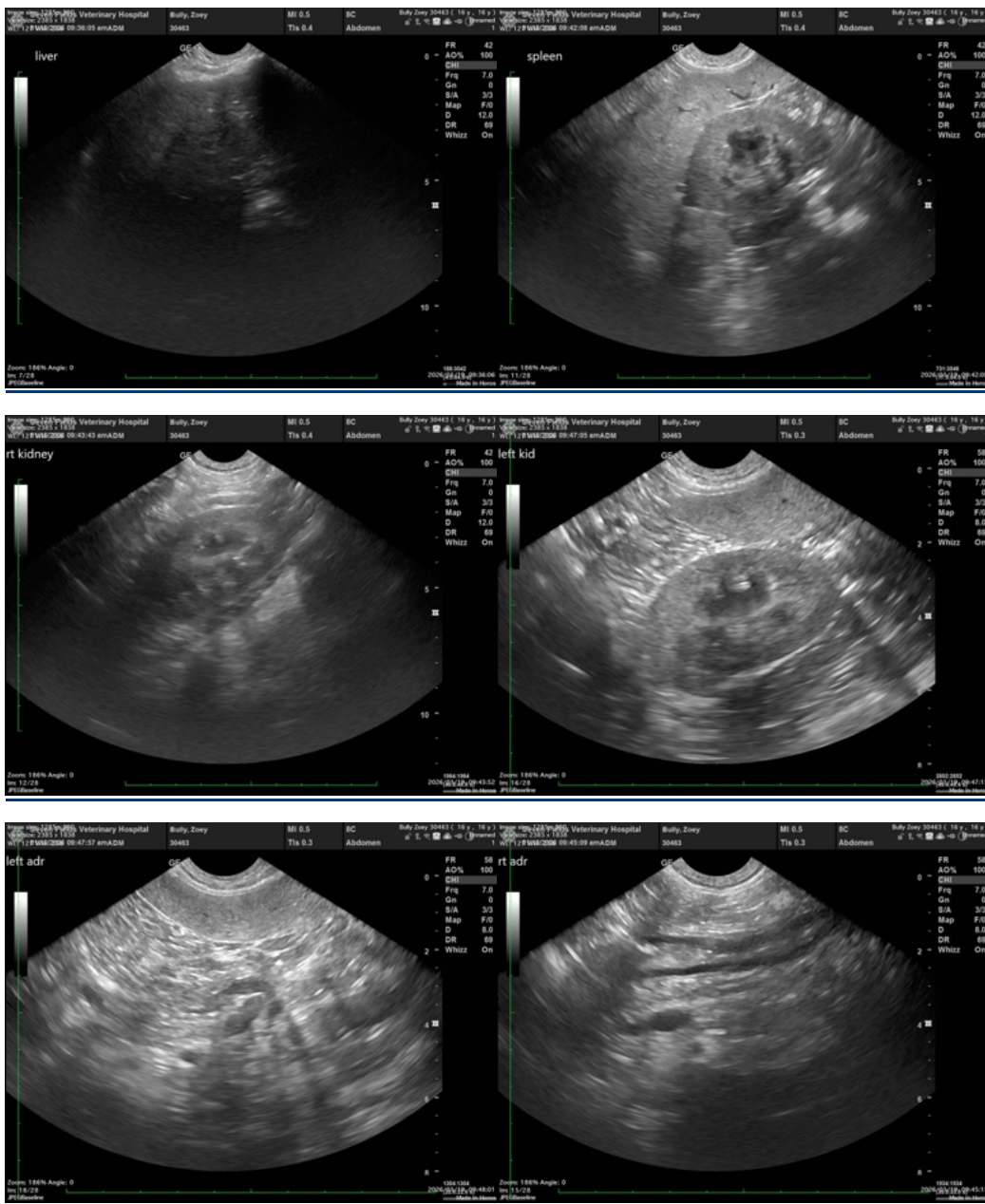
Dr. Morgan

**INVOICE**

70246

**DATE**

1/19/26





**PATIENT**

Zoey Bully

**SPECIES**

Canine

**BREED**

Pitbull

**SEX**

Spayed female

**AGE**

16 years

**WEIGHT**

46.2 lbs

**INTERPRETED BY**

Remo Lobetti, BVSc,  
MMedVet (Med),  
PhD, Dipl. ECVIM

**IMAGING PERFORMED BY**

Dr. Morgan

**HOSPITAL NAME**

Seven Fields VH

**REFERRING VET**

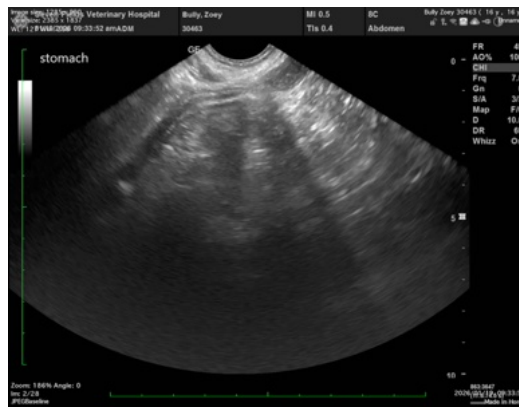
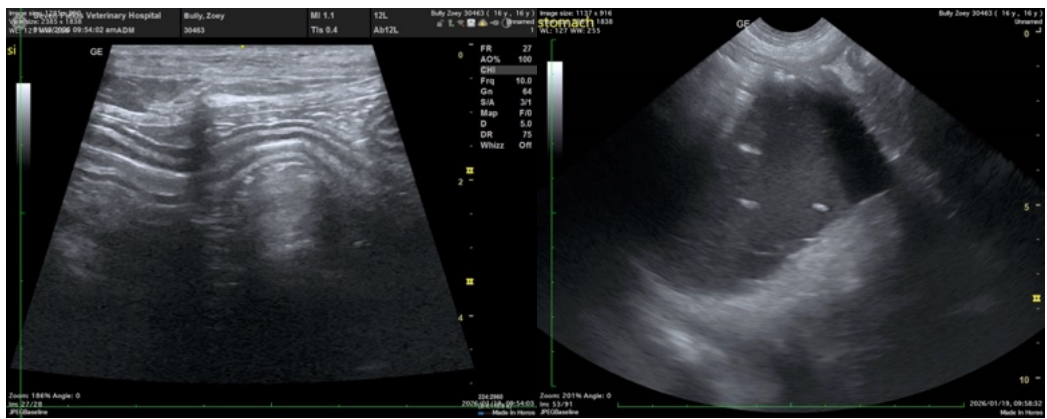
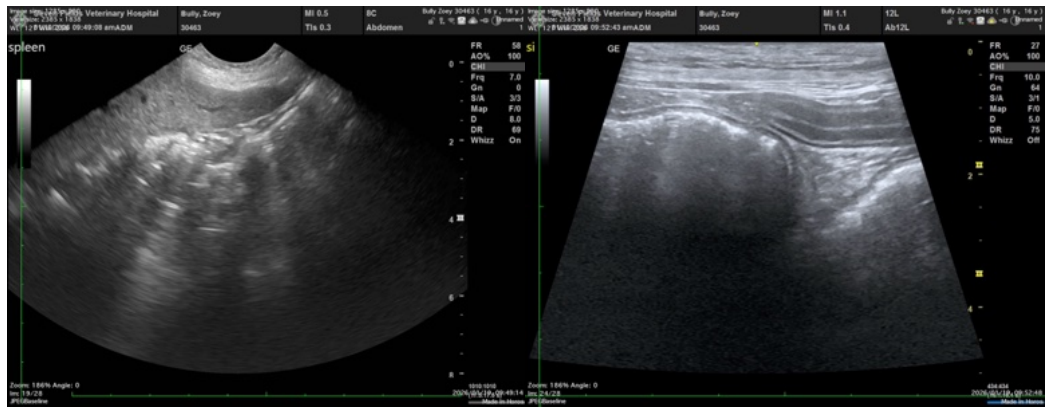
Dr. Morgan

**INVOICE**

70246

**DATE**

1/19/26



The information and recommendations provided are based on the images presented by the referring veterinarian/sonographer. No evaluation can be communicated regarding pathology that was not visible in the image/video clips provided.

Thank you for this referral. If the clinical or image interpretation does not parallel your findings or if I can be of any further assistance please contact me.

Remo Lobetti, BVSc, MMedVet (Med), PhD, Dipl. ECVIM (Internal Medicine)

[info@sonopath.com](mailto:info@sonopath.com)