

PATIENT

Bosco Phair

SPECIES

Canine

BREED

Bichon Shih Tzu Mix

SEX

Neutered male

AGE

11 years

WEIGHT

17.3 lbs

INTERPRETED BY

Remo Lobetti, BVSc,
MMedVet (Med),
PhD, Dipl. ECVIM

IMAGING PERFORMED BY

Dr. Wagner

HOSPITAL NAME

Angeles Clinic for
Animals

REFERRING VET

Dr. Wagner

INVOICE

70286

DATE

1/19/26

PRESENTING CLINICAL SIGNS

- Owner reports intermittent overnight bilious vomiting
- Bladder stones noted on u/s guided cysto
- CBC - NSF Chem - NSF - BUN 15, Creat 1.1 UA - USG 1.021, 1+ protein, benign sediment T4 - 1.7

ULTRASONOGRAPHIC EXAMINATION OF THE ABDOMEN

Urinary System

The urinary bladder is full with a normal thickness and smooth appearance of the wall. Normal anechoic urine with no sediment evident. A focal urolith measuring 0.8 cm is present.

Normal appearance of the trigone area, proximal urethra, and iliac blood vessels.

Normal appearance and size of the iliac lymph nodes. Ureters not visualized, which can be considered a normal finding.

Normal renal size (left measured 3.8 cm, right measured 3.6 cm), architecture, echogenic appearance, cortico-medullary differentiation, which maintains a 1:3 cortex to medulla ratio, pelvis, and capsule. No infarcts, mineralization or renoliths evident. Normal color flow pattern is evident in both kidneys.

The prostate is small and hypoechogenic measuring 0.5 cm in width.

Adrenal Glands

Normal shape, echogenic appearance, size, position, and appearance of the visible peri-adrenal vasculature. Left adrenal gland measured 0.4 cm and 0.45 cm in width. The right adrenal gland measured 0.49 cm and 0.48 cm in width.

Spleen

Normal size and echogenic appearance. Smooth homogenous parenchyma and regular curvilinear capsule. Normal volume of the splenic vasculature without any overt congestion or thrombosis evident. No inflammatory, neoplastic, infarction, or infiltrative changes evident. The spleen measured 1.7 cm in width.

Liver

Normal size, echogenic appearance, portal markings, and regular curvilinear capsule. No nodules or masses evident. Normal appearance of the hepatic and portal vasculature.



PATIENT

Bosco Phair

SPECIES

Canine

BREED

Bichon Shih Tzu Mix

SEX

Neutered male

AGE

11 years

WEIGHT

17.3 lbs

INTERPRETED BY

Remo Lobetti, BVSc,
MMedVet (Med),
PhD, Dipl. ECVIM

IMAGING PERFORMED BY

Dr. Wagner

HOSPITAL NAME

Angeles Clinic for
Animals

REFERRING VET

Dr. Wagner

INVOICE

70286

DATE

1/19/26

Gallbladder

The gallbladder is full containing normal anechoic bile. Normal thickness and echogenic appearance of the wall. Normal size and appearance of the cystic and common bile duct.

Gastrointestinal

Normal appearance of the stomach, duodenum, small intestine, ileo-cecal junction, and colon with no loss of layering, 1:3 muscularis to mucosa ratio, normal wall thickness and peristaltic activity, and no distension of the lumen.

Pancreas

The visible sections of the pancreas are of normal size and echogenic appearance with a regular capsule. Normal echogenic appearance of the mesentery and fat surrounding the pancreas.

Free Abdomen

Normal mesenteric lymph nodes.

No ascites evident.

ULTRASONOGRAPHIC FINDINGS

- Urolith.

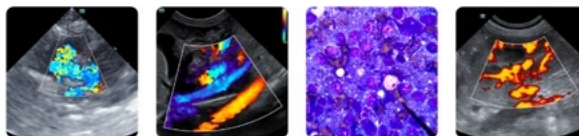
INTERPRETATION OF THE FINDINGS & FURTHER RECOMMENDATIONS

On this ultrasound there is no obvious etiology for the intermittent vomiting.

Vomiting bilious syndrome would be the most likely diagnosis and although the GI tract appears ultrasonographically normal, differential diagnosis would be chronic gastritis, Helicobacter gastritis, parasitic gastroenteritis, inflammatory bowel disease and dietary hypersensitivity.

Further assessment would be fecal analysis, cobalamin and folate assay and endoscopy of the upper GI tract with biopsies.

Specific therapy would be dependent on an etiological diagnosis. Management of the urolith would either be surgical removal or medical dissolution.



PATIENT

Bosco Phair

SPECIES

Canine

BREED

Bichon Shih Tzu Mix

SEX

Neutered male

AGE

11 years

WEIGHT

17.3 lbs

INTERPRETED BY

Remo Lobetti, BVSc,
MMedVet (Med),
PhD, Dipl. ECVIM

IMAGING PERFORMED BY

Dr. Wagner

HOSPITAL NAME

Angeles Clinic for
Animals

REFERRING VET

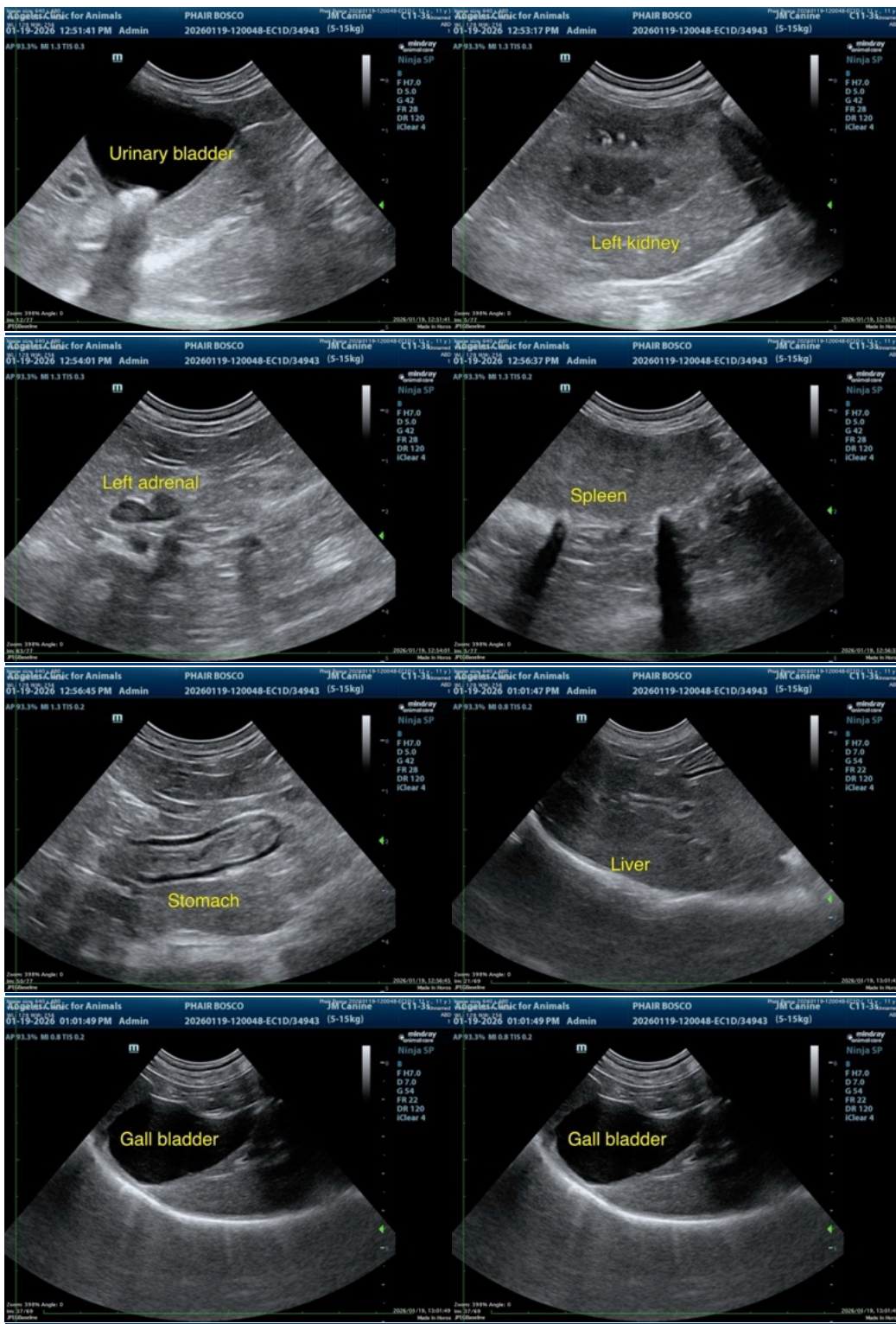
Dr. Wagner

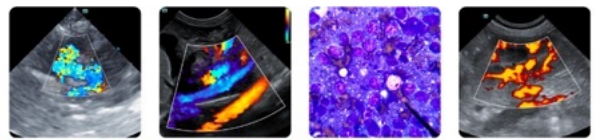
INVOICE

70286

DATE

1/19/26





PATIENT

Bosco Phair

SPECIES

Canine

BREED

Bichon Shih Tzu Mix

SEX

Neutered male

AGE

11 years

WEIGHT

17.3 lbs

INTERPRETED BY

Remo Lobetti, BVSc,
MMedVet (Med),
PhD, Dipl. ECVIM

IMAGING PERFORMED BY

Dr. Wagner

HOSPITAL NAME

Angeles Clinic for
Animals

REFERRING VET

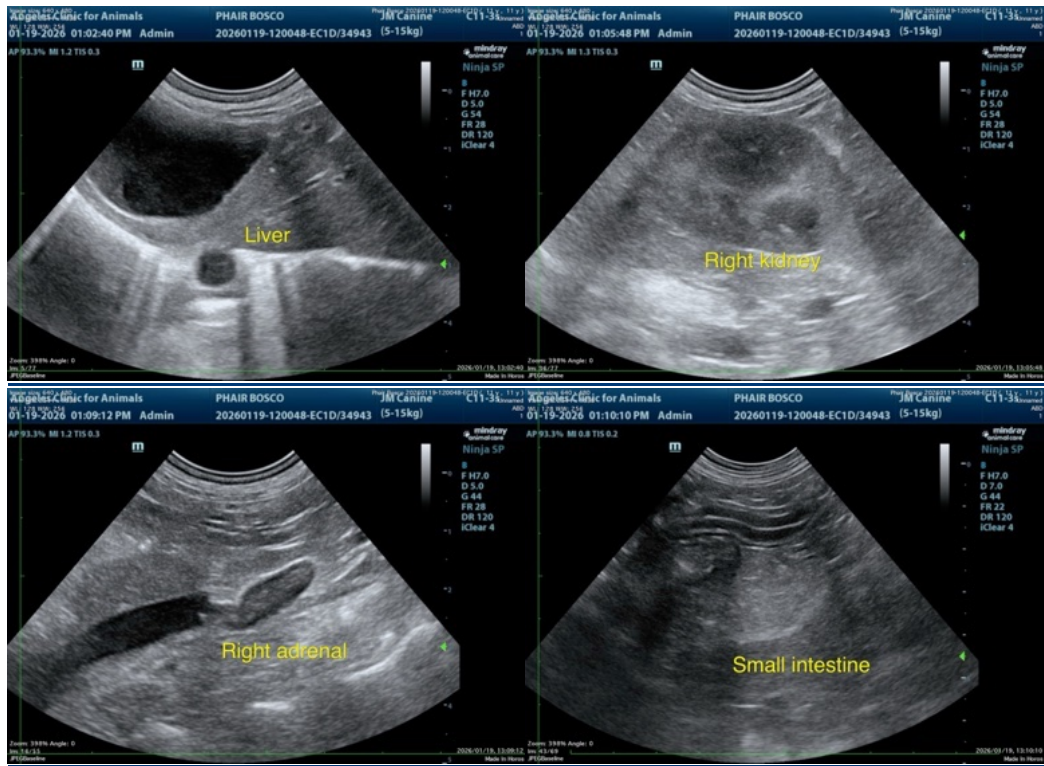
Dr. Wagner

INVOICE

70286

DATE

1/19/26



The information and recommendations provided are based on the images presented by the referring veterinarian/sonographer. No evaluation can be communicated regarding pathology that was not visible in the image/video clips provided.

Thank you for this referral. If the clinical or image interpretation does not parallel your findings or if I can be of any further assistance please contact me.

Remo Lobetti, BVSc, MMedVet (Med), PhD, Dipl. ECVIM (Internal Medicine)

info@sonopath.com