



## PATIENT

Piper Fischer

## SPECIES

Canine

## BREED

Labrador Cross

## SEX

Spayed female

## AGE

9 months

## WEIGHT

38 lbs

## INTERPRETED BY

Remo Lobetti, BVSc,  
MMedVet (Med),  
PhD, Dipl. ECVIM

## IMAGING PERFORMED BY

Dr. Coe

## HOSPITAL NAME

Riverside Animal Clinic

## REFERRING VET

Dr. Brenner

## INVOICE

70211

## DATE

1/16/26

## PRESENTING CLINICAL SIGNS

History: Grape ingestion in 8/17/2025 - Seen/treated at MSU CVM - induced emesis (3 grapes retrieved...5 grapes thought to be ingested). Activated charcoal. Renal panel at that time WNL (not complete chemistry). No clinical signs/complaints from owner. Never has been food-motivated. No vomiting. Normal BMs.

Brought to us on 8/18/25 to recheck chemistry. Complete chemistry done, showed ALT 119, but rest WRI. Chemistry repeated 8/20/25 - still elevated ALT (102). Rest WRI. Chemistry repeated 1/7/2026 (not fasted) - ALT 298, ALKP 314, GGT 37. TBili WRI. Alb WRI. Gluc WRI. HW-4DX = Negative. Bile acids testing 1/8/2026: Both pre and post-prandial WRI.

## ULTRASONOGRAPHIC EXAMINATION OF THE ABDOMEN

### *Urinary System*

The urinary bladder is small with a normal thickness and smooth appearance of the wall. Normal anechoic urine with no sediment or uroliths evident.

Normal appearance of the trigone area, proximal urethra, and iliac blood vessels.

Normal appearance and size of the iliac lymph nodes. Ureters not visualized, which can be considered a normal finding.

Normal renal size (left measured 5.0 cm, right measured 5.1 cm), architecture, echogenic appearance, cortico-medullary differentiation, which maintains a 1:3 cortex to medulla ratio, pelvis, and capsule. No infarcts, mineralization or renoliths evident. Normal color flow pattern is evident in both kidneys.

### *Adrenal Glands*

Normal shape, echogenic appearance, size, position, and appearance of the visible peri-adrenal vasculature. Left adrenal gland measured 2.04 cm x 0.38 cm and 0.35 cm in width. The right adrenal gland measured 3.11 cm in length x 0.79 cm and 0.97 cm in width.

### *Spleen*

Normal size and echogenic appearance. Smooth homogenous parenchyma and regular curvilinear capsule. Normal volume of the splenic vasculature without any overt congestion or thrombosis evident. No inflammatory, neoplastic, infarction, or infiltrative changes evident. The spleen measured 2.8 cm in width.

### *Liver*

Normal size, echogenic appearance, portal markings, and regular curvilinear capsule. No nodules or masses evident. Normal appearance of the hepatic and portal vasculature.



## PATIENT

Piper Fischer

## SPECIES

Canine

## BREED

Labrador Cross

## SEX

Spayed female

## AGE

9 months

## WEIGHT

38 lbs

## INTERPRETED BY

Remo Lobetti, BVSc,  
MMedVet (Med),  
PhD, Dipl. ECVIM

## IMAGING PERFORMED BY

Dr. Coe

## HOSPITAL NAME

Riverside Animal Clinic

## REFERRING VET

Dr. Brenner

## INVOICE

70211

## DATE

1/16/26

## ***Gallbladder***

The gallbladder is small containing normal anechoic bile. Normal thickness and echogenic appearance of the wall. Normal size and appearance of the cystic and common bile duct.

## ***Gastrointestinal***

Normal appearance of the stomach, duodenum, small intestine, ileo-cecal junction, and colon with no loss of layering, 1:3 muscularis to mucosa ratio, normal wall thickness and peristaltic activity, and no distension of the lumen.

## ***Pancreas***

The visible sections of the pancreas are of normal size and echogenic appearance with a regular capsule. Normal echogenic appearance of the mesentery and fat surrounding the pancreas.

## ***Free Abdomen***

Normal mesenteric lymph nodes.

No ascites evident.

## **ULTRASONOGRAPHIC FINDINGS**

- Normal ultrasound examination of the abdomen.

## **INTERPRETATION OF THE FINDINGS & FURTHER RECOMMENDATIONS**

On this ultrasound there is no obvious etiology for the elevated liver enzyme activity.

Although the liver appears ultrasonographically normal, an underlying hepatopathy such as reactive hyperplasia, vacuolar and metabolic and breed specific hepatopathy should be considered.

Further assessment would be FNA cytology of the liver. However, a tru cut or wedge biopsy may be required for a final etiological diagnosis.

Specific therapy would be dependent on an etiological diagnosis.

Symptomatic management that can be considered would be the use of Ursodiol with regular monitoring of liver enzyme activity.



**PATIENT**

Piper Fischer

**SPECIES**

Canine

**BREED**

Labrador Cross

**SEX**

Spayed female

**AGE**

9 months

**WEIGHT**

38 lbs

**INTERPRETED BY**

Remo Lobetti, BVSc,  
MMedVet (Med),  
PhD, Dipl. ECVIM

**IMAGING PERFORMED BY**

Dr. Coe

**HOSPITAL NAME**

Riverside Animal Clinic

**REFERRING VET**

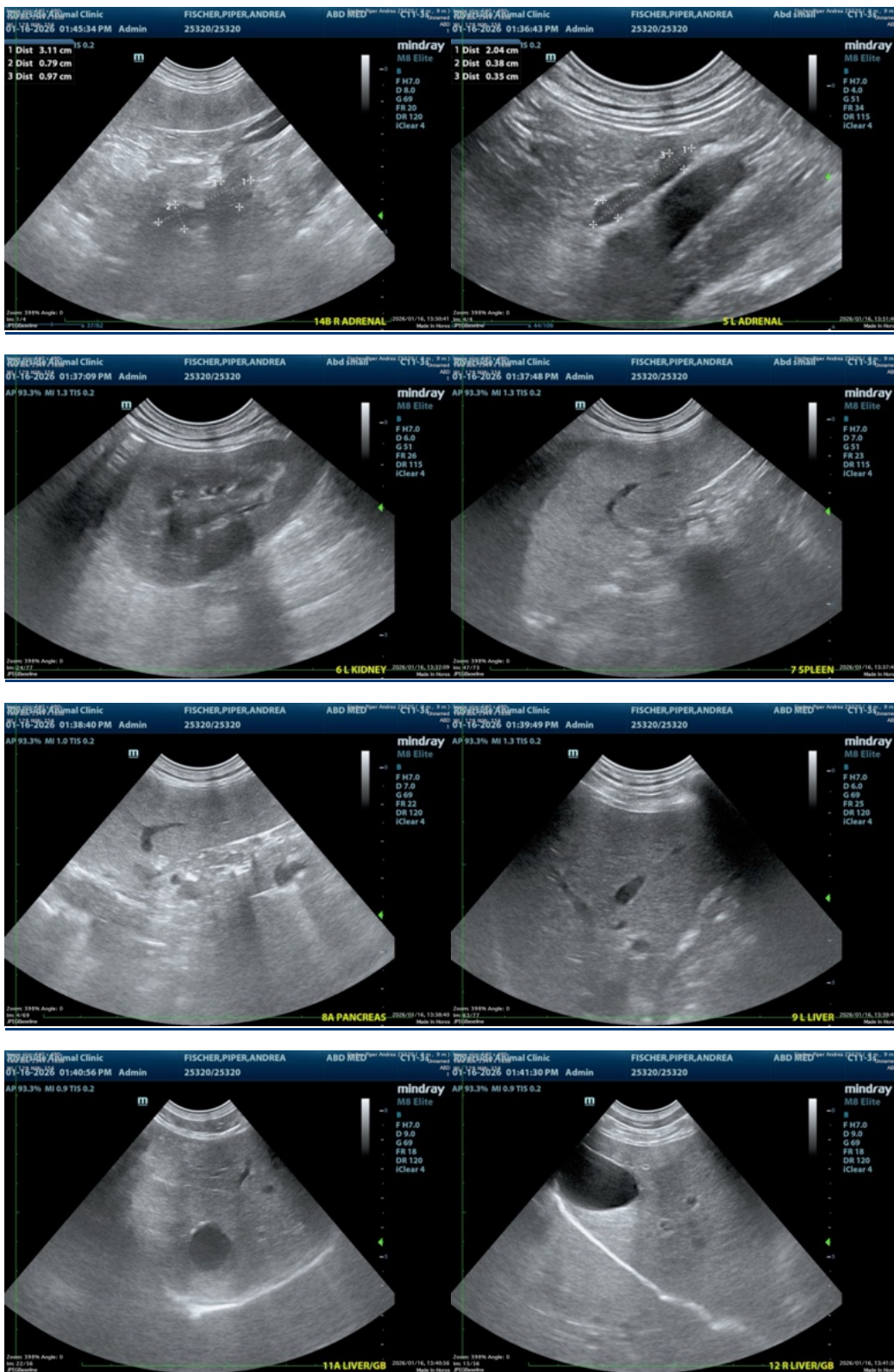
Dr. Brenner

**INVOICE**

70211

**DATE**

1/16/26





## PATIENT

Piper Fischer

## SPECIES

Canine

## BREED

Labrador Cross

## SEX

Spayed female

## AGE

9 months

## WEIGHT

38 lbs

## INTERPRETED BY

Remo Lobetti, BVSc,  
MMedVet (Med),  
PhD, Dipl. ECVIM

## IMAGING PERFORMED BY

Dr. Coe

## HOSPITAL NAME

Riverside Animal Clinic

## REFERRING VET

Dr. Brenner

## INVOICE

70211

## DATE

1/16/26

The information and recommendations provided are based on the images presented by the referring veterinarian/sonographer. No evaluation can be communicated regarding pathology that was not visible in the image/video clips provided.

Thank you for this referral. If the clinical or image interpretation does not parallel your findings or if I can be of any further assistance please contact me.

Remo Lobetti, BVSc, MMedVet (Med), PhD, Dipl. ECVIM (Internal Medicine)

[info@sonopath.com](mailto:info@sonopath.com)