



PATIENT

Caico Pease

SPECIES

Canine

BREED

Labrador Cross

SEX

Male

AGE

10 ½ years

WEIGHT

49.2 lbs

INTERPRETED BY

Remo Lobetti, BVSc,
MMedVet (Med),
PhD, Dipl. ECVIM

IMAGING PERFORMED BY

Dr. Schmieder

HOSPITAL NAME

Slade VH

REFERRING VET

Dr. Schmieder

INVOICE

70186

DATE

1/15/26

PRESENTING CLINICAL SIGNS

History: Recurrent GI issues x 2 months. This dog is extremely aggressive and complete physicals are not possible without sedation which the owner declined until today. Unlabeled images of a testicular type mass in the scrotal area on this reportedly neutered male.

ULTRASONOGRAPHIC EXAMINATION OF THE ABDOMEN

Urinary System

The urinary bladder is full with a normal thickness and smooth appearance of the wall. Normal anechoic urine with no sediment or uroliths evident.

Normal appearance of the trigone area, proximal urethra, and iliac blood vessels.

Normal appearance and size of the iliac lymph nodes. Ureters not visualized, which can be considered a normal finding.

Normal renal size (left measured 5.2 cm, right measured 5.0 cm), architecture, echogenic appearance, cortico-medullary differentiation, which maintains a 1:3 cortex to medulla ratio, pelvis, and capsule. No infarcts, mineralization or renoliths evident. Normal color flow pattern is evident in both kidneys. A few, small, bilateral cortical cysts are present.

The prostate is small and hypoechogenic measuring 0.8 cm in width. A hyperechogenic scrotal mass measuring 3.0 x 5.6 cm in size is noted.

Adrenal Glands

The left adrenal gland is normal in shape, echogenic appearance, size, position, and appearance of the visible peri-adrenal vasculature. Left adrenal gland measured 0.85 cm in width. The right adrenal gland was not visualized.

Spleen

The visible sections of the spleen are of normal size and echogenic appearance with a smooth homogenous parenchyma and regular curvilinear capsule. The spleen measured 1.4 cm in width.

Liver

Normal size, echogenic appearance, portal markings, and regular curvilinear capsule. No nodules or masses evident. Normal appearance of the hepatic and portal vasculature.

Gallbladder

The gallbladder is small containing normal anechoic bile. Normal thickness and echogenic appearance of the wall. Normal size and appearance of the cystic and common bile duct.



PATIENT

Caico Pease

SPECIES

Canine

BREED

Labrador Cross

SEX

Male

AGE

10 ½ years

WEIGHT

49.2 lbs

INTERPRETED BY

Remo Lobetti, BVSc,
MMedVet (Med),
PhD, Dipl. ECVIM

IMAGING PERFORMED BY

Dr. Schmieder

HOSPITAL NAME

Slade VH

REFERRING VET

Dr. Schmieder

INVOICE

70186

DATE

1/15/26

Gastrointestinal

Normal appearance of the stomach, duodenum, small intestine, ileo-cecal junction, and colon with no loss of layering, 1:3 muscularis to mucosa ratio, normal wall thickness and peristaltic activity, and no distension of the lumen.

Pancreas

The visible sections of the pancreas are of normal size and echogenic appearance with a regular capsule. Normal echogenic appearance of the mesentery and fat surrounding the pancreas.

Free Abdomen

Normal mesenteric lymph nodes.

No ascites evident.

Large, irregular, hyperechoic mass measuring 5.0 x 5.3 cm in size in the cranial midabdomen and possibly originating from the spleen.

ULTRASONOGRAPHIC FINDINGS

- Abdominal mass.
- Scrotal mass.

INTERPRETATION OF THE FINDINGS & FURTHER RECOMMENDATIONS

The most likely etiology for the scrotal and abdominal mass would be neoplasia with granulomatous disease a possible differential diagnosis.

Further assessment would be three view thoracic radiographs and FNA cytology of the masses.

Specific therapy would be dependent on an etiological diagnosis.

If surgery is being contemplated then a CT scan would ideally be recommended.



PATIENT

Caico Pease

SPECIES

Canine

BREED

Labrador Cross

SEX

Male

AGE

10 ½ years

WEIGHT

49.2 lbs

INTERPRETED BY

Remo Lobetti, BVSc,
MMedVet (Med),
PhD, Dipl. ECVIM

IMAGING PERFORMED BY

Dr. Schmieder

HOSPITAL NAME

Slade VH

REFERRING VET

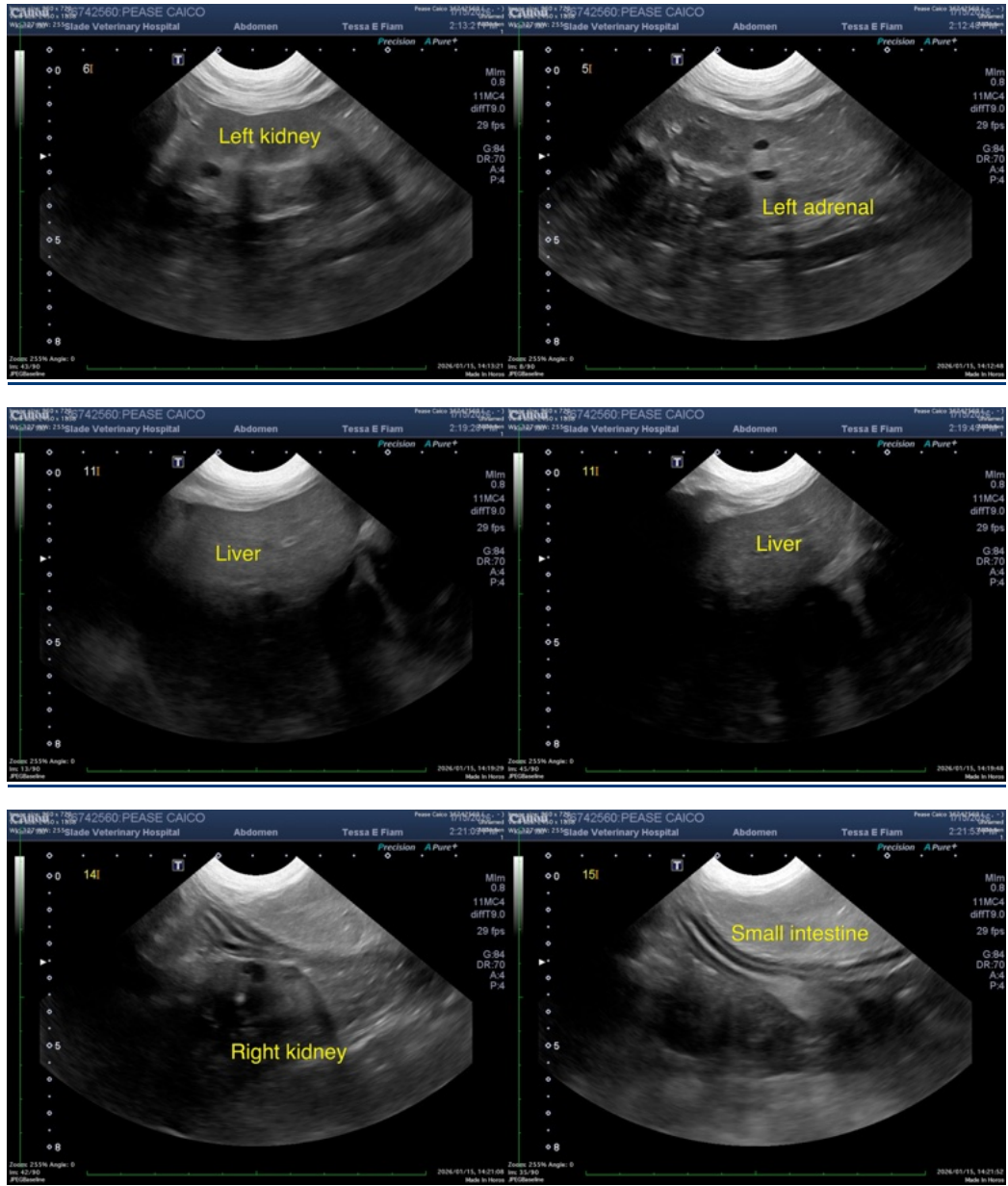
Dr. Schmieder

INVOICE

70186

DATE

1/15/26





PATIENT

Caico Pease

SPECIES

Canine

BREED

Labrador Cross

SEX

Male

AGE

10 ½ years

WEIGHT

49.2 lbs

INTERPRETED BY

Remo Lobetti, BVSc,
MMedVet (Med),
PhD, Dipl. ECVIM

IMAGING PERFORMED BY

Dr. Schmieder

HOSPITAL NAME

Slade VH

REFERRING VET

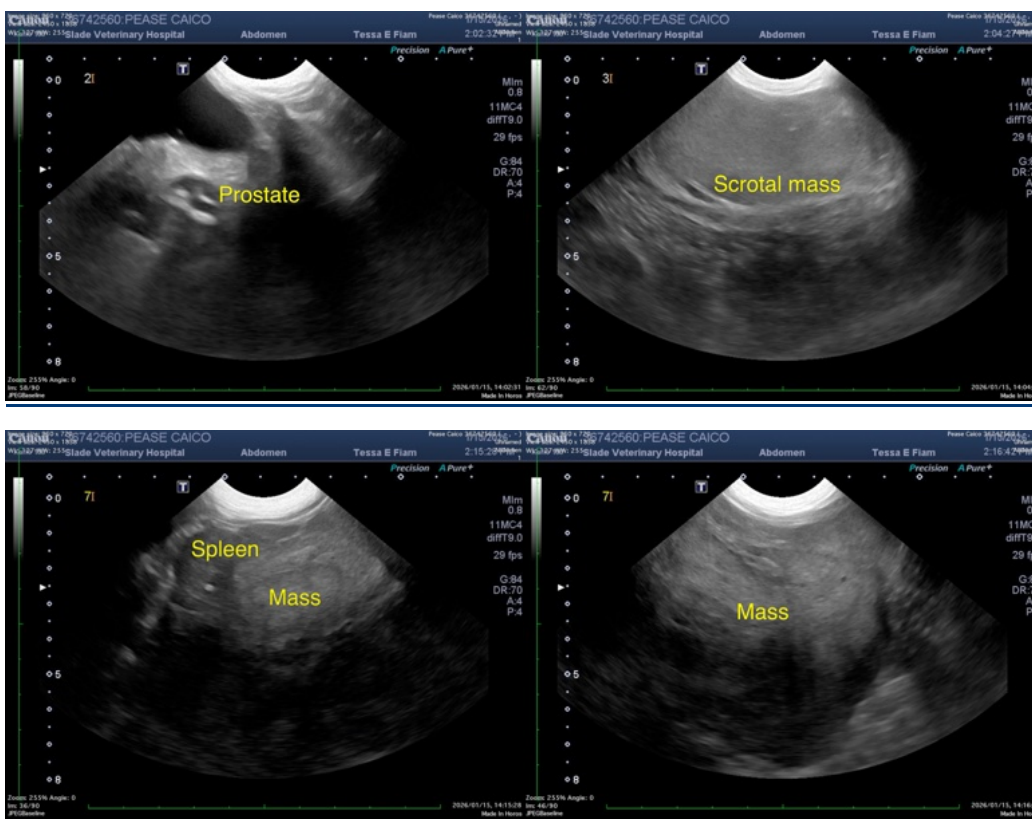
Dr. Schmieder

INVOICE

70186

DATE

1/15/26



The information and recommendations provided are based on the images presented by the referring veterinarian/sonographer. No evaluation can be communicated regarding pathology that was not visible in the image/video clips provided.

Thank you for this referral. If the clinical or image interpretation does not parallel your findings or if I can be of any further assistance please contact me.

Remo Lobetti, BVSc, MMedVet (Med), PhD, Dipl. ECVIM (Internal Medicine)

info@sonopath.com