



PATIENT

Justice Cummings

SPECIES

Canine

BREED

Rottie Mix

SEX

Neutered male

AGE

9 years

WEIGHT

53 lbs

INTERPRETED BY

Remo Lobetti, BVSc,
MMedVet (Med),
PhD, Dipl. ECVIM

IMAGING PERFORMED BY

Dr. Casita

HOSPITAL NAME

CompanionAH

REFERRING VET

Dr. Casita/Flanagan

INVOICE

70013

DATE

1/12/26

PRESENTING CLINICAL SIGNS

History: 1/2: presented for 2 episodes of V, weight loss, some mild behavior changes has been normal since tense abd for exam, no other abnormalities on exam

Abnormal PE/Chem/CBC/UA Results: 1/2/25: ALT (SGPT) 199 (HIGH) 12-118 IU/L ALK PHOS 1,906 (HIGH) 5-131 Rest WNL 12/2/2024: ALP 982

ULTRASONOGRAPHIC EXAMINATION OF THE ABDOMEN

Urinary System

The urinary bladder is small with a normal thickness and smooth appearance of the wall. Normal anechoic urine with no sediment or uroliths evident.

Normal appearance of the trigone area, proximal urethra, and iliac blood vessels.

Normal appearance and size of the iliac lymph nodes. Ureters not visualized, which can be considered a normal finding.

Normal renal size (left measured 6.5 cm, right measured 6.7 cm), architecture, echogenic appearance, cortico-medullary differentiation, which maintains a 1:3 cortex to medulla ratio, pelvis, and capsule. No infarcts, mineralization or renoliths evident.

The prostate is small and hypoechogenic.

Adrenal Glands

Normal shape, echogenic appearance, size, position, and appearance of the visible peri-adrenal vasculature. Left adrenal gland measured 0.46 cm and 0.55 cm in width. The right adrenal gland measured 0.5 cm in width.

Spleen

Normal size and echogenic appearance. Smooth homogenous parenchyma and regular curvilinear capsule. Normal volume of the splenic vasculature without any overt congestion or thrombosis evident. No inflammatory, neoplastic, infarction, or infiltrative changes evident. The spleen measured 2.3 cm in width.

Liver

Normal size with a diffuse, increased echogenic and coarse appearance, prominent portal markings, and regular curvilinear capsule. No nodules or masses evident. Normal appearance of the hepatic and portal vasculature.



PATIENT

Justice Cummings

SPECIES

Canine

BREED

Rottie Mix

SEX

Neutered male

AGE

9 years

WEIGHT

53 lbs

INTERPRETED BY

Remo Lobetti, BVSc,
MMedVet (Med),
PhD, Dipl. ECVIM

IMAGING PERFORMED BY

Dr. Casita

HOSPITAL NAME

CompanionAH

REFERRING VET

Dr. Casita/Flanagan

INVOICE

70013

DATE

1/12/26

Gallbladder

The gallbladder is full containing normal anechoic bile. Normal thickness and echogenic appearance of the wall. Normal size and appearance of the cystic and common bile duct.

Gastrointestinal

Normal appearance of the stomach, duodenum, small intestine, ileo-cecal junction, and colon with no loss of layering, 1:3 muscularis to mucosa ratio, normal wall thickness and peristaltic activity, and no distension of the lumen.

Pancreas

The visible sections of the pancreas are of normal size and echogenic appearance with a regular capsule. Normal echogenic appearance of the mesentery and fat surrounding the pancreas.

Free Abdomen

Normal mesenteric lymph nodes.

No ascites evident.

ULTRASONOGRAPHIC FINDINGS

- Hepatopathy.

INTERPRETATION OF THE FINDINGS & FURTHER RECOMMENDATIONS

Etiologies for the hepatopathy would be reactive hyperplasia, early nodular hyperplasia, vacuolar and metabolic with hepatitis and infiltrative neoplasia an unlikely differential diagnosis.

Further assessment would be FNA cytology of the liver; however, a tru cut or wedge biopsy may be required for a final etiological diagnosis.

Specific therapy would be dependent on an etiological diagnosis.

Symptomatic management would be the use of Ursodiol with regular monitoring of liver enzyme activity.



PATIENT

Justice Cummings

SPECIES

Canine

BREED

Rottie Mix

SEX

Neutered male

AGE

9 years

WEIGHT

53 lbs

INTERPRETED BY

Remo Lobetti, BVSc,
MMedVet (Med),
PhD, Dipl. ECVIM

IMAGING PERFORMED BY

Dr. Casita

HOSPITAL NAME

CompanionAH

REFERRING VET

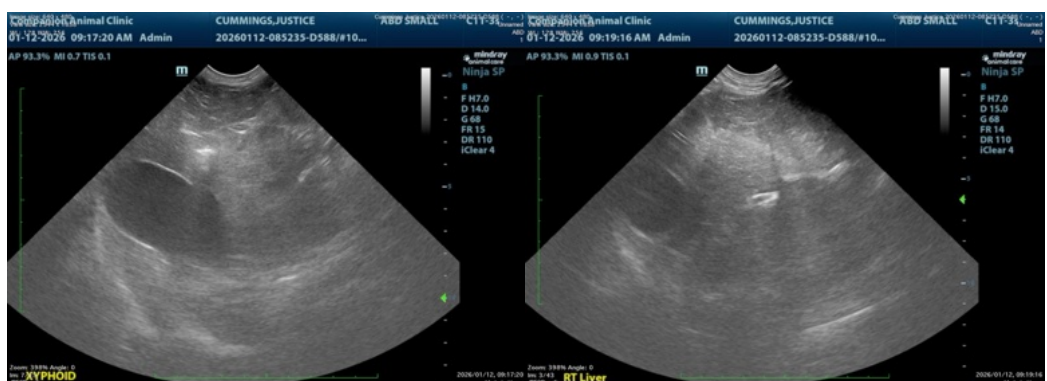
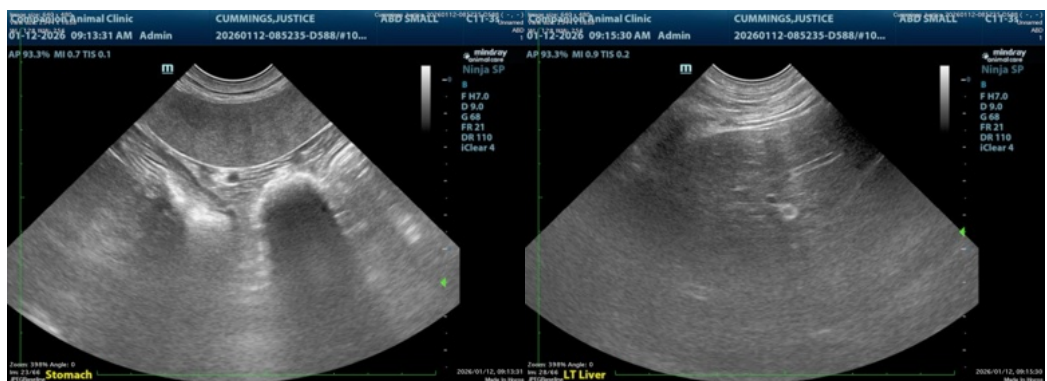
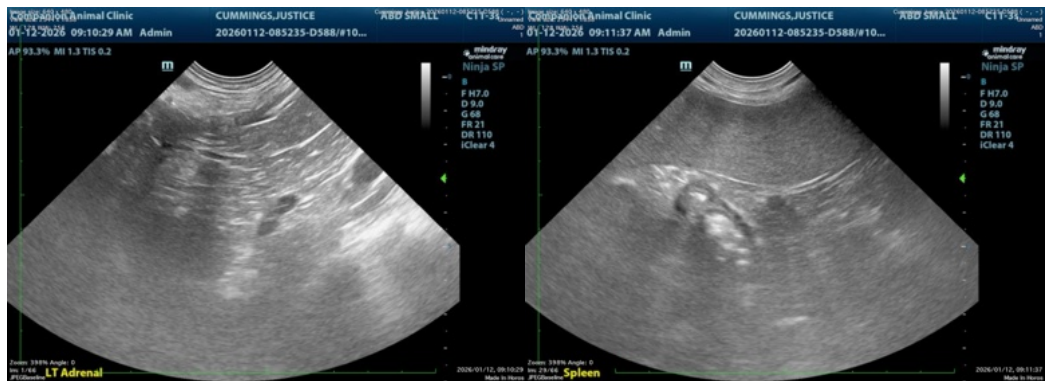
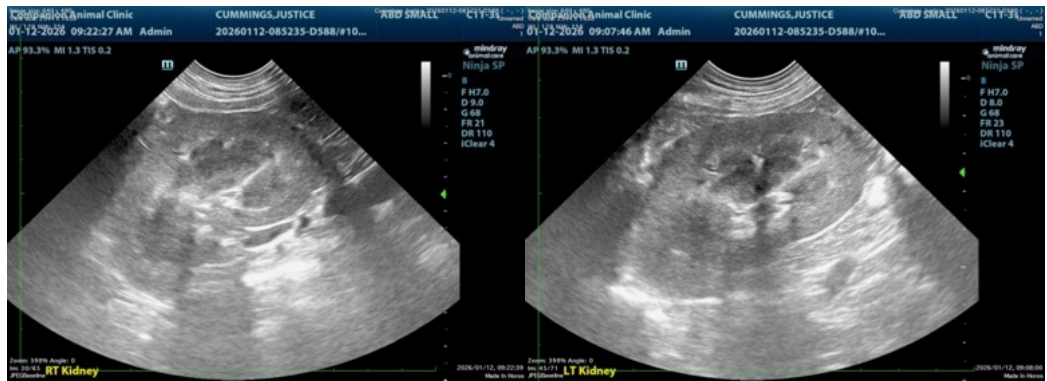
Dr. Casita/Flanagan

INVOICE

70013

DATE

1/12/26





PATIENT

Justice Cummings

SPECIES

Canine

BREED

Rottie Mix

SEX

Neutered male

AGE

9 years

WEIGHT

53 lbs

INTERPRETED BY

Remo Lobetti, BVSc,
MMedVet (Med),
PhD, Dipl. ECVIM

IMAGING PERFORMED BY

Dr. Casita

HOSPITAL NAME

CompanionAH

REFERRING VET

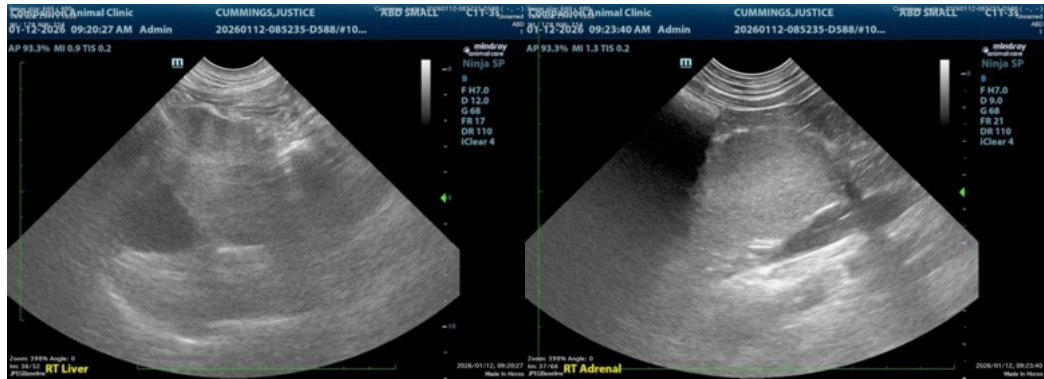
Dr. Casita/Flanagan

INVOICE

70013

DATE

1/12/26



The information and recommendations provided are based on the images presented by the referring veterinarian/sonographer. No evaluation can be communicated regarding pathology that was not visible in the image/video clips provided.

Thank you for this referral. If the clinical or image interpretation does not parallel your findings or if I can be of any further assistance please contact me.

Remo Lobetti, BVSc, MMedVet (Med), PhD, Dipl. ECVIM (Internal Medicine)

info@sonopath.com