



PATIENT

Bella Luna Ford

SPECIES

Canine

BREED

Boxer

SEX

Spayed female

AGE

10 years

WEIGHT

50 lbs

INTERPRETED BY

Remo Lobetti, BVSc,
MMedVet (Med),
PhD, Dipl. ECVIM

IMAGING PERFORMED BY

Dr. Reser

HOSPITAL NAME

Harvest Hills VH

REFERRING VET

Dr. Reser

INVOICE

70029

DATE

1/12/26

PRESENTING CLINICAL SIGNS

History: Dog has been vomiting for past 2 weeks, will eat, but vomits after each time. Prev. rads at ER were inconclusive. Has lost approx 15 pounds
Abnormal PE/Chem/CBC/UA Results: Dog is thin, BCS 3/9, ER labs were all normal. Dog is QAR< not painful in abdomen. No prev. treatment given so far.

ULTRASONOGRAPHIC EXAMINATION OF THE ABDOMEN

Urinary System

The urinary bladder is small with a normal thickness and smooth appearance of the wall. Normal anechoic urine with no sediment or uroliths evident.

Normal appearance of the trigone area, proximal urethra, and iliac blood vessels.

Normal appearance and size of the iliac lymph nodes. Ureters not visualized, which can be considered a normal finding.

Normal renal size (left measured 5.6 cm, right measured 6.4 cm), architecture, echogenic appearance, cortico-medullary differentiation, which maintains a 1:3 cortex to medulla ratio, pelvis, and capsule. No infarcts, mineralization or renoliths evident.

Adrenal Glands

Normal shape, echogenic appearance, size, position, and appearance of the visible peri-adrenal vasculature. Left adrenal gland measured 0.5 cm in width. The right adrenal gland measured 0.3 cm in width.

Spleen

Normal size and echogenic appearance. Smooth homogenous parenchyma and regular curvilinear capsule. Normal volume of the splenic vasculature without any overt congestion or thrombosis evident. No inflammatory, neoplastic, infarction, or infiltrative changes evident. The spleen measured 1.5 cm in width.

Liver

Normal size, echogenic appearance, portal markings, and regular curvilinear capsule. No nodules or masses evident. Normal appearance of the hepatic and portal vasculature.

Gallbladder

The gallbladder is full containing normal anechoic bile. Normal thickness and echogenic appearance of the wall. Normal size and appearance of the cystic and common bile duct.



PATIENT

Bella Luna Ford

SPECIES

Canine

BREED

Boxer

SEX

Spayed female

AGE

10 years

WEIGHT

50 lbs

INTERPRETED BY

Remo Lobetti, BVSc,
MMedVet (Med),
PhD, Dipl. ECVIM

IMAGING PERFORMED BY

Dr. Reser

HOSPITAL NAME

Harvest Hills VH

REFERRING VET

Dr. Reser

INVOICE

70029

DATE

1/12/26

Gastrointestinal

Normal thickness of the gastric wall with no loss of layering and maintaining a 1:3 muscularis to mucosa ratio. A moderate amount of gas and fluid was present in the stomach as well as a small amount of ill-defined, foreign material. The small intestines and colon were unremarkable with normal curvilinear mural patterns and content. Fecal material is present in the colon.

Pancreas

Normal size and echogenic appearance with a regular capsule. Normal echogenic appearance of the mesentery and fat surrounding the pancreas.

Free Abdomen

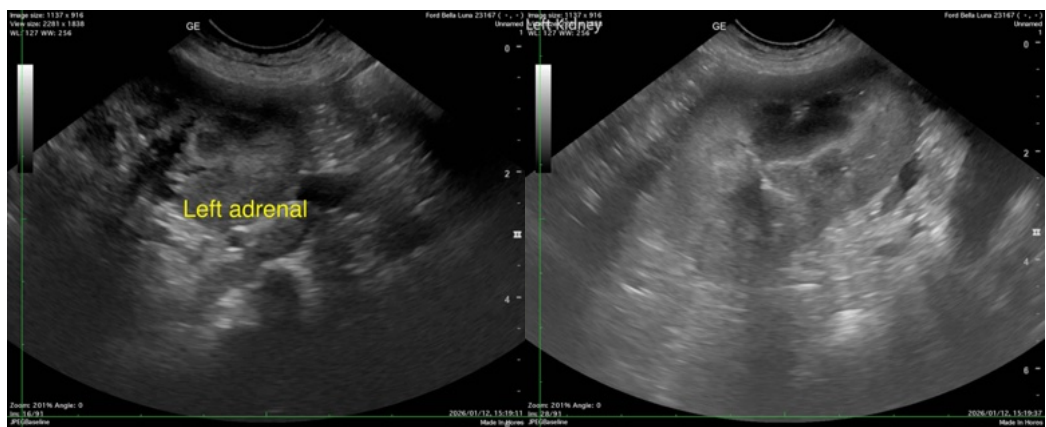
Normal mesenteric lymph nodes.
No ascites evident.

ULTRASONOGRAPHIC FINDINGS

- Gastric foreign body.

INTERPRETATION OF THE FINDINGS & FURTHER RECOMMENDATIONS

Further assessment and therapy would be a laparotomy.





PATIENT

Bella Luna Ford

SPECIES

Canine

BREED

Boxer

SEX

Spayed female

AGE

10 years

WEIGHT

50 lbs

INTERPRETED BY

Remo Lobetti, BVSc,
MMedVet (Med),
PhD, Dipl. ECVIM

IMAGING PERFORMED BY

Dr. Reser

HOSPITAL NAME

Harvest Hills VH

REFERRING VET

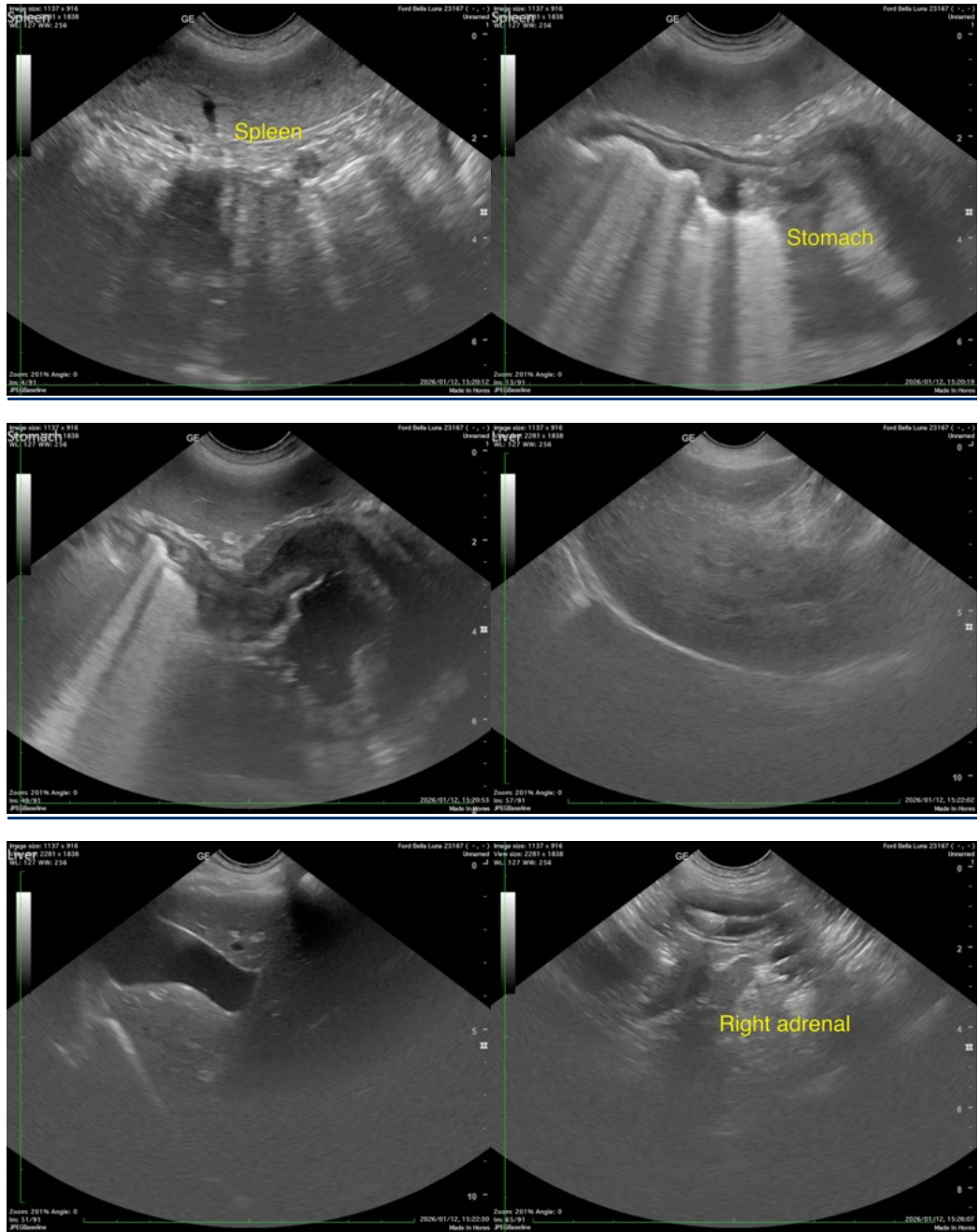
Dr. Reser

INVOICE

70029

DATE

1/12/26





PATIENT

Bella Luna Ford

SPECIES

Canine

BREED

Boxer

SEX

Spayed female

AGE

10 years

WEIGHT

50 lbs

INTERPRETED BY

Remo Lobetti, BVSc,
MMedVet (Med),
PhD, Dipl. ECVIM

IMAGING PERFORMED BY

Dr. Reser

HOSPITAL NAME

Harvest Hills VH

REFERRING VET

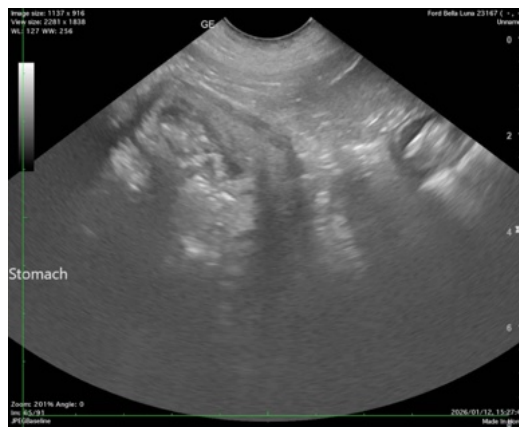
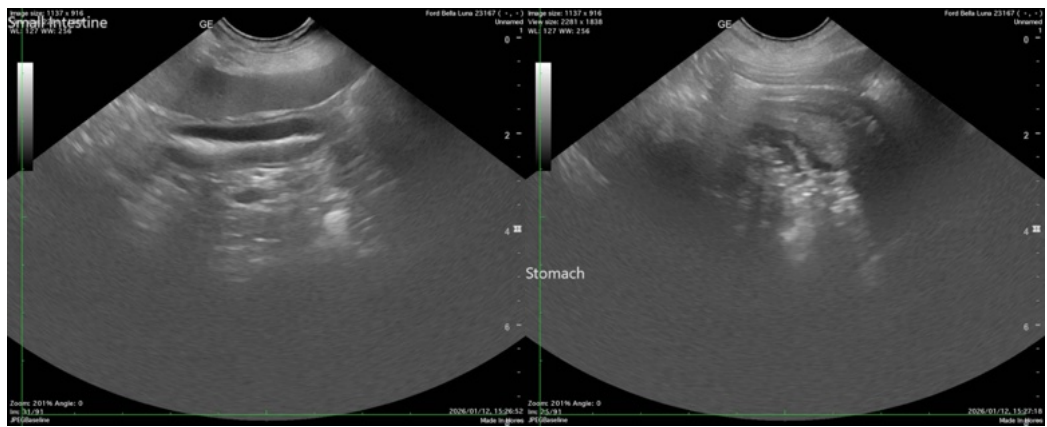
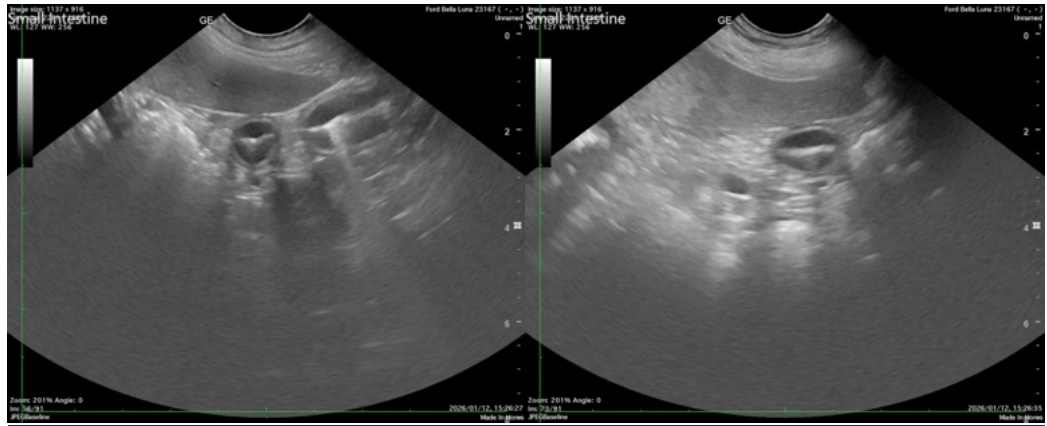
Dr. Reser

INVOICE

70029

DATE

1/12/26



The information and recommendations provided are based on the images presented by the referring veterinarian/sonographer. No evaluation can be communicated regarding pathology that was not visible in the image/video clips provided.

Thank you for this referral. If the clinical or image interpretation does not parallel your findings or if I can be of any further assistance please contact me.

Remo Lobetti, BVSc, MMedVet (Med), PhD, Dipl. ECVIM (Internal Medicine)



PATIENT

info@sonopath.com

Bella Luna Ford

SPECIES

Canine

BREED

Boxer

SEX

Spayed female

AGE

10 years

WEIGHT

50 lbs

INTERPRETED BY

Remo Lobetti, BVSc,
MMedVet (Med),
PhD, Dipl. ECVIM

**IMAGING
PERFORMED BY**

Dr. Reser

HOSPITAL NAME

Harvest Hills VH

REFERRING VET

Dr. Reser

INVOICE

70029

DATE

1/12/26