

DATE **PRESENTING CLINICAL SIGNS**

10/21/22

History: Recent adoption from hoarding issue, palpable abdominal mass.
Medication: Metronidazole, Carafate

INTERPRETED BY **CYTOLOGY SUBMISSION**

L.D. McGill, DVM,
Ph.D, DACVP

FNA of Enlarged lymph node

PATIENT

Figaro Zolomij

OBSERVATIONS

Enlarged lymph node: Submitted are 9 excellent videos of minimal cellular collections from the lymph node in Figaro. There is a marked background of red blood cells with a mixture of a few nucleated cells. Many of those cells are neutrophils. There are lymphoid cells and scattered macrophages. Malignant characteristics are not identified in this collection but there is a suggestion of inflammation.

SPECIES

Feline

INTERPRETATION OF THE FINDINGS & FURTHER RECOMMENDATIONS

Enlarged lymph node - Chronic suppurative lymphadenitis with reactive lymphoid tissue.

BREED

DLH

COMMENTS

The cellularity supports an inflammatory lymphadenopathy. This could be the result of inflammation draining from the pancreas or intestine. Pancreatitis could cause this type of lymphoid reactivity. The more likely cause is due to feline infectious peritonitis. This type of condition can affect specific lymph nodes or other locations in the abdominal cavity. There is no suggestion of malignancy or sepsis but there is definite suggestion of chronic inflammation. If further diagnostics are desired, further evaluation for feline coronavirus infection in Figaro is suggested. A guarded prognosis is warranted due to the potential of FIP.

SEX

Male

AGE

7m

WEIGHT

2.9

HOSPITAL NAME

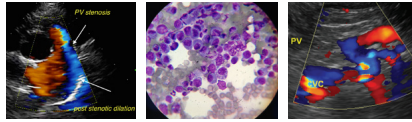
Orefield VC

REFERRING VET

Dr. Schlofer

INVOICE NUMBER

40629



DATE

10/21/22

INTERPRETED BY

L.D. McGill, DVM,
Ph.D, DACVP

PATIENT

Figaro Zolomij

SPECIES

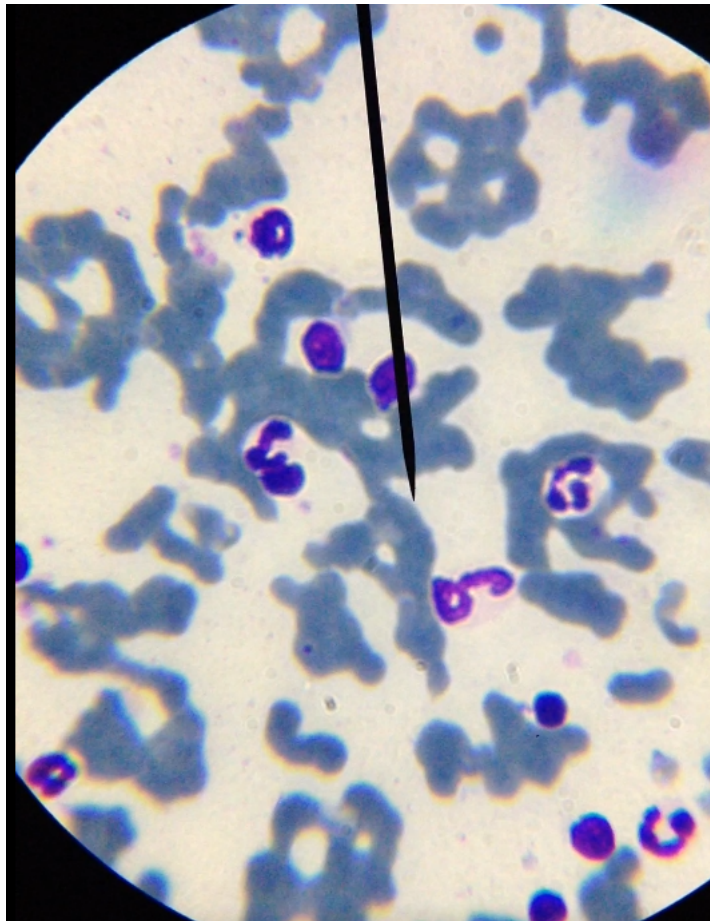
Feline

BREED

DLH

SEX

Male



AGE

7m

Image demonstrates a large number of neutrophils with mature lymphocytes collected from the lymph node in Figaro. The neutrophils do not appear to be toxic.

WEIGHT

2.9

The information and recommendations provided are based on the images presented by the referring veterinarian. No evaluation can be communicated regarding pathology that was not visible in the image/video clips provided.

Thank you for this referral. If the clinical or image interpretation does not parallel your findings or if I can be of any further assistance, please contact me.

HOSPITAL NAME

Orefield VC

L.D. McGill, DVM, Ph.D., DACVP
8288 Top of the World Drive
Cottonwood Heights, UT 84121
ldmcgill.vetpath@gmail.com
cell: 801-865-1220

REFERRING VET

Dr. Schlofer

INVOICE NUMBER

40629