



**PATIENT**

Cinnamon Mansey

**SPECIES**

Canine

**BREED**

Shih Tzu Mix

**SEX**

Female

**AGE**

6 Years, 4 Months

**INTERPRETED BY**

Nele Eley, DVM  
Dr. med. Vet. DipECVDI

**HOSPITAL NAME**

DPC Veterinary  
Hospital

**REFERRING VET**

Dr. Rivera

**INVOICE**

54017

**DATE**

9-8-22

**PRESENTING CLINICAL SIGNS**

Cinnamon started favoring her rear left leg, last Saturday, mom is concerned. B.A. R  
Abnormal PE/Chem/CBC/UA Results: Oral cavity: Moderate dental tartar, gingival recession on upper incisors. Musculoskeletal: BCS = 5/9. Ambulatory x 3. LH: Grade 4-5/5 lameness, semi-firm swelling at tarsus, painful on palpation, stifle and coxofemoral joint WNL.

**RADIOGRAPHIC STUDY OF THE LEFT TARSUS**

Mediolateral and dorsoplantar views of the left tarsus totaling 2 images available for review.

**RADIOGRAPHIC FINDINGS**

Moderate soft tissue swelling is noted circumferential to the left tarsometatarsal joint. There is medial deviation of the 2<sup>nd</sup> tarsal bone. A radiolucent line and deviation of the distolateral aspect of the left 4<sup>th</sup> tarsal bone are seen. Asymmetric widening of the tarsometatarsal joint space is noted.

**RADIOGRAPHIC DIAGNOSIS**

- Left tarsometatarsal subluxation with suspect traumatic osseous and ligamentous injury.

**INTERPRETATION OF THE FINDINGS & FURTHER RECOMMENDATIONS**

The radiographic findings suggest presence of traumatic injury with subluxation of the left tarsometatarsal joint. There appears to be a fracture of the 4<sup>th</sup> tarsal bone with articular involvement and moderate displacement as well as displacement of the 2<sup>nd</sup> tarsal bone and generalized and asymmetric widening of the tarsometatarsal joint space. Correlate with the clinical palpation. Stressed radiographs could be considered in order to further define for presence of subluxation/luxation. Presurgical CT could be considered as well in order to screen for additional occult traumatic osseous injury and to plan potential surgery.



**PATIENT**

Cinnamon Mansey

**SPECIES**

Canine

**BREED**

Shih Tzu Mix

**SEX**

Female

**AGE**

6 Years, 4 Months

**INTERPRETED BY**

Nele Eley, DVM  
Dr. med. Vet. DipECVDI

**HOSPITAL NAME**

DPC Veterinary  
Hospital

**REFERRING VET**

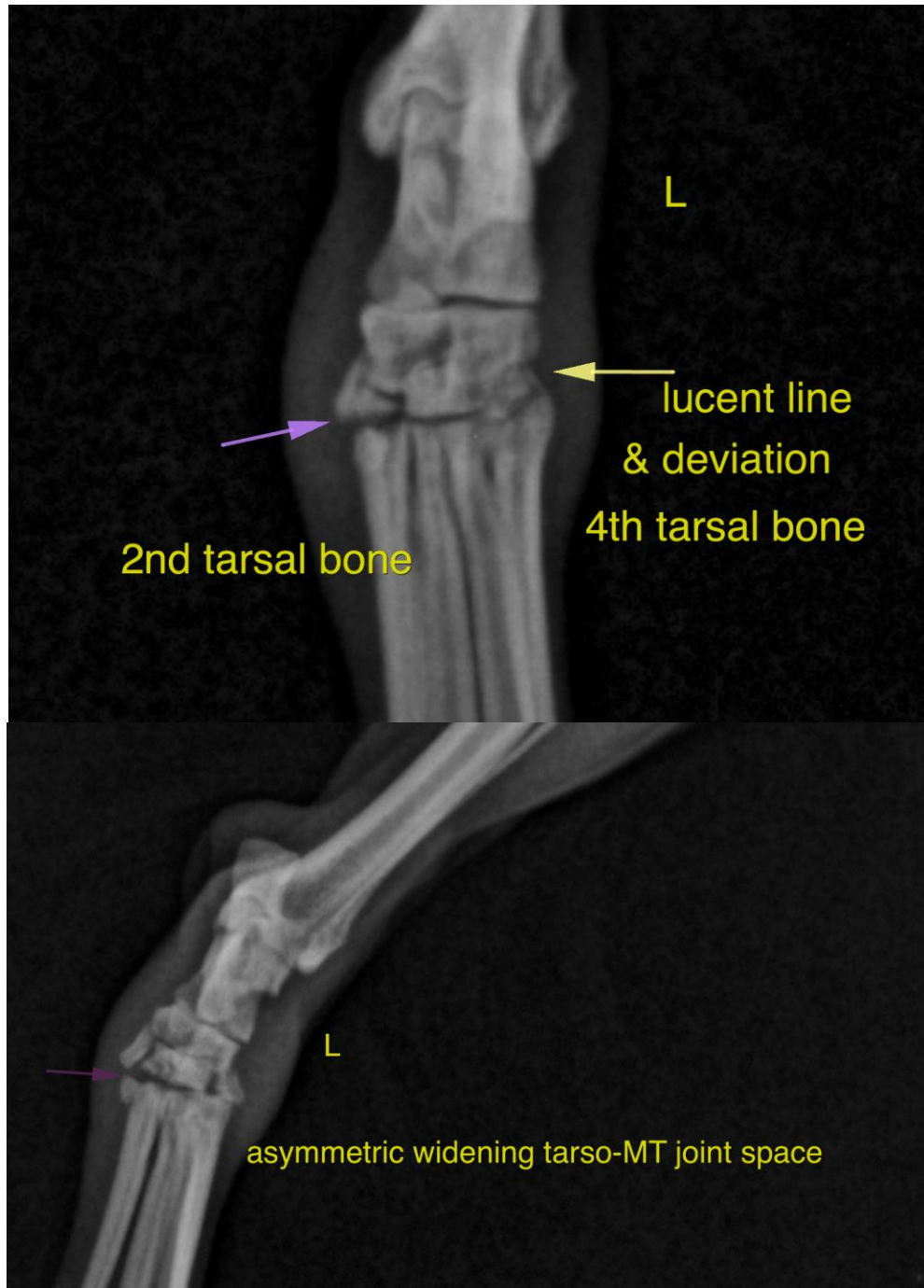
Dr. Rivera

**INVOICE**

54017

**DATE**

9-8-22





**PATIENT**

Cinnamon Mansey

**SPECIES**

Canine

The information and recommendations provided are based on the images presented by the referring veterinarian/sonographer. No evaluation can be communicated regarding pathology that was not visible in the image/video clips provided.

**BREED**

Shih Tzu Mix

Thank you for this referral. If the clinical or image interpretation does not parallel your findings or if I can be of any further assistance please contact me.

**Nele Eley**, DVM, Dr. med. vet., DipECVDI  
European Specialist in Veterinary Diagnostic Imaging, Cert. Radiology,  
Senior lecturer University of Giessen, Germany, Veterinary Faculty, Department of Radiology  
Nele.Eley@sonopath.com

**SEX**

Female

**AGE**

6 Years, 4 Months

**INTERPRETED BY**

Nele Eley, DVM  
Dr. med. Vet. DipECVDI

**HOSPITAL NAME**

DPC Veterinary  
Hospital

**REFERRING VET**

Dr. Rivera

**INVOICE**

54017

**DATE**

9-8-22