



**PATIENT PRESENTING CLINICAL SIGNS**

CHICO  
SWIERCZYNSKI

History: O STATES P BEEN COUGHING GOING ON LONG TIME USUALLY ONLY WHEN EXCITED. CHECK DERMAL GROWTHS P HAS 6 OR 7. GROWTH ON L HIP SEEMS TO HAVE GOTTEN BIGGER GRADUALLY O NOTICED A YEAR AGO. NO OTHER CONCERNS.

**SPECIES**

Canine

Abnormal PE/Chem/CBC/UA Results: Skin: Multiple pink semi-lobulated 1-3mm dermal masses consistent with sebaceous adenomas including left flank measuring 0.5cm. Solitary 0.5cm green-gray circumscribed waxy-appearing dermal mass right craniolateral thorax right side. Otherwise healthy hair coat. No ectoparasites seen, skin clean dry and intact. Musculoskeletal: BCS = 7/9. Ambulatory x 4, normal gait, high grade 2/4 MPL left stifle

**BREED**

Chihuahua

**RADIOGRAPHIC STUDY OF THE THORAX**

Right/left lateral and ventrodorsal views of the thorax totaling 3 images available for review.

**RADIOGRAPHIC FINDINGS**

**SEX**

NM

The lungs are moderately inflated. A moderate generalized bronchial lung pattern with mild cylindrical bronchiectasis and peribronchial cuffing accentuating the caudodorsal lung is seen.

There is mild esophageal aerophagia.

**AGE**

9 Years, 2 Months

Mild collapse of the caudal cervical and cranial thoracic trachea is seen on the left lateral view.

The radiographic presentation of the cardiac silhouette is within normal limits. The vertebral heart score is 10.5. No evidence of a vascular lung pattern is noted.

**INTERPRETED BY**

Nele Eley, DVM  
Dr. med. Vet. DipECVDI

The mediastinum presents within normal limits.

**RADIOGRAPHIC DIAGNOSIS**

- Chronic bronchial lung pattern
- Suspect dynamic tracheal disease.

**HOSPITAL NAME**

DPC Veterinary  
Hospital

**INTERPRETATION OF THE FINDINGS & FURTHER RECOMMENDATIONS**

The radiographic findings suggest potential for chronic lower airway disease such as irritant bronchitis, eosinophilic bronchopneumopathy, or infectious bronchitis including viral, bacterial, and parasitic.

**REFERRING VET**

Ward

There also is evidence of dynamic tracheal disease with mild collapse of the trachea being visible on the left lateral view. Clinical correlation is required.

**INVOICE**

54024

Upper and lower airway endoscopy with airway sampling could be considered for further definition as indicated per the clinical signs.

**DATE**

9-8-22



**PATIENT**

CHICO  
SWIERCZYNSKI

**SPECIES**

Canine

**BREED**

Chihuahua

**SEX**

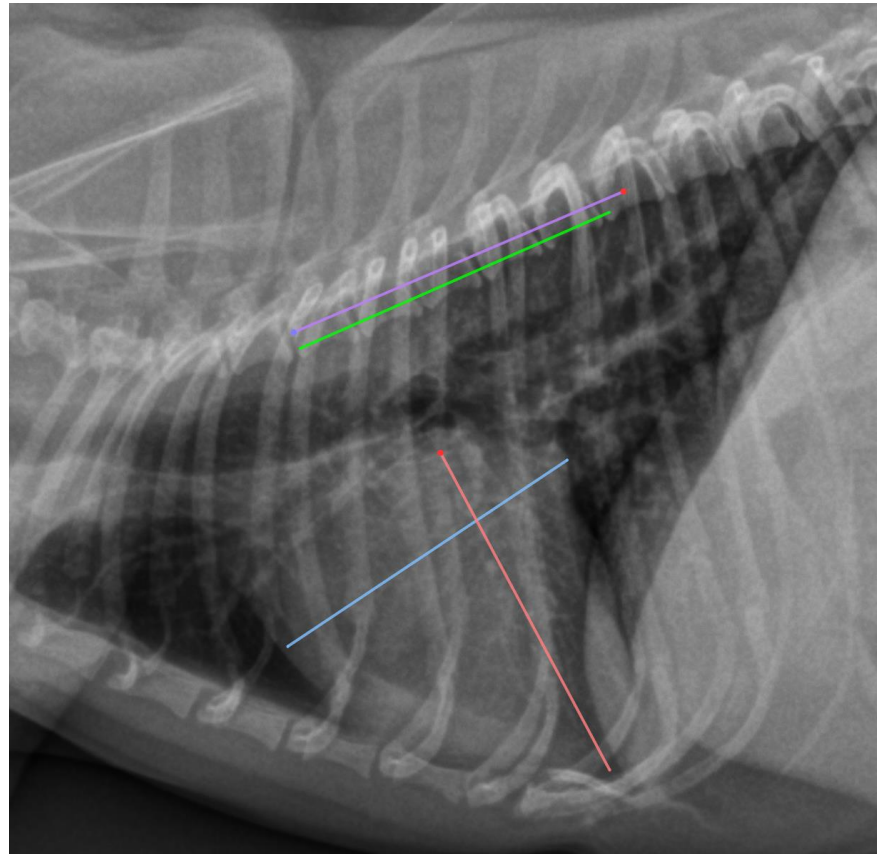
NM

**AGE**

9 Years, 2 Months

**INTERPRETED BY**

Nele Eley, DVM  
Dr. med. Vet. DipECVDI



**HOSPITAL NAME**

DPC Veterinary  
Hospital

**REFERRING VET**

Ward

**INVOICE**

54024

**DATE**

9-8-22

The information and recommendations provided are based on the images presented by the referring veterinarian/sonographer. No evaluation can be communicated regarding pathology that was not visible in the image/video clips provided.

Thank you for this referral. If the clinical or image interpretation does not parallel your findings or if I can be of any further assistance please contact me.

**Nele Eley**, DVM, Dr. med. vet., DipECVDI  
European Specialist in Veterinary Diagnostic Imaging, Cert. Radiology,  
Senior lecturer University of Giessen, Germany, Veterinary Faculty, Department of Radiology  
Nele.Eley@sonopath.com