



PATIENT

Blueberry Stubbert

PRESENTING CLINICAL SIGNS

Acute lameness LH leg
 Abnormal PE/Chem/CBC/UA Results: Moderate anterior drawer L stifle, mild lameness.

SPECIES

Canine

ULTRASONOGRAPHIC FINDINGS

Right Stifle

Scant effusion is seen within the supra- and infra patellar recesses of the right stifle joint. There is no evidence of synovial or capsular thickening or proliferation. The cranial cruciate ligament appears to be continuous and well-delineated, no deviation from normal echoarchitecture is noted. Lateral and medial menisci are within their anticipated positions and align well below the bone surfaces, meniscal surfaces are even and smooth. The echotexture is hypo echoic and uniform. The joint margins are smooth, no osteophytes are seen. The infra patellar fat pad present, the expected echo architecture.

BREED

American Bull Dog

SEX

Female

Left Stifle

A moderate amount of effusion is noted within the supra- and infra- patellar recesses of the left stifle joint. Continuous fibers of the left cranial cruciate ligament are seen. However, the ligament is poorly delineated, thickened with periligamentous effusion, and echogenic foci in the proximal and distal aspect of the visible ligament. The lateral and medial menisci present within normal limits.

AGE

11 Months

ULTRASONOGRAPHIC DIAGNOSIS

- Suspect partial avulsion injury of the left cranial cruciate ligament.

INTERPRETED BY

Nele Eley, DVM
 Dr. med. Vet. DipECVDI

INTERPRETATION OF THE FINDINGS & FURTHER RECOMMENDATIONS

The ultrasonographic findings suggest partial rupture of the left cranial cruciate ligament with potential avulsion fragments from the ligament's insertion. Differential diagnosis includes purely traumatic ligamentous avulsion as well as avulsion secondary to disturbed endochondral ossification in the intercondylar fossa of the distal femur which happens to occur in conjunction with cruciate ligament injuries in juvenile and adolescent dogs.

HOSPITAL NAME

Cedarview Animal Hospital

REFERRING VET

Chantal McCoubry

INVOICE

54023

DATE

9-8-22



PATIENT

Blueberry Stubbert

SPECIES

Canine

BREED

American Bull Dog

SEX

Female

AGE

11 Months

INTERPRETED BY

Nele Eley, DVM
Dr. med. Vet. DipECVDI

HOSPITAL NAME

Cedarview Animal
Hospital

REFERRING VET

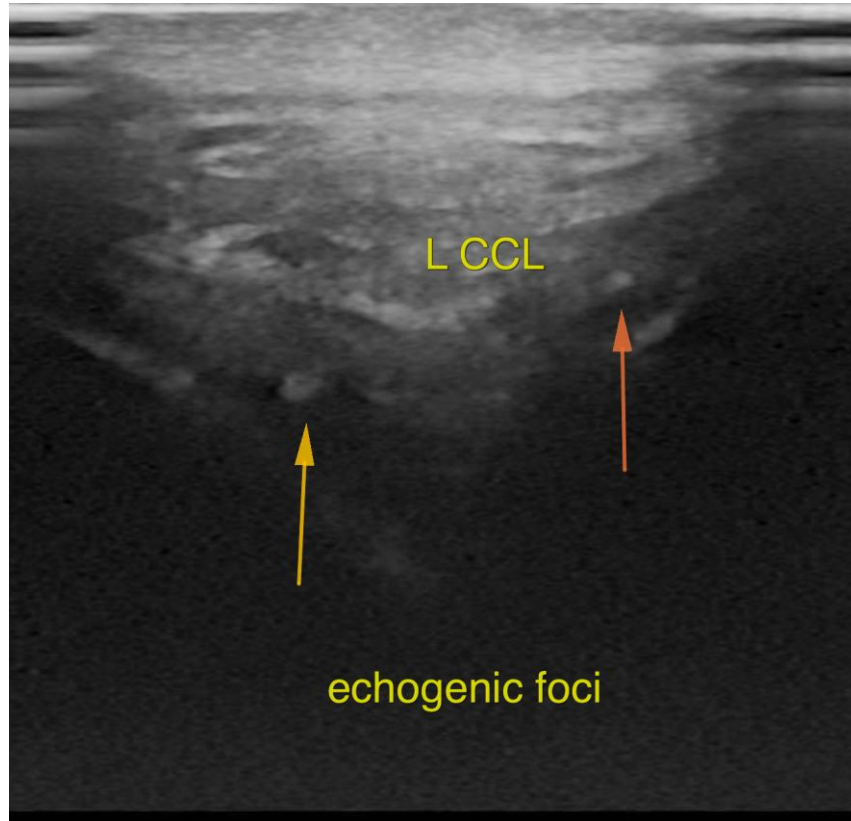
Chantal McCoubry

INVOICE

54023

DATE

9-8-22



The information and recommendations provided are based on the images presented by the referring veterinarian/sonographer. No evaluation can be communicated regarding pathology that was not visible in the image/video clips provided.

Thank you for this referral. If the clinical or image interpretation does not parallel your findings or if I can be of any further assistance please contact me.

Nele Eley, DVM, Dr. med. vet., DipECVDI
European Specialist in Veterinary Diagnostic Imaging, Cert. Radiology,
Senior lecturer University of Giessen, Germany, Veterinary Faculty, Department of Radiology
Nele.Eley@sonopath.com