



PATIENT

Big Boy Hovey

PRESENTING CLINICAL SIGNS

Hx of hind limb weakness unable to jump up on counter
 Abnormal PE/Chem/CBC/UA Results: BCS 9/9 Crepitation on hocks Suspect joint effusion by palpation Chest rads submitted as base line, no murmur auscultated at this time

SPECIES

FE

RADIOGRAPHIC STUDY OF THE TARSI & THORAX

Mediolateral and dorsoplantar views of both tarsi and lateral and ventrodorsal views of the thorax totaling 6 images available for review.

BREED

Maine Coon

RADIOGRAPHIC FINDINGS

Tarsi

Moderate articular effusion of the tarsocrural and intertarsal joints is seen.

SEX

MN

There is a moderate amount of periarticular new bone in the distal tibia, talus, and calcaneus, as well as between the central tarsal bones and proximal metatarsi.

AGE

15

Mild multifocal subchondral bone erosion accentuating both tarsocrural joints with mild irregular narrowing of the joint spaces is seen.

Thorax

INTERPRETED BY

Nele Eley, DVM
 Dr. med. Vet. DipECVDI

The patient is obese.

Note the presence of bilobed spherical mineralization in the cranial abdomen superimposed onto the central division of the liver.

HOSPITAL NAME

Torch Lake
 Veterinary Clinic

The surrounding bony structures are within normal limits.

The heart is of normal size and shape and there is no evidence of cardiac chamber or vascular enlargement. The pulmonary vasculature is within normal limits.

The cranial mediastinum presents the expected soft tissue opacity. The mediastinal width is less than twice the width of the vertebral column at the same level.

REFERRING VET

Adrienne Waffle

The trachea is normal in diameter and presents the anticipated course. The luminal outline of the trachea is smooth.

INVOICE

54036

The bronchial tree presents with thin walls and tapers uniformly towards the periphery as expected.

The lung parenchyma presents the expected architecture and opacity. The intrapulmonary vascular branching is seen up to the third order lung vessels.

DATE

9-8-22

The diaphragm is well delineated with even surface and the expected mild cranial bulging of the diaphragmatic cupola.



PATIENT

Big Boy Hovey

RADIOGRAPHIC DIAGNOSIS

- Moderate chronic bilateral tarsal arthropathy with mild erosive component.
- Normal radiographic presentation of the thorax.
- Bates body versus hepatic mineralization within the cranial abdomen.

SPECIES

FE

INTERPRETATION OF THE FINDINGS & FURTHER RECOMMENDATIONS

The radiographic study reveals moderate chronic bilateral tarsal arthropathy with articular swelling and mild erosive component. Differential diagnosis includes degenerative joint disease as well as immune mediated polyarthropathy. Consider aspiration and analysis of synovia for further definition. No evidence of aggressive osteolytic lesions is seen.

BREED

Maine Coon

The radiographic presentation of the lung, bronchial tree, and cardiovascular structures is within age related normal limits.

SEX

MN

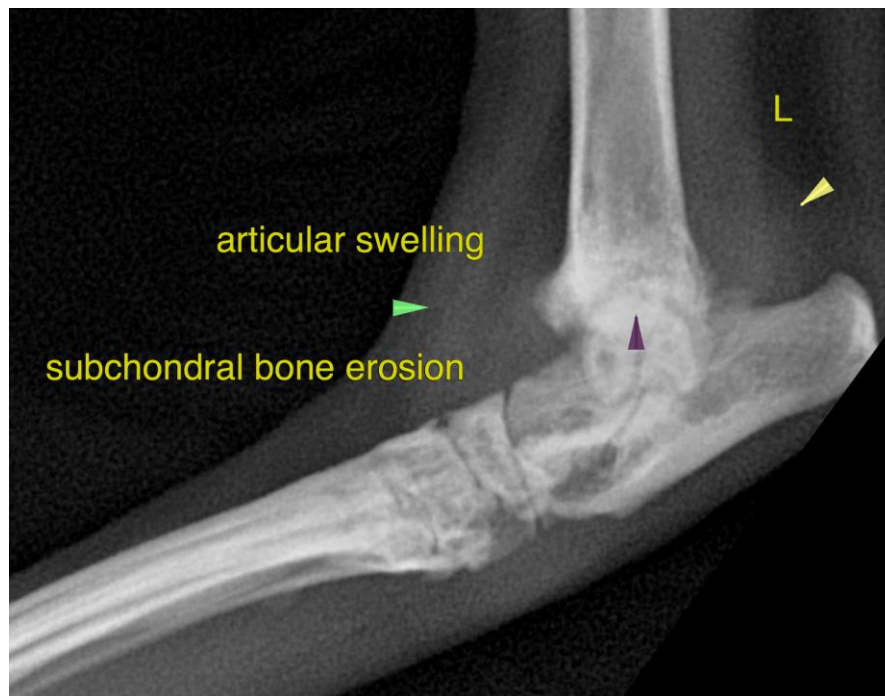
The spherical mineralization in the cranial abdomen is likely to represent a bates body which is an incidental finding. Hepatic mineralization is a potential but less likely differential diagnosis.

AGE

15

INTERPRETED BY

Nele Eley, DVM
Dr. med. Vet. DipECVDI



HOSPITAL NAME

Torch Lake
Veterinary Clinic

REFERRING VET

Adrienne Waffle

INVOICE

54036

DATE

9-8-22



PATIENT

Big Boy Hovey

The information and recommendations provided are based on the images presented by the referring veterinarian/sonographer. No evaluation can be communicated regarding pathology that was not visible in the image/video clips provided.

SPECIES

FE

Thank you for this referral. If the clinical or image interpretation does not parallel your findings or if I can be of any further assistance please contact me.

BREED

Maine Coon

Nele Eley, DVM, Dr. med. vet., DipECVDI
European Specialist in Veterinary Diagnostic Imaging, Cert. Radiology,
Senior lecturer University of Giessen, Germany, Veterinary Faculty, Department of Radiology
Nele.Eley@sonopath.com

SEX

MN

AGE

15

INTERPRETED BY

Nele Eley, DVM
Dr. med. Vet. DipECVDI

HOSPITAL NAME

Torch Lake
Veterinary Clinic

REFERRING VET

Adrienne Waffle

INVOICE

54036

DATE

9-8-22