



PATIENT

Sugar Levine

PRESENTING CLINICAL SIGNS

limping

SPECIES

Canine

RADIOGRAPHIC STUDY OF THE PELVIS & STIFLES

Mediolateral views of the stifles and ventrodorsal hip extended view of the pelvis totaling 3 images available for review.

BREED

Peekapoo

The patient is a chondrodystrophic dog with shortened and stunted long bones.

SEX

Female/sp

Moderate signs of hip dysplasia with reduced femoral head coverage and femoral head subluxation are seen in both coxofemoral joints along with moderate osteoarthritic changes such as circumferential femoral head and caudolateral curvilinear femoral neck osteophytes. Flattening of the cranio-lateral acetabular rims with increased subchondral bone sclerosis and periarticular new bone formation of the acetabulum are seen as well.

AGE

13 Years

Subluxation of the caudal coccygeal vertebrae with angulation of the caudal tail is noted due to presence of a short vertebra.

The muscle volume of both hind limbs appears to be symmetric.

Mild medial curvature of the proximal tibia is seen with no evidence of medial patella luxation.

The stifle joints present within age and breed related normal limits.

The medial fabella is in a distal position which is common in terrier breeds.

No evidence of articular swelling and no significant osteoarthritic changes of the stifle joints are seen.

RADIOGRAPHIC DIAGNOSIS

- Moderate bilateral canine hip dysplasia with moderate secondary coxofemoral joint osteoarthritis.

INTERPRETATION OF THE FINDINGS & FURTHER RECOMMENDATIONS

Both coxofemoral joints reveal moderate signs of osteoarthritis secondary to canine hip dysplasia.

No radiographic evidence of stifle joint pathology is seen. correlation with the clinical palpation required.

INTERPRETED BY

Nele Eley, DVM
Dr. med. Vet. DipECVDI

HOSPITAL NAME

New Bridge
Veterinary Practice

REFERRING VET

Dr. Abina Glennon

INVOICE

53993

DATE

9-7-22



PATIENT

Sugar Levine

SPECIES

Canine

BREED

Peekapoo

SEX

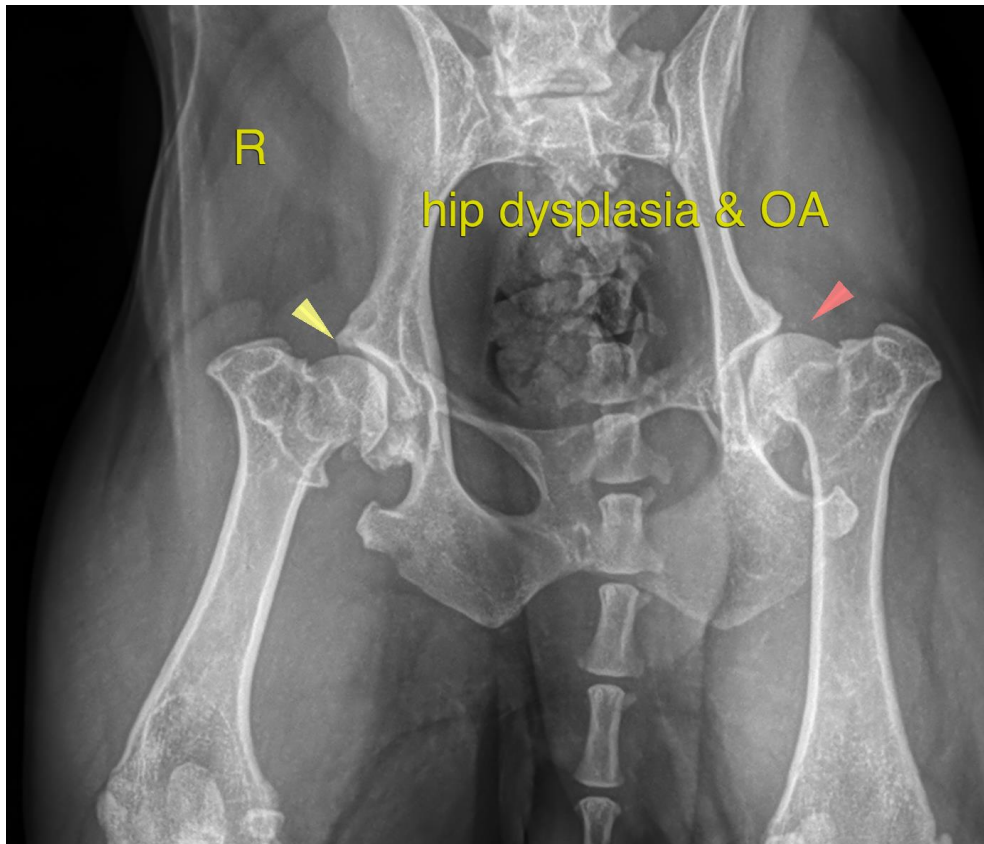
Female/sp

AGE

13 Years

INTERPRETED BY

Nele Eley, DVM
Dr. med. Vet. DipECVDI



HOSPITAL NAME

New Bridge
Veterinary Practice

REFERRING VET

Dr. Abina Glennon

INVOICE

53993

DATE

9-7-22

The information and recommendations provided are based on the images presented by the referring veterinarian/sonographer. No evaluation can be communicated regarding pathology that was not visible in the image/video clips provided.

Thank you for this referral. If the clinical or image interpretation does not parallel your findings or if I can be of any further assistance please contact me.

Nele Eley, DVM, Dr. med. vet., DipECVDI
European Specialist in Veterinary Diagnostic Imaging, Cert. Radiology,
Senior lecturer University of Giessen, Germany, Veterinary Faculty, Department of Radiology
Nele.Eley@sonopath.com