

**PATIENT**

Cooper Viehdorfer

**PRESENTING CLINICAL SIGNS**

He woke up yesterday morning, lethargic and uncomfortable, went to bed at 6pm and didn't get up for 12 hours. He didn't eat or drink anything yesterday. He had 3 normal BM's yesterday. This morning his stool was soft. He seems a little bit better. He had metronidazole yesterday afternoon and kept it down and then he threw up the pill today. He has thrown up a few times today. Bile. Rick syringed Cooper water yesterday afternoon since he wasn't drinking. Abnormal PE/Chem/CBC/UA Results: Full Adult Blood Work Pending

**SPECIES**

Canine

**RADIOGRAPHIC STUDY OF THE ABDOMEN****BREED**

Corgi

Right/left lateral and ventrodorsal views of the abdomen totaling 3 images available for review.

**RADIOGRAPHIC FINDINGS****SEX**

Patient has an asymmetric thoracolumbar transitional vertebra and is mildly obese.

**MN**

The abdominal serosal detail is maintained.

**AGE**

2 Years, 3 Months

Crowding of the small intestine is seen in the mid abdomen. Part of the small intestine contains gas and severe loops are turgid in appearance. The small intestinal loops are of even diameter with no evidence of plication or radiopaque foreign material.

Gastric aerophagia is noted.

**INTERPRETED BY**

Nele Eley, DVM  
Dr. med. Vet. DipECVDI

A mild amount of fecal matter is seen in the descending colon.

**RADIOGRAPHIC DIAGNOSIS**

- Gastrointestinal maldigestion pattern with no radiographic evidence of mechanical ileus.

**HOSPITAL NAME**

Elizabeth Animal  
Hospital

**INTERPRETATION OF THE FINDINGS & FURTHER RECOMMENDATIONS**

The radiographic study suggests functional ileus rather than mechanical ileus. No signs of complete mechanical obstruction are seen. Abdominal ultrasound could be considered for further definition in case of persisting or deteriorating clinical signs.

**REFERRING VET**

Kim Allyn, DVM

**INVOICE**

53989

**DATE**

9-7-22



**PATIENT**

Cooper Viehdorfer

**SPECIES**

Canine

**BREED**

Corgi

**SEX**

MN

**AGE**

2 Years, 3 Months

**INTERPRETED BY**

Nele Eley, DVM  
Dr. med. Vet. DipECVDI

**HOSPITAL NAME**

Elizabeth Animal  
Hospital

**REFERRING VET**

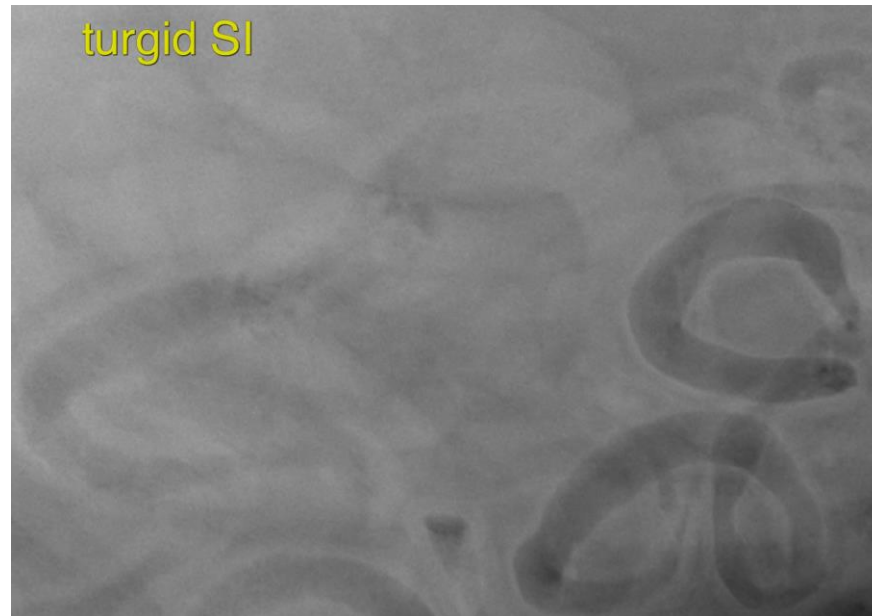
Kim Allyn, DVM

**INVOICE**

53989

**DATE**

9-7-22



The information and recommendations provided are based on the images presented by the referring veterinarian/sonographer. No evaluation can be communicated regarding pathology that was not visible in the image/video clips provided.

Thank you for this referral. If the clinical or image interpretation does not parallel your findings or if I can be of any further assistance please contact me.

**Nele Eley**, DVM, Dr. med. vet., DipECVDI  
European Specialist in Veterinary Diagnostic Imaging, Cert. Radiology,  
Senior lecturer University of Giessen, Germany, Veterinary Faculty, Department of Radiology  
Nele.Eley@sonopath.com